



PATIENT

Huck Glick

SPECIES

Canine

BREED

Miniature Schnauzer

SEX

Neutered Male

AGE

2007

WEIGHT

14.6 Pounds

INTERPRETED BY

Eric Lindquist, DMV
DABVP, Cert. IVUSS

**IMAGING
PERFORMED BY**

Denise Bruno, LVT,
RDMS

HOSPITAL NAME

Farview AC

REFERRING VET

Dr. Mosaad

INVOICE

97778

DATE

3/24/22

PRESENTING CLINICAL SIGNS

History: Constant diarrhea since 2/2022 + losing weight not responding to Metro., Provable + Tylan powder. Hx of kidney Dz - on k?d + Aminavast (L) 1 cup Bid
Abnormal PE/Chem/CBC/UA Results: Labs & Radiographs attached

ULTRASONOGRAPHIC EXAMINATION OF THE ABDOMEN

Urinary System

The **urinary bladder**, trigone, and pelvic urethra presented normal thicknesses and normal tone. The ureters were not visible which is normal. Minor bladder sand was noted and was non-obstructive. No evidence of inflammatory or neoplastic changes was noted. Ureteral papillae were normal.

The prostate was uniform and measured 1.02 cm. The pre and post prostatic urethra were unremarkable other than minor urethral sand.

The **kidneys** revealed largely normal size and structure, corticomedullary definition and ratio (cortex 1/3 of medulla) were essentially maintained with some age-related loss of curvilinear patterns regarding the capsule and C/M junction. The cortices presented largely uniform texture with some increased echogenicity expected for this age patient. Medullary structure differed distinctly from that of the cortex and no evidence of pelvic dilation was present. Occasional cortical cysts were noted. The right kidney measured 4.4 cm. The left kidney measured 4.22 cm.

Adrenal Glands

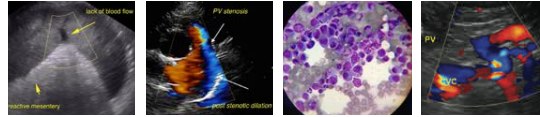
Both **adrenal glands** were visualized and recognized as having normal shape, size, position and echogenicity for this breed. The phrenic vasculature, glandular echogenicity and detail were unremarkable. Capsule, cortex, and medullary definition were normal for this age patient. The right adrenal gland measured 2.07 x 0.71 cm at the cranial pole and 0.48 cm at the caudal pole. The left adrenal gland measured 2.0 x 0.61 cm at the caudal pole and 0.56 cm at the cranial pole.

Spleen

The **spleen** presented a smooth homogeneous parenchyma hyperechoic to liver and renal cortical parenchyma. The capsule was smooth without noticeable expansion or deviation from within the spleen or adjacent pathology. The splenic vasculature demonstrated normal volume without signs of congestion or thrombosis. No sonographic evidence of acute or chronic inflammatory, neoplastic, or infarctual changes was noted.

Liver

The **liver** revealed multi-focal, hypoechoic nodular changes in the left limb. Other heterogenous hepatic changes were noted. The gallbladder was over distended with gallbladder sand and debris. This is consistent with emerging mucocele.



PATIENT

Gastrointestinal

Huck Glick

The **gastrointestinal** presentation revealed mild uniform prominence of the gastric mucosa as well as areas of "ropey" small intestinal wall. The muscularis layer was hypertrophied inverting the normal ratio (1:3). The intestinal submucosa was slightly irregular, thickened and hyperechoic suggestive of low grade, chronic inflammation. Intestinal wall thickness measured 0.36 cm. No evidence of obstruction was present. Chronic inflammatory bowel disease is probable with a low possibility of an early neoplastic event such as lymphoma or, less likely, dry form FIP can at times be found on biopsy of these presentations. Full thickness tissue biopsies via open laparotomy, ideally guided by intraoperative ultrasound in order to obtain the most representative mural sample, would be necessary to rule more significant disease than IBD.

SPECIES

Canine

BREED

Miniature Schnauzer

SEX

Pancreas

Neutered Male

The base and limbs of the **pancreas** were observed to be largely isoechoic to surrounding omental fat. Pancreatic duct and capsular contour were acceptably normal and parenchyma respected normal curvilinear patterns. No overt evidence of active inflammatory or neoplastic disease was noted.

AGE

2007

ULTRASONOGRAPHIC FINDINGS

WEIGHT

14.6 Pounds

Emerging mucocele.

Undefined hepatic nodules. Differentials include nodular hyperplasia versus emerging carcinoma.

Variable intestinal thickening.

INTERPRETED BY

Small amount of bladder and urethral stand.

Eric Lindquist, DMV
DABVP, Cert. IVUSS

INTERPRETATION OF THE FINDINGS & FURTHER RECOMMENDATIONS

IMAGING PERFORMED BY

FNA of the liver nodules is recommended. The residual prostate is slightly enlarged for a neutered male, but may be normal if the patient was neutered later in life. Full urinary work-up is warranted. Full thickness GI biopsies and liver biopsies can be considered in this patient. If not FNA of the liver nodules are recommended. There is no obvious evidence of neoplasia in the GI tract; however, hepatic neoplasia is a potential. Sampling is strongly recommended. Maldigestion panel, three view chest radiographs and full CNS examination is recommended to examine for occult disease that could be responsible for the weight loss. Evaluation for competitive eating environments should also be considered.

Denise Bruno, LVT,
RDMS

HOSPITAL NAME

Farview AC

REFERRING VET

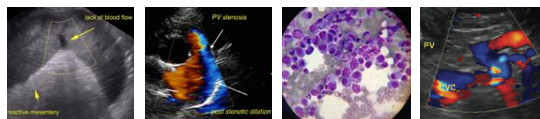
Dr. Mosaad

INVOICE

97778

DATE

3/24/22



PATIENT

Huck Glick

SPECIES

Canine

BREED

Miniature Schnauzer

SEX

Neutered Male

AGE

2007

WEIGHT

14.6 Pounds

INTERPRETED BY

Eric Lindquist, DMV
DABVP, Cert. IVUSS

IMAGING PERFORMED BY

Denise Bruno, LVT,
RDMS

HOSPITAL NAME

Farview AC

REFERRING VET

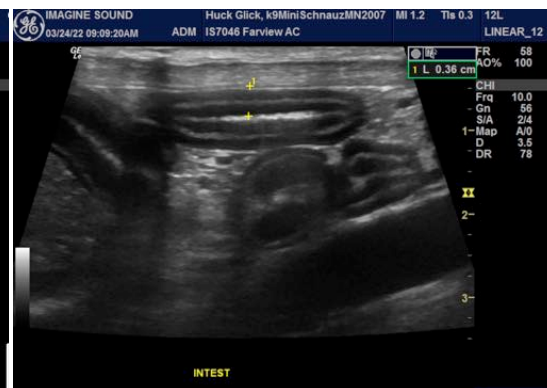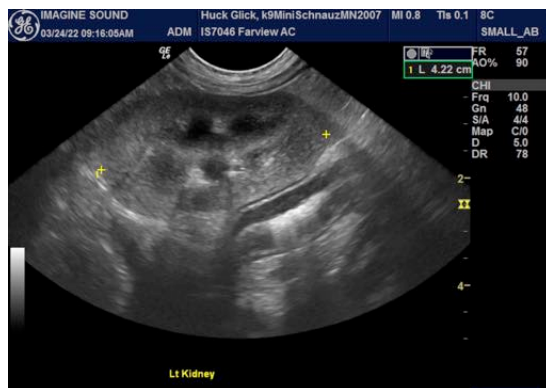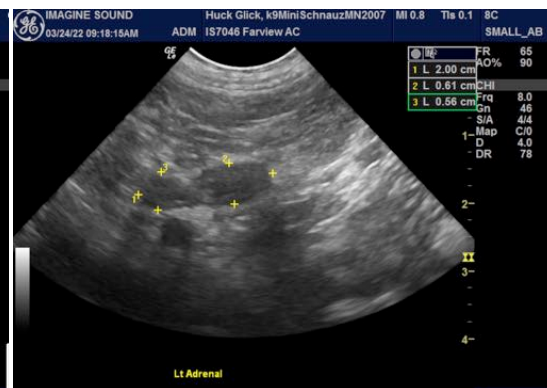
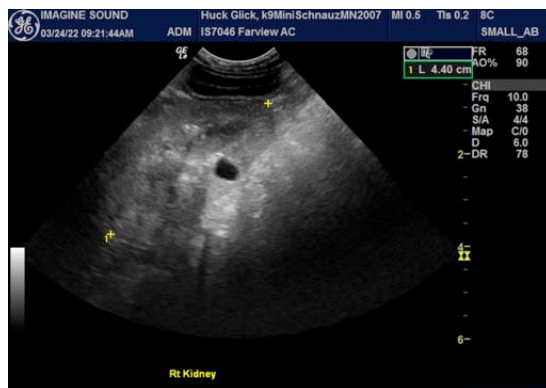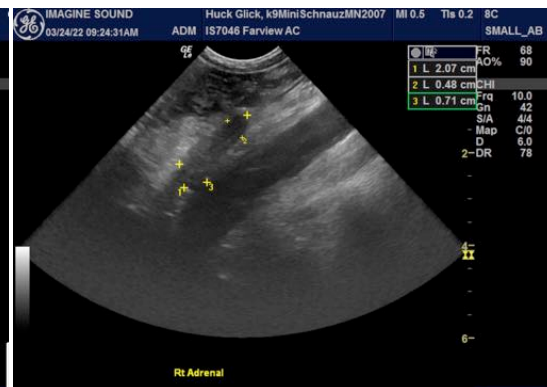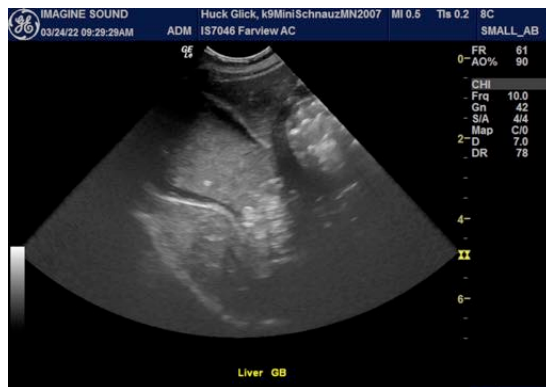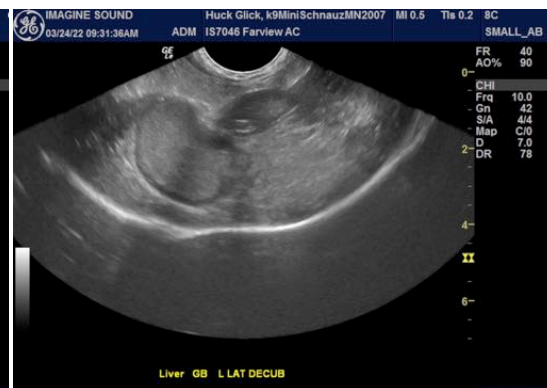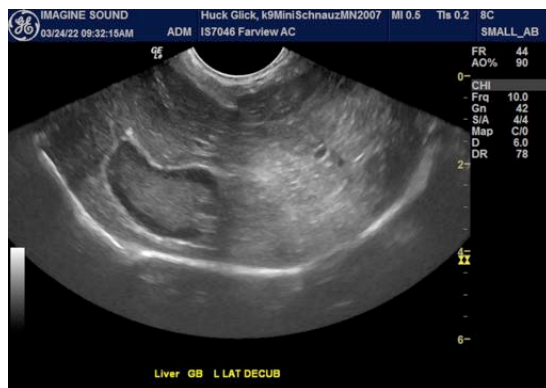
Dr. Mosaad

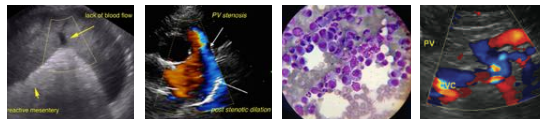
INVOICE

97778

DATE

3/24/22





PATIENT

Huck Glick

SPECIES

Canine

BREED

Miniature Schnauzer

SEX

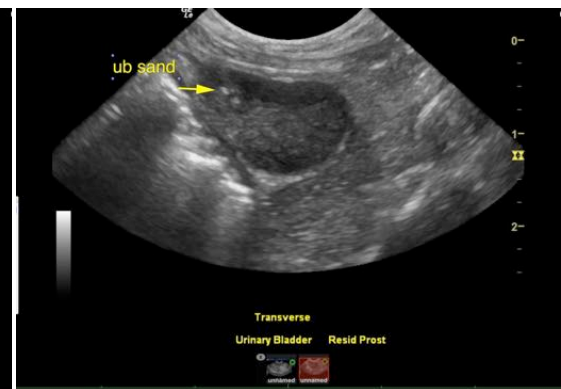
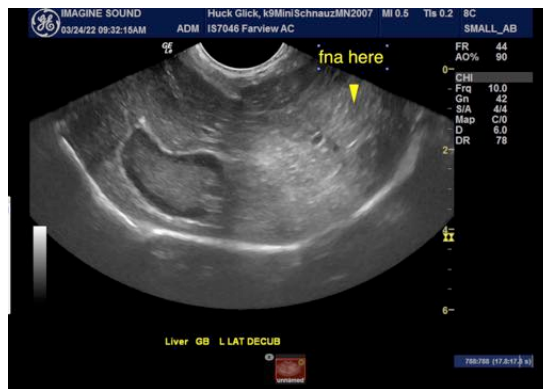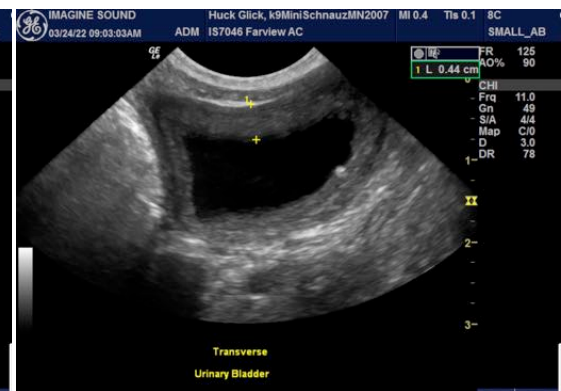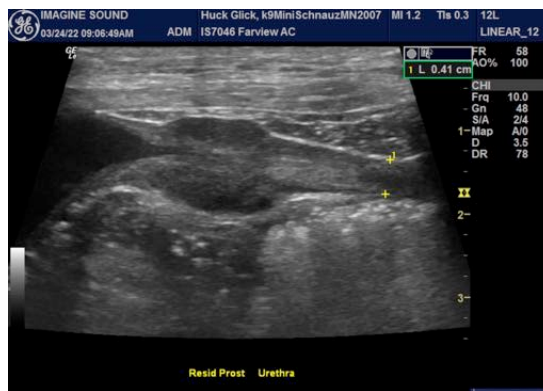
Neutered Male

AGE

2007

WEIGHT

14.6 Pounds



INTERPRETED BY

Eric Lindquist, DMV
DABVP, Cert. IVUSS

IMAGING PERFORMED BY

Denise Bruno, LVT,
RDMS

HOSPITAL NAME

Farview AC

REFERRING VET

Dr. Mosaad

INVOICE

97778

DATE

3/24/22

The information and recommendations provided are based on the images presented by the referring veterinarian/sonographer. No evaluation can be communicated regarding pathology that was not visible in the image/video clips provided.

Thank you for this referral. If the clinical or image interpretation does not parallel your findings or if I can be of any further assistance please contact me.

Eric Lindquist, DMV, DABVP, Cert. IVUSS, CEO of SonoPath.com
Eric.Lindquist@SonoPath.com