

**DATE**

3/24/22

PRESENTING CLINICAL SIGNS

Increasing lethargy, occasional vomiting, general ADR over las month- sudden change; bloodwork showed PLN & anemia.

PATIENT

Breeze Stadler

Current Medications: Just starting Doxy/Benazepril.

Lab Results: See attached.

Date of Previous IntraPet Ultrasound: No previous.

Sedation: Not required to complete full diagnostic ultrasound.

Stat Report: Not requested.

Imaging Performed By: Rachel Brilhart, RDMS.

SPECIES

Canine

ULTRASONOGRAPHIC EXAMINATION OF THE ABDOMEN**BREED**

Golden Retriever

Urinary System

The **urinary bladder**, trigone, and pelvic urethra presented normal thicknesses and normal tone. The ureters were not visible which is normal. No uroliths or sediment were visualized and anechoic urine was present. No evidence of inflammatory or neoplastic changes was noted. Ureteral papillae were normal.

SEX

Spayed Female

The **kidneys** revealed largely normal size and structure, corticomedullary definition and ratio (cortex 1/3 of medulla) were essentially maintained with some age-related loss of curvilinear patterns regarding the capsule and C/M junction. The cortices presented largely uniform texture with some increased echogenicity expected for this age patient. Medullary structure differed distinctly from that of the cortex. The left kidney measured 7.14 cm with pyelectasia that measured 0.48 cm. The right kidney measured 7.03 cm with minor pyelectasia that measured 0.43 cm.

AGE

5/28/12

WEIGHT

65 lbs

Adrenal Glands

Both **adrenal glands** were visualized and recognized as having normal shape, size, position and echogenicity for this breed. The phrenic vasculature, glandular echogenicity and detail were unremarkable. Capsule, cortex, and medullary definition were normal for this age patient. The left adrenal gland measured 3.02 x 0.75 cm at the caudal pole and 0.55 cm at the cranial pole. The right adrenal gland measured 4.08 x 1.12 cm at the cranial pole and 1.07 cm at the caudal pole.

INTERPRETED BY

Eric Lindquist, DMV
DABVP, Cert. IVUSS

Spleen

The **spleen** was largely smooth with subtle heterogeneous parenchymal changes while maintaining normal echogenic relationship to the liver and kidney. These changes are consistent with normal age-related alteration. The capsule was smooth without noticeable impingement from within the spleen or from pathology in the adjacent abdomen. The splenic vasculature demonstrated normal volume without signs of congestion or significant contraction. No evidence of active acute or chronic inflammatory, neoplastic, or infarctual changes was noted.

HOSPITAL NAME

Bayside Animal
Medical Center

REFERRING VET

Dr. DeLozier

Liver

The **liver** images submitted revealed subjectively normal liver size, contour, and structure. Parenchymal echogenicity was naturally coarse and hypoechoic to the spleen. Vascular and biliary tracts were of normal volume with no evidence of congestion. Minor gallbladder debris was noted.

INVOICE

97771

Gastrointestinal

Examination of the **gastrointestinal tract** revealed a stomach and intestine free of stasis, of normal wall thickness, acceptable curvilinear mural detail, and peristaltic activity. Small and large intestine demonstrated normal luminal chyme and stool consistency respectively. No obstructive or overt infiltrative disease was noted. No associated abnormal lymphatic activity was noted.

Pancreas

The base and limbs of the **pancreas** were observed to be largely isoechoic to surrounding omental fat. Pancreatic duct and capsular contour were acceptably normal and parenchyma respected normal curvilinear patterns. No overt evidence of active inflammatory or neoplastic disease was noted.

Heart

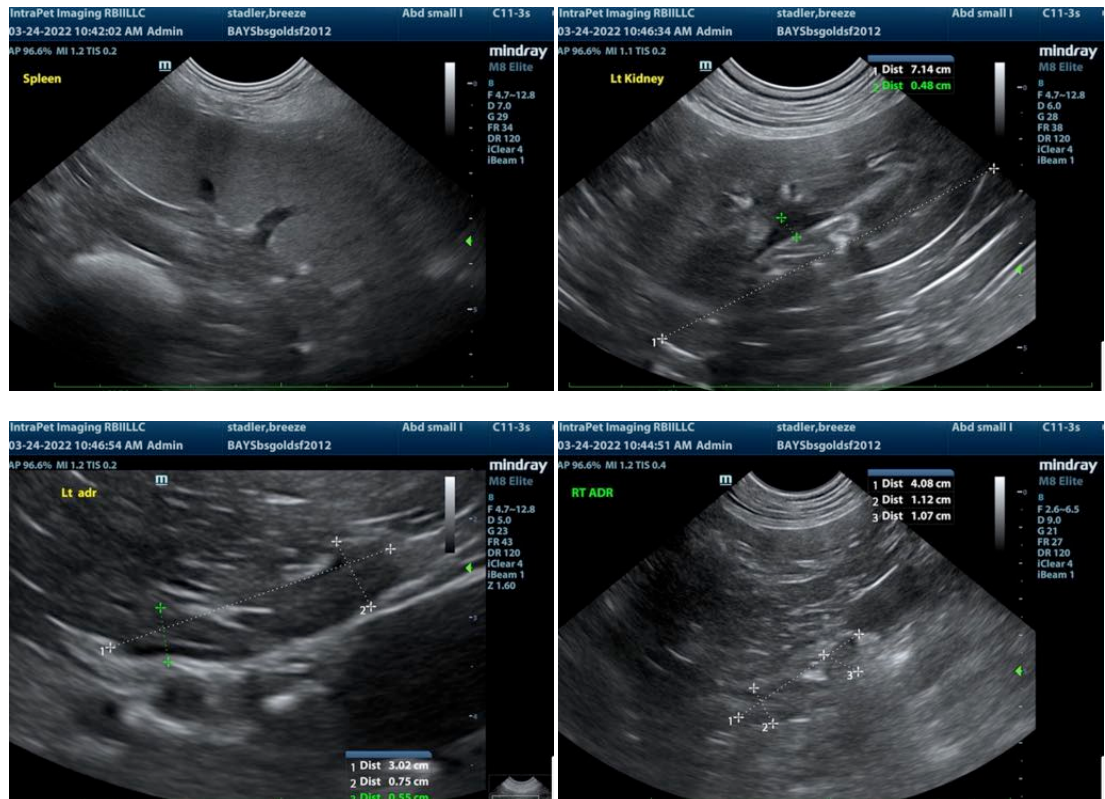
Rapid view of the heart revealed occasional arrhythmia.

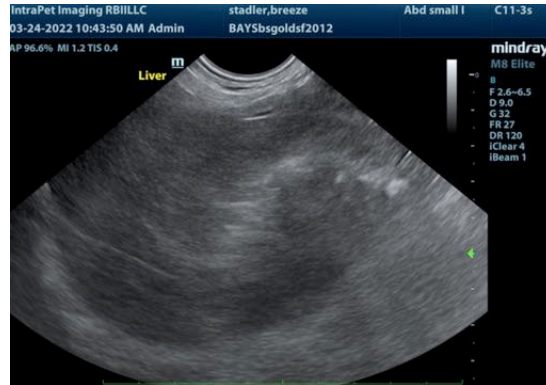ULTRASONOGRAPHIC FINDINGS

Structurally unremarkable abdomen with age related renal changes with pyelectasia. Occasional arrhythmia.

INTERPRETATION OF THE FINDINGS & FURTHER RECOMMENDATIONS

I recommend assessment for proteinuria and any inflammatory sediment is warranted that may be consistent with pyelonephritis, yet the pyelectasia may be owing to simple scarring of the renal pelvises. The cause of lethargy is unclear. Assessment for arrhythmogenic disease is warranted. Orthopedic, CNS or thoracic disease should also be considered. Underlying food intolerance, Helicobacter and occult parasitism are all potentials for the vomiting. Screening for Addison's is warranted given the vague clinical signs even though the adrenal glands appear unremarkable. If weight loss is an issue FNA of the spleen is warranted to ensure this is a benign process as subjectively assessed.





The information and recommendations provided are based on the images presented by the referring veterinarian. No evaluation can be communicated regarding pathology that was not visible in the image/video clips provided.

Thank you for this referral. If the clinical or image interpretation does not parallel your findings or if I can be of any further assistance please contact me.

Eric Lindquist, DMV, DABVP, Cert. IVUSS, CEO of SonoPath.com
Eric.Lindquist@SonoPath.com