



**PATIENT**

Aspen Carr

**PRESENTING CLINICAL SIGNS**

Increased respiratory rate. Weight loss.

**SPECIES**

Feline

**BREED**

DSH

**SEX**

Neutered Male

**AGE**

5 Years

**WEIGHT**

16.9 Pounds

**INTERPRETED BY**

Eric Lindquist, DMV

DABVP, Cert. IVUSS

**IMAGING PERFORMED BY**

Eric Lindquist, DMV

DABVP, Cert. IVUSS

**HOSPITAL NAME**

ACC Flanders

**REFERRING VET**

Dr. Hallihan

**INVOICE**

36424

**DATE**

3/24/22

**ULTRASONOGRAPHIC EXAMINATION OF THE HEART**

FELINE CARDIAC PARAMETERS	BODY WEIGHT (kg)	HR (BPM)	IVSd (cm)	LVIDd (cm)	LVWd (cm)	FS (%)	EF (%)
NORMAL PARAMETER	-----	150-240	0.3-0.6	1.0-2.1	0.25-0.6	35-67	80-100
PATIENT		117	0.73	1.5	0.9	56	89
FELINE CARDIAC PARAMETERS	LA/AO (Boon)	LA/AO HEART BASE (Sisson)	LA 2D 4-chamber long axis AS to FW (Sisson) (cm)	LVOT VEL. (m/s)	RVOT VEL. (m/s)	IVRT (m/)	
NORMAL PARAMETER	<1.5	0.88-1.79	0.7-1.7	<1.6	<1.3	40-60	
PATIENT	~2.5						NM
Adapted from June Boon, Veterinary Echocardiography, 1998 Sisson D et al. JVIM 1991; 5: 232, Jacobs et al. Am J Vet Res 1985; 46:1705							

**Cardiac Presentation**

Rapid echocardiogram performed owing to pathological bradycardia and severe volume overload of the heart. The extracardiac space revealed pulmonary edema. Severe left atrial enlargement with bradyarrhythmia. Moderate right atrial enlargement noted. Slight pericardial effusion present. Contractility appeared adequate.

**ULTRASONOGRAPHIC FINDINGS**

- Hypertrophic cardiomyopathy with bradyarrhythmia, left-sided heart failure, moderate right-sided enlargement

**INTERPRETATION OF THE FINDINGS & FURTHER RECOMMENDATIONS**

This patient is at high risk for sudden death. Recommend Lasix 12.5 mg BID, diminishing to 6.25 BID based on blood pressures, any azotemia development, and basal respiratory rate of target <20/min. Pimobendan off-label at 0.3 mg/kg BID. ACE inhibitor 0.5 mg/kg SID, and Plavix therapy. Recheck echo in 10 days. Very guarded prognosis.



**PATIENT**

Aspen Carr

**SPECIES**

Feline

**BREED**

DSH

**SEX**

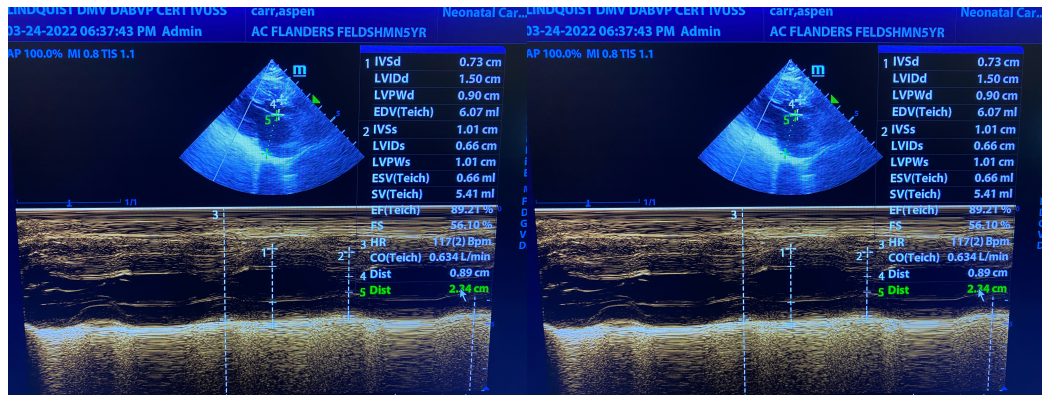
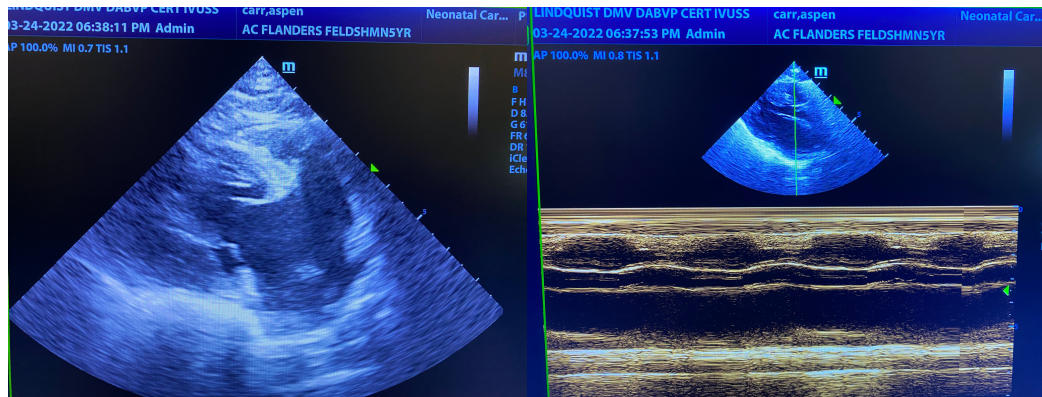
Neutered Male

**AGE**

5 Years

**WEIGHT**

16.9 Pounds



**INTERPRETED BY**

Eric Lindquist, DMV  
DABVP, Cert. IVUSS

**IMAGING PERFORMED BY**

Eric Lindquist, DMV  
DABVP, Cert. IVUSS

**HOSPITAL NAME**

ACC Flanders

**REFERRING VET**

Dr. Hallihan

**INVOICE**

36424

**DATE**

3/24/22

The information and recommendations provided are based on the images presented by the referring veterinarian/sonographer. No evaluation can be communicated regarding pathology that was not visible in the image/video clips provided.

Thank you for this referral. If the clinical or image interpretation does not parallel your findings or if I can be of any further assistance please contact me.

Eric Lindquist, DMV, DABVP, Cert. IVUSS, CEO of SonoPath.com

[info@SonoPath.com](mailto:info@SonoPath.com)