



PATIENT

Rufus Bradley

SPECIES

Canine

BREED

Mixed

SEX

Male

AGE

12 Years 9 Months

WEIGHT

23.9 Pounds

INTERPRETED BY

Eric Lindquist, DMV,
DABVP (Canine & Feline), Cert. IVUSS

IMAGING PERFORMED BY

Vincent Ravancho,
CVT

HOSPITAL NAME

Legacy AH

REFERRING VET

Dr. Potenzzone

INVOICE

36343

DATE

3/23/26

PRESENTING CLINICAL SIGNS

- Recheck echo 12/10/25
- Current medications - benazepril, pimobendan, gabapentin, denamarin

ULTRASONOGRAPHIC EXAMINATION OF THE HEART

CANINE CARDIAC PARAMETERS	MR VMAX (m/s)	TR VMAX (m/s)	LA/AO (M-Mode)	LA/AO (Heart Base; Swe)	FS (%)	EF (%)	EPSS (cm)
NORMAL PARAMETER	4.5-5.5	<2.7	1.3	Up to 1.6	28-40	40-100	<0.6
PATIENT	5.24	2.19	1.3	1.0	37	68	0.1
CANINE CARDIAC PARAMETERS	HR (BPM)	AV VMAX (m/s)	PV MAX (m/s)	BODY WEIGHT (lbs)	LAD LA MAX 4 Chamber	LVIDd Avg; 2D and m-mode short axis (cm)	LVIDs Avg; 2D and m-mode short axis (cm)
NORMAL PARAMETER	50-100	0.7-1.7	0.7-1.6				
PATIENT	137	--	--	23.9	3.4	2.59	--

Cardiac Presentation

The echocardiogram in this patient demonstrated normal **left atrial** size based on 3 different LA measurement methods. Chamber volumes and echogenicity were normal. The cranial and caudal **mitral** valve leaflets presented vegetative thickening consistent with endocardiosis. Doppler indicated measurable insufficiency. The **left ventricle** presented thicknesses with linear contour and was not dilated nor restricted. The **myocardium** presented normal echogenicity without subjective evidence of significant fibrotic or ischemic disease. **Contractility** of the ventricular walls was adequate and in normal range for this patient evidenced by the fractional shortening measurement and subjective evaluation of the different regions of the myocardium. The **left ventricular outflow** tract demonstrated normal laminar flow and subjective structural integrity. The **right atrium** and auricle revealed normal size, structure and content. No evidence of masses was noted or chamber overload. **Tricuspid** valvular assessment demonstrated adequate linear morphology. The **right ventricle** was of normal size (1/3 diameter of LV), chordae structure, myocardial echogenicity and thickness. **Pulmonic** tract assessment revealed normal valve structure, laminar flow, and diameter (approx.1:1 pa/ao ratio). No visible **pericardial** or free pleura fluid was noted. No echographically detectable evidence of infiltrative disease was visible. The cranial **mediastinum and pericardial regions** were free of masses in the visible window.

ULTRASONOGRAPHIC FINDINGS

- Compensated mitral insufficiency



PATIENT

- No left atrial enlargement on the current protocol

Rufus Bradley

INTERPRETATION OF THE FINDINGS & FURTHER RECOMMENDATIONS

SPECIES

Recommend continuation of the current protocol and monitoring for systemic hypertension, BUN and creatinine levels.

Canine

BREED

Mixed

SEX

Male

AGE

12 Years 9 Months

WEIGHT

23.9 Pounds

INTERPRETED BY

Eric Lindquist, DMV,
 DABVP (Canine & Feline), Cert. IVUSS

IMAGING PERFORMED BY

Vincent Ravancho,
 CVT

HOSPITAL NAME

Legacy AH

REFERRING VET

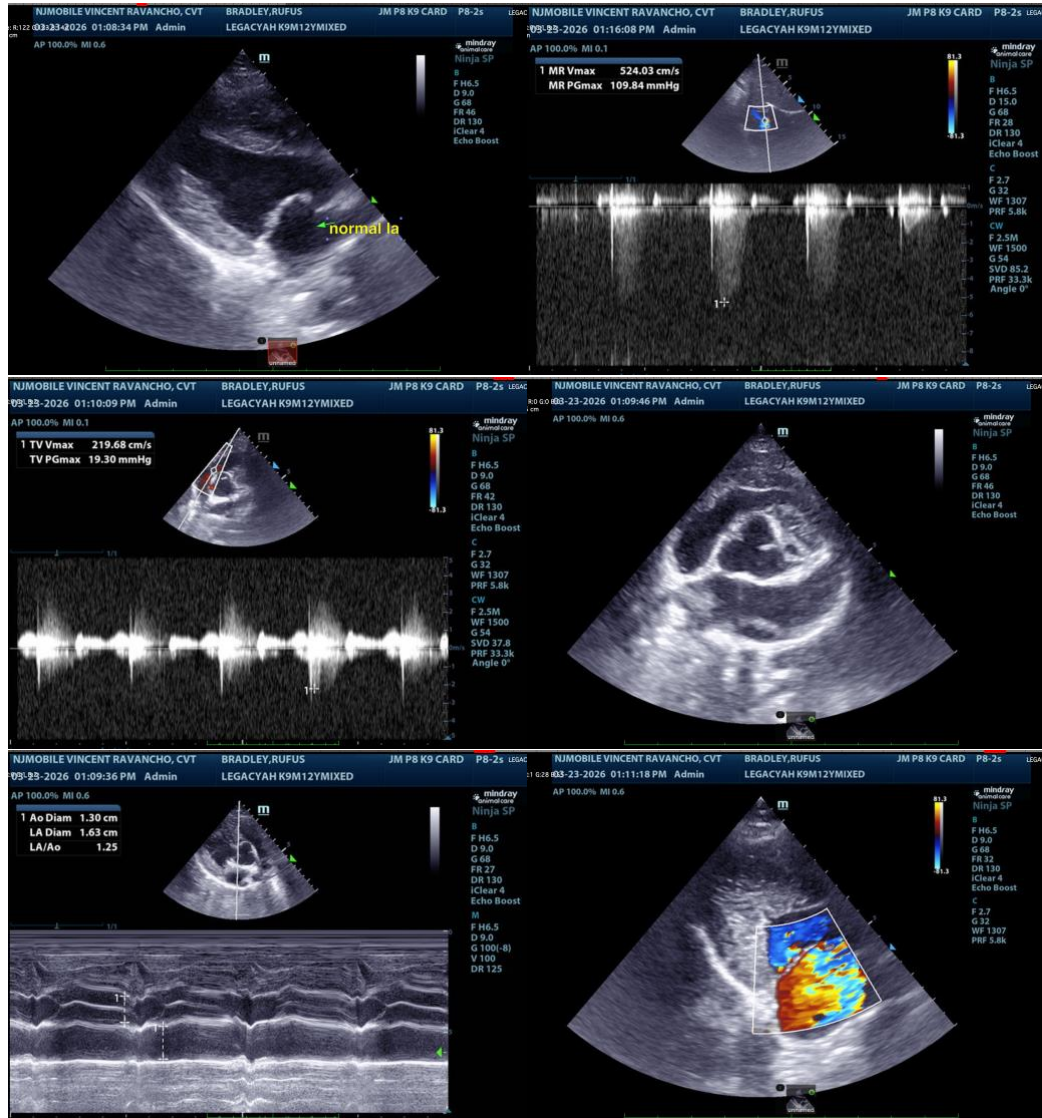
Dr. Potenzzone

INVOICE

36343

DATE

3/23/26





PATIENT

Rufus Bradley

SPECIES

Canine

BREED

Mixed

SEX

Male

AGE

12 Years 9 Months

WEIGHT

23.9 Pounds

INTERPRETED BY

Eric Lindquist, DMV,
 DABVP (Canine &
 Feline), Cert. IVUSS

IMAGING PERFORMED BY

Vincent Ravancho,
 CVT

HOSPITAL NAME

Legacy AH

REFERRING VET

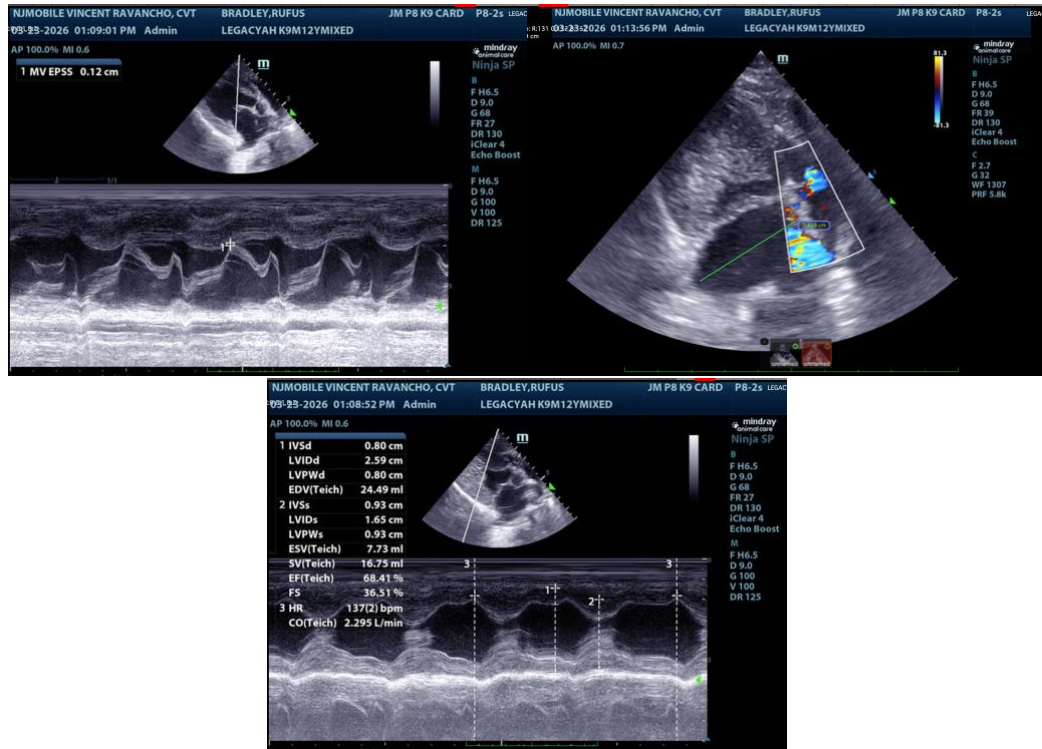
Dr. Potenzzone

INVOICE

36343

DATE

3/23/26



The information and recommendations provided are based on the images presented by the referring veterinarian/sonographer. No evaluation can be communicated regarding pathology that was not visible in the image/video clips provided.

Thank you for this referral. If the clinical or image interpretation does not parallel your findings or if I can be of any further assistance please contact me.

Eric Lindquist, DMV, DABVP(CFM), Cert. IVUSS,
 CEO, Owner, Founder -- SonoPath.com
info@SonoPath.com