



PATIENT

Peanu Denully

SPECIES

Feline

BREED

DSH

SEX

Neutered Male

AGE

12 Years 6 Months

WEIGHT

9.5 Pounds

INTERPRETED BY

Eric Lindquist, DMV,
DABVP (Canine & Feline), Cert. IVUSS

IMAGING PERFORMED BY

Vincent Ravancho,
CVT

HOSPITAL NAME

Legacy AH

REFERRING VET

Dr. Potenzone

INVOICE

36344

DATE

3/23/26

PRESENTING CLINICAL SIGNS

- Baseline Heart Eval
- HM 3/6
- Abnormal PE/Chem/CBC/UA Results: BNP 165, BUN 41, SDMA 18, Creat WNL

ULTRASONOGRAPHIC EXAMINATION OF THE HEART

FELINE CARDIAC PARAMETERS	BODY WEIGHT	HR (BPM)	IVSd (cm)	LVIDd (cm)	LVWd (cm)	FS (%)	EF (%)
NORMAL PARAMETER	-----	150-240	0.3-0.6	1.0-2.1	0.25-0.6	35-67	80-100
PATIENT	9.5 lbs	207	0.54	1.23	0.55	35	68
FELINE CARDIAC PARAMETERS	LA/AO (M-mode)	LA/AO HEART BASE (Sisson)	LAD LA MAX 4 Chamber		LVOT VEL (m/s)	RVOT VEL (m/s)	IVRT (m/)
NORMAL PARAMETER	<1.5	1.6	0.7-1.7		<1.6	<1.3	40-60
PATIENT	1.1	--	1.4		--	1.50	NM

Adapted from June Boon, Veterinary Echocardiography, 1998
Sisson D et al. JVIM 1991; 5: 232, Jacobs et al. Am J Vet Res 1985; 46:1705

EPSS: 0.1

Cardiac Presentation

The echocardiogram in this patient demonstrated normal **left atrial** size based on 3 separate LA measurements. Minor mitral insufficiency was noted, compensated. The **left ventricle** presented normal thicknesses with linear contour and was not dilated nor restricted. The **myocardium** presented normal echogenicity without subjective evidence of significant fibrotic or ischemic disease. **Contractility** of the ventricular walls was adequate and in normal range for this patient evidenced by the fractional shortening measurement and subjective evaluation of the different regions and angles of the myocardium. The **left ventricular outflow** tract demonstrated normal laminar flow and subjective structural integrity. The **right atrium** and auricle revealed normal size, structure and content. No evidence of masses was noted or chamber overload. Trivial **tricuspid** insufficiency was noted in this patient, measuring 2.0 m/s. The **right ventricle** was of normal size (1/3 diameter of LV), chordae structure, myocardial echogenicity and thickness. **Pulmonic** tract assessment revealed normal valve structure, laminar flow, and diameter (approx. 1:1 pa/ao ratio). No visible **pericardial** or free pleura fluid was noted or extra cardiac pathology in the visible planes. The cranial **mediastinum and pericardial regions** were free of masses in the visible window.

ULTRASONOGRAPHIC FINDINGS

- Trivial valvular insufficiency (mitral and tricuspid).
- No evidence of volume overload or structural pathology.



PATIENT

Peanu Denully

SPECIES

Feline

BREED

DSH

SEX

Neutered Male

AGE

12 Years 6 Months

WEIGHT

9.5 Pounds

INTERPRETED BY

Eric Lindquist, DMV,
 DABVP (Canine & Feline), Cert. IVUSS

IMAGING PERFORMED BY

Vincent Ravancho,
 CVT

HOSPITAL NAME

Legacy AH

REFERRING VET

Dr. Potenzzone

INVOICE

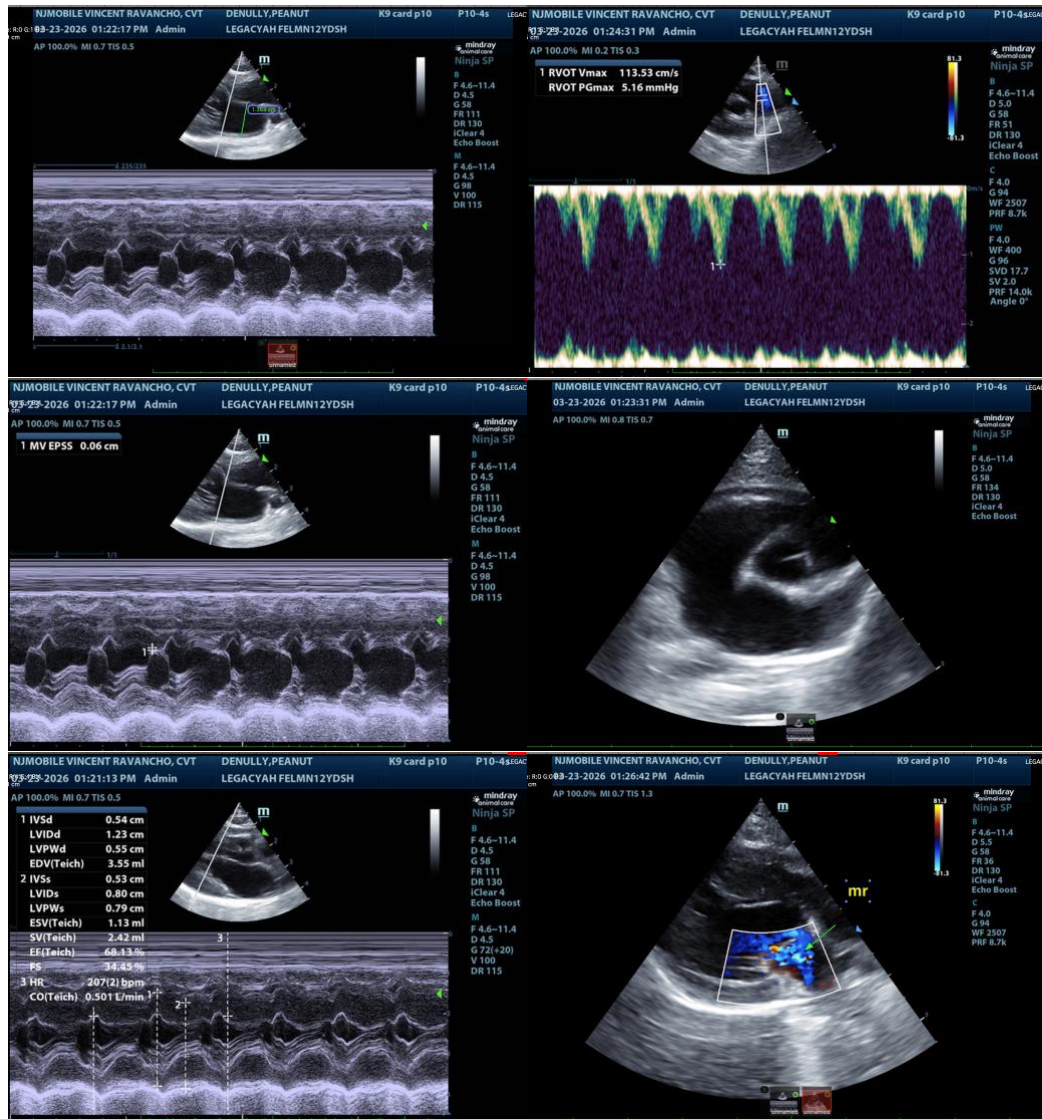
36344

DATE

3/23/26

INTERPRETATION OF THE FINDINGS & FURTHER RECOMMENDATIONS

No treatment is necessary in this patient. No contraindication to anesthetic procedure if needed.





PATIENT

Peanu Denully

SPECIES

Feline

BREED

DSH

SEX

Neutered Male

AGE

12 Years 6 Months

WEIGHT

9.5 Pounds

INTERPRETED BY

Eric Lindquist, DMV,
 DABVP (Canine & Feline), Cert. IVUSS

IMAGING PERFORMED BY

Vincent Ravancho,
 CVT

HOSPITAL NAME

Legacy AH

REFERRING VET

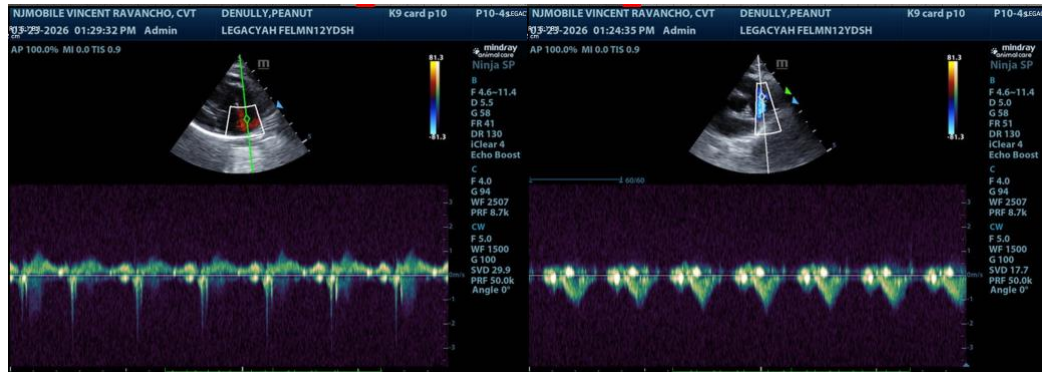
Dr. Potenzzone

INVOICE

36344

DATE

3/23/26



The information and recommendations provided are based on the images presented by the referring veterinarian/sonographer. No evaluation can be communicated regarding pathology that was not visible in the image/video clips provided.

Thank you for this referral. If the clinical or image interpretation does not parallel your findings or if I can be of any further assistance please contact me.

Eric Lindquist, DMV, DABVP(CFM), Cert. IVUSS,
 CEO, Owner, Founder -- SonoPath.com
info@SonoPath.com