



## PATIENT

Maya Jackson

## SPECIES

Canine

## BREED

Chihuahua

## SEX

Female

## AGE

5 years

## WEIGHT

6.8 lbs

## PRESENTING CLINICAL SIGNS

- Having bloody diarrhea since Thursday. Owner did give her butter in her oatmeal. Concern for pancreatitis. Not eating as well as normal
- cPL normal rest of labs are pending has hx of elevated ALT

## ULTRASONOGRAPHIC EXAMINATION OF THE ABDOMEN

### Urinary System

The **urinary bladder**, trigone, and pelvic urethra presented normal thicknesses and normal tone. The ureters were not visible which is normal. No uroliths or sediment were visualized and anechoic urine was present. No evidence of inflammatory or neoplastic changes was noted. Ureteral papillae were normal.

The **kidneys** revealed largely normal structure, corticomedullary definition and ratio (cortex 1/3 of medulla) were essentially maintained with some age-related loss of curvilinear patterns regarding the capsule and C/M junction. The cortices presented largely uniform texture with some increased echogenicity expected for this age patient. Medullary structure differed distinctly from that of the cortex and no evidence of pelvic dilation was present. Mild mineralization was noted in the kidneys. The right kidney measured 3.2 cm. The left kidney was subnormal in size and measured 2.48 cm.

## INTERPRETED BY

Eric Lindquist, DMV  
DABVP, Cert. IVUSS

## IMAGING PERFORMED BY

Kathleen Laux

## HOSPITAL NAME

Rondout Valley VA

## REFERRING VET

Dr. Laux

## INVOICE

73713

## DATE

3/23/26

### Adrenal Glands

Both **adrenal glands** were visualized and recognized as having normal shape, size, position and echogenicity for this breed. The phrenic vasculature, glandular echogenicity and detail were unremarkable. Capsule, cortex, and medullary definition were normal for this age patient. The left adrenal gland measured 0.39 cm. The right adrenal gland measured 0.23 cm.

### Spleen

The **spleen** presented a smooth homogeneous parenchyma hyperechoic to liver and renal cortical parenchyma. The capsule was smooth without noticeable expansion or deviation from within the spleen or adjacent pathology. The splenic vasculature demonstrated normal volume without signs of congestion or thrombosis. No sonographic evidence of acute or chronic inflammatory, neoplastic, or infarctual changes was noted.

### Liver

The **liver** images submitted revealed subjectively normal liver size, contour, and structure. Parenchymal echogenicity was naturally coarse and hypoechoic to the spleen. Vascular and biliary tracts were of normal volume with no evidence of congestion. The gallbladder presented acceptably thin walls with primarily anechoic content. The cystic and common bile ducts were normal. No pathological hepatic lymphadenopathy was evident. No overt structural evidence of inflammatory, infiltrative or regenerative pathology was evident.



## PATIENT

Maya Jackson

## SPECIES

Canine

## BREED

Chihuahua

## SEX

Female

## AGE

5 years

## WEIGHT

6.8 lbs

## INTERPRETED BY

Eric Lindquist, DMV  
DABVP, Cert. IVUSS

## IMAGING PERFORMED BY

Kathleen Laux

## HOSPITAL NAME

Rondout Valley VA

## REFERRING VET

Dr. Laux

## INVOICE

73713

## DATE

3/23/26

## Gastrointestinal

The **gastric** wall was mildly thickened with anechoic fluid. The small intestines and colon were unremarkable with normal curvilinear mural patterns and content. Underlying low-grade gastritis is suspected.

## Pancreas

The base and limbs of the **pancreas** were observed to be largely isoechoic to surrounding omental fat. Some parenchymal remodeling, however, with mild deviation from curvilinear normalcy was observed. Pancreatic duct and capsular irregularities were present consistent with age related changes. If pain upon imaging (+ Murphy sign) was present or if the patient is focally painful in subxiphoid palpation then low-grade smoldering chronic pancreatitis should be suspected.

## ULTRASONOGRAPHIC FINDINGS

Gastritis pattern. Low-grade gastritis is suspected in this patient.

Slight renal mineralization.

Moderate left renal changes, minor right renal changes. Slight mineralization was noted.

## INTERPRETATION OF THE FINDINGS & FURTHER RECOMMENDATIONS

Diet change, GI protectant protocol such as the following should be considered.

### Helicobacter/Gastritis protocol

A clinical trial of **Zithromax (Dogs: 5-10 mg/kg p.o. q24h. May increase dosing interval to q48h after 3-5 days of treatment)**, **Metronidazole (10-20 mg/kg p.o. b.i.d.)**, **Pepcid (0.5-1 mg/kg s.i.d.)** and **Sucralfate (0.5-2 g/dog PO)** or **Omeprazole (1 mg/kg p.o. s.i.d.)** over the next 3 weeks along with a **novel-protein or hydrolyzed diet** with slurry feeding b.i.d./t.i.d. over the next 2-4 days and then increase to canned diet bid. Dry food should be avoided over the next 4 weeks. A recheck sonogram to assess GI improvement or progression would be ideal in 4 weeks.



**PATIENT**

Maya Jackson

**SPECIES**

Canine

**BREED**

Chihuahua

**SEX**

Female

**AGE**

5 years

**WEIGHT**

6.8 lbs

**INTERPRETED BY**

Eric Lindquist, DMV  
DABVP, Cert. IVUSS

**IMAGING PERFORMED BY**

Kathleen Laux

**HOSPITAL NAME**

Rondout Valley VA

**REFERRING VET**

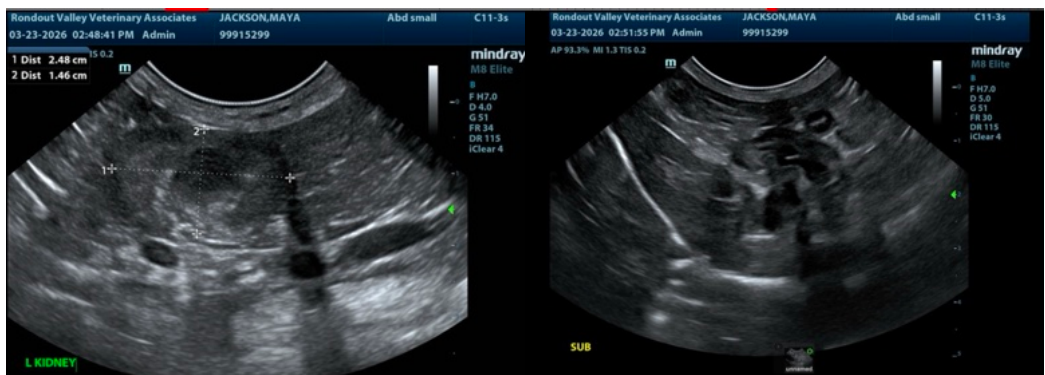
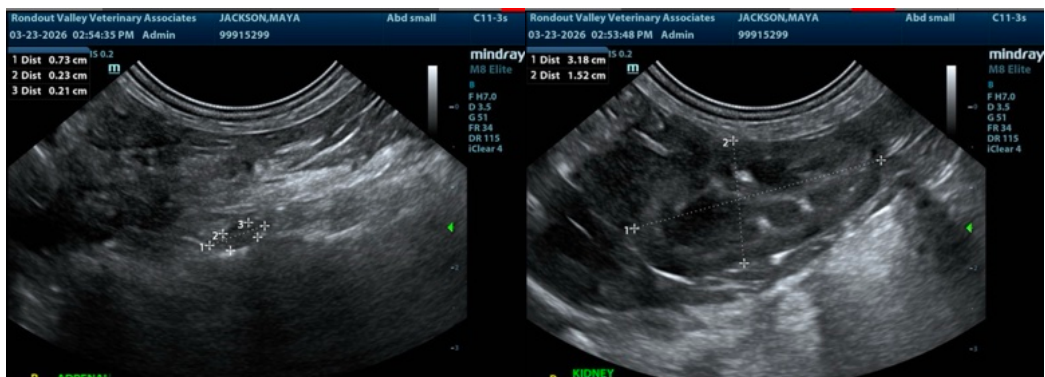
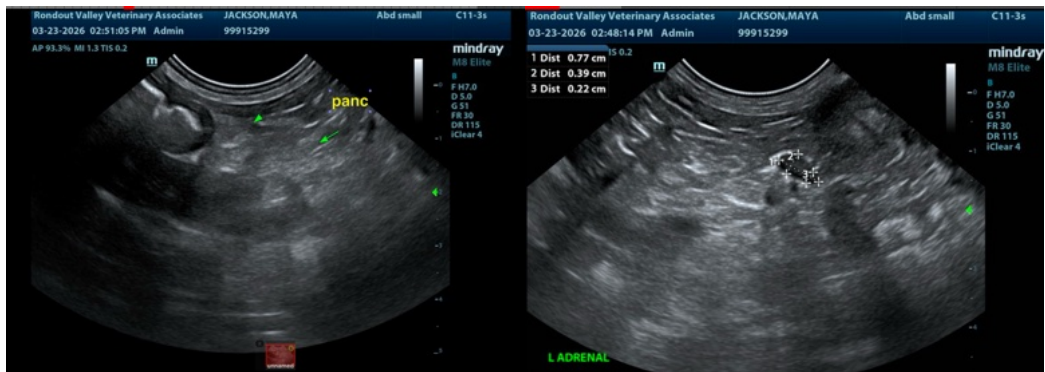
Dr. Laux

**INVOICE**

73713

**DATE**

3/23/26



The information and recommendations provided are based on the images presented by the referring veterinarian/sonographer. No evaluation can be communicated regarding pathology that was not visible in the image/video clips provided.

Thank you for this referral. If the clinical or image interpretation does not parallel your findings or if I can be of any further assistance please contact me.

Eric Lindquist, DMV, DABVP (CFM), Cert. IVUSS, CEO of SonoPath.com

[info@SonoPath.com](mailto:info@SonoPath.com)