



PATIENT

Luna Lozada

SPECIES

Canine

BREED

Bull Terrier

SEX

Female

AGE

8 years

WEIGHT

29 lbs

INTERPRETED BY

Eric Lindquist, DMV
DABVP, Cert. IVUSS

PRESENTING CLINICAL SIGNS

- rDVM heard a murmur on an exam in November 2025 and recommended an echo prior to ohe and dental
- Grade 1 murmur today on exam

ULTRASONOGRAPHIC EXAMINATION OF THE HEART

The echocardiogram in this patient demonstrated normal **left atrial** size based on 3 separate methods of LA evaluation. The cranial and caudal **mitral** valve leaflets presented normal linear structure, extension in systole, and union in diastole with normal kinesis. The **left ventricle** presented thicknesses with linear contour and was not dilated nor restricted. The **myocardium** presented normal echogenicity without subjective evidence of significant fibrotic or ischemic disease. **Contractility** of the ventricular walls was adequate and in normal range for this patient evidenced by the fractional shortening measurement and subjective evaluation of the different regions of the myocardium. The **left ventricular outflow** tract demonstrated normal laminar flow and subjective structural integrity. The **right atrium** and auricle revealed normal size, structure and content. No evidence of masses was noted. **Tricuspid** valvular assessment demonstrated adequate linear morphology and kinesis. The **right ventricle** was of normal size (1/3 diameter of LV), chordae structure, myocardial echogenicity and thickness. **Pulmonary outflow** tract assessment revealed normal valve structure, laminar flow, and diameter (approx. 1:1 pa/ao ratio). No visible **pericardial** or free pleura fluid was noted. The cranial **mediastinum and pericardial and extra-cardiac regions** were free of masses in the visible window.

E Wave Velocity 0.9

IMAGING PERFORMED BY

Bill McGee

HOSPITAL NAME

Bridgeport AH PLLC

REFERRING VET

Dr. Smith

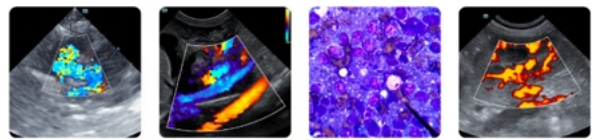
INVOICE

73718

DATE

3/23/26

CANINE CARDIAC PARAMETERS	MR VMAX (m/s)	TR VMAX (m/s)	LA/AO	LA/AO (Heart Base)	FS (%)	EF (%)	EPSS (cm)
NORMAL PARAMETER	4.5-5.5	<2.7	1.3	<1.6	28-40	40-100	<0.6
PATIENT	-	-	1.18	1.3	32	71	0.15
CANINE CARDIAC PARAMETERS	HR (BPM)	AV VMAX (m/s)	PV MAX (m/s)	BODY WEIGHT	LA 2D short axis Base view (cm)	LVIDd Avg; 2D and m-mode short axis (cm)	LVIDs Avg; 2D and m-mode short axis (cm)
NORMAL PARAMETER	50-100	0.7-1.7	0.7-1.6	BELOW	BELOW	BELOW	BELOW
PATIENT	150	1.76	1.45	29 lbs	2.68	3.0	



PATIENT

Luna Lozada

SPECIES

Canine

BREED

Bull Terrier

SEX

Female

AGE

8 years

WEIGHT

29 lbs

INTERPRETED BY

Eric Lindquist, DMV
DABVP, Cert. IVUSS

IMAGING PERFORMED BY

Bill McGee

HOSPITAL NAME

Bridgeport AH PLLC

REFERRING VET

Dr. Smith

INVOICE

73718

DATE

3/23/26

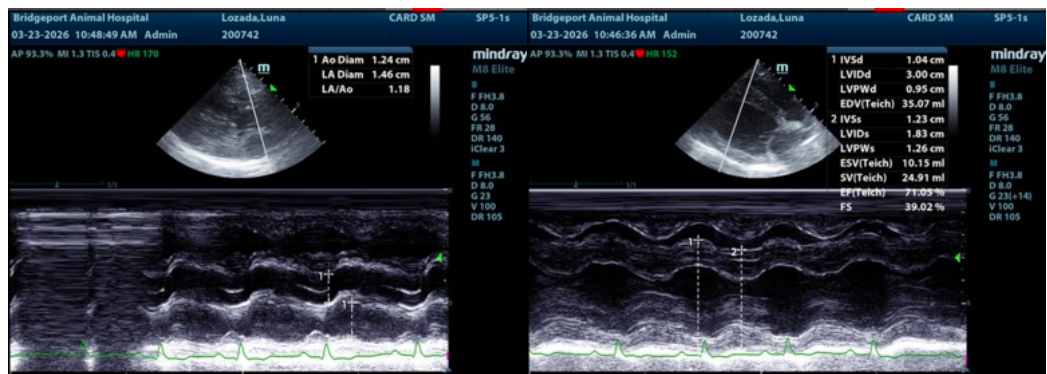
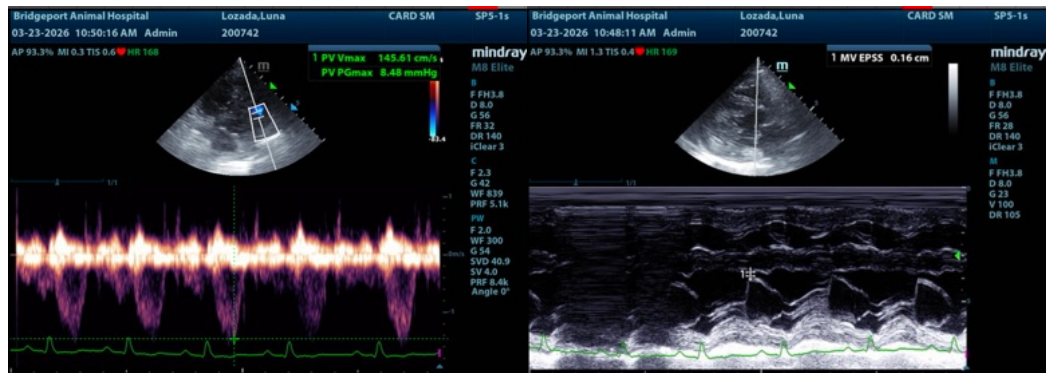
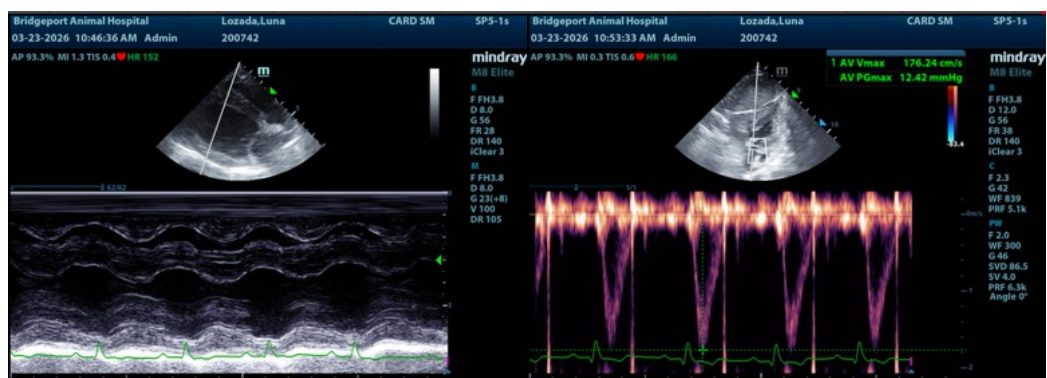
ULTRASONOGRAPHIC FINDINGS

Idiopathic flow murmur.

Essentially a normal heart.

INTERPRETATION OF THE FINDINGS & FURTHER RECOMMENDATIONS

The exact cause of the murmur is unclear, yet it is not hemodynamically significant.





PATIENT

Luna Lozada

SPECIES

Canine

BREED

Bull Terrier

SEX

Female

AGE

8 years

WEIGHT

29 lbs

INTERPRETED BY

Eric Lindquist, DMV
DABVP, Cert. IVUSS

IMAGING PERFORMED BY

Bill McGee

HOSPITAL NAME

Bridgeport AH PLLC

REFERRING VET

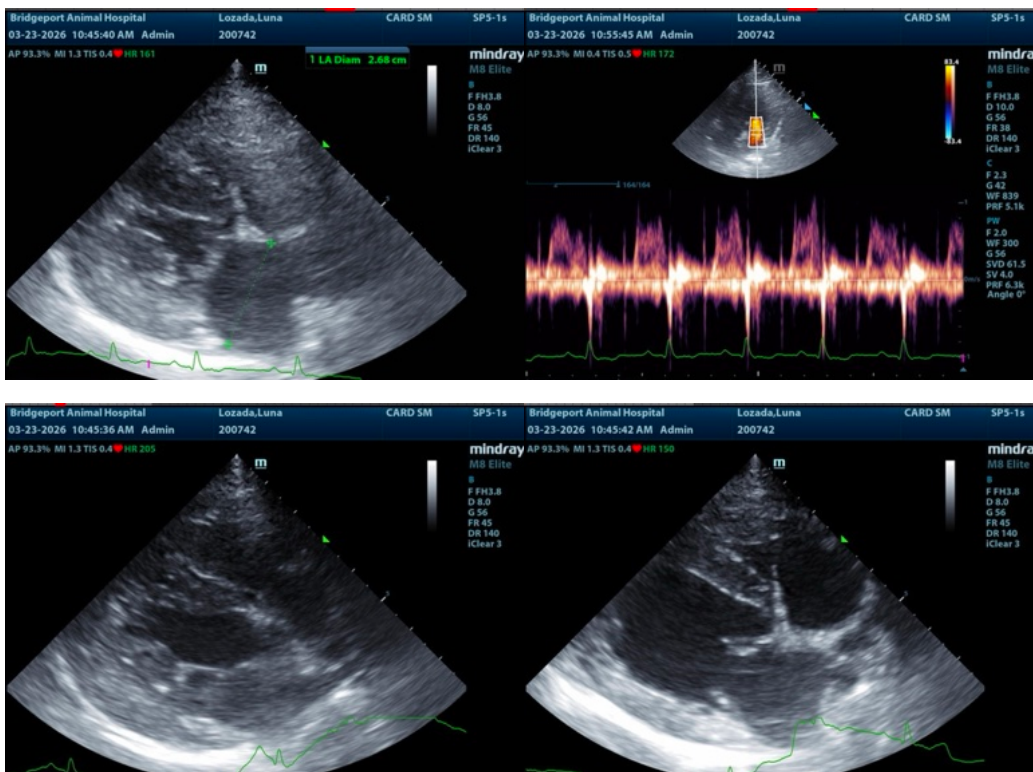
Dr. Smith

INVOICE

73718

DATE

3/23/26



The information and recommendations provided are based on the images presented by the referring veterinarian/sonographer. No evaluation can be communicated regarding pathology that was not visible in the image/video clips provided.

Thank you for this referral. If the clinical or image interpretation does not parallel your findings or if I can be of any further assistance please contact me.

Eric Lindquist, DMV, DABVP (CFM), Cert. IVUSS, CEO of SonoPath.com

info@SonoPath.com