



PATIENT

Charlie Kogan

SPECIES

Canine

BREED

Labradoodle

SEX

Spayed Female

AGE

12 Years 5 Months

WEIGHT

13.2 Pounds

INTERPRETED BY

Eric Lindquist, DMV,
 DABVP (Canine & Feline), Cert. IVUSS

IMAGING PERFORMED BY

Vincent Ravancho,
 CVT

HOSPITAL NAME

Summit Dog & Cat Hospital

REFERRING VET

Dr. Baker

INVOICE

36346

DATE

3/23/26

PRESENTING CLINICAL SIGNS

- Cardiac Recheck, last Echo 6/25/25
- Stable Stage B1 Valvular disease please compare
- Cardiac III/VI
- No cardiac clinical signs, no cardiac meds

ULTRASONOGRAPHIC EXAMINATION OF THE HEART

CANINE CARDIAC PARAMETERS	MR VMAX (m/s)	TR VMAX (m/s)	LA/AO (M-Mode)	LA/AO (Heart Base; Swe)	FS (%)	EF (%)	EPSS (cm)
NORMAL PARAMETER	4.5-5.5	<2.7	1.3	Up to 1.6	28-40	40-100	<0.6
PATIENT	5.56	1.74	NM	--	44	77	0.1
CANINE CARDIAC PARAMETERS	HR (BPM)	AV VMAX (m/s)	PV MAX (m/s)	BODY WEIGHT	LAD LA MAX 4 Chamber	LVIDd Avg; 2D and m-mode short axis (cm)	LVIDs Avg; 2D and m-mode short axis (cm)
NORMAL PARAMETER	50-100	0.7-1.7	0.7-1.6				
PATIENT	189	1.50	1.07	13.2 lbs	3.1	2.82	--

Cardiac Presentation

The cardiac presentation in this patient presented persistent mitral and tricuspid insufficiency with no significant volume overload and no progression from the prior echocardiogram. Contractility and volumes were contained. Slight prolapse of the anterior mitral valve leaflet was noted in this patient with moderate filling of the left atrium on colorflow assessment. No pericardial or pleural disease was noted in the acoustic views available. The hepatic veins were not dilated.

ULTRASONOGRAPHIC FINDINGS

- Compensated stage B-1 valvular disease with slight mitral valve prolapse

INTERPRETATION OF THE FINDINGS & FURTHER RECOMMENDATIONS

Serial blood pressures are warranted. Recommend maintaining the current management.

The heart is stable without clinical disease. No overt contraindication for anesthesia of brief to moderate duration. I suggest Torbutrol premed, Propofol induction, Isoflor maintenance or similar



PATIENT

Charlie Kogan

SPECIES

Canine

BREED

Labradoodle

SEX

Spayed Female

AGE

12 Years 5 Months

WEIGHT

13.2 Pounds

INTERPRETED BY

Eric Lindquist, DMV,
 DABVP (Canine &
 Feline), Cert. IVUSS

IMAGING PERFORMED BY

Vincent Ravancho,
 CVT

HOSPITAL NAME

Summit Dog & Cat
 Hospital

REFERRING VET

Dr. Baker

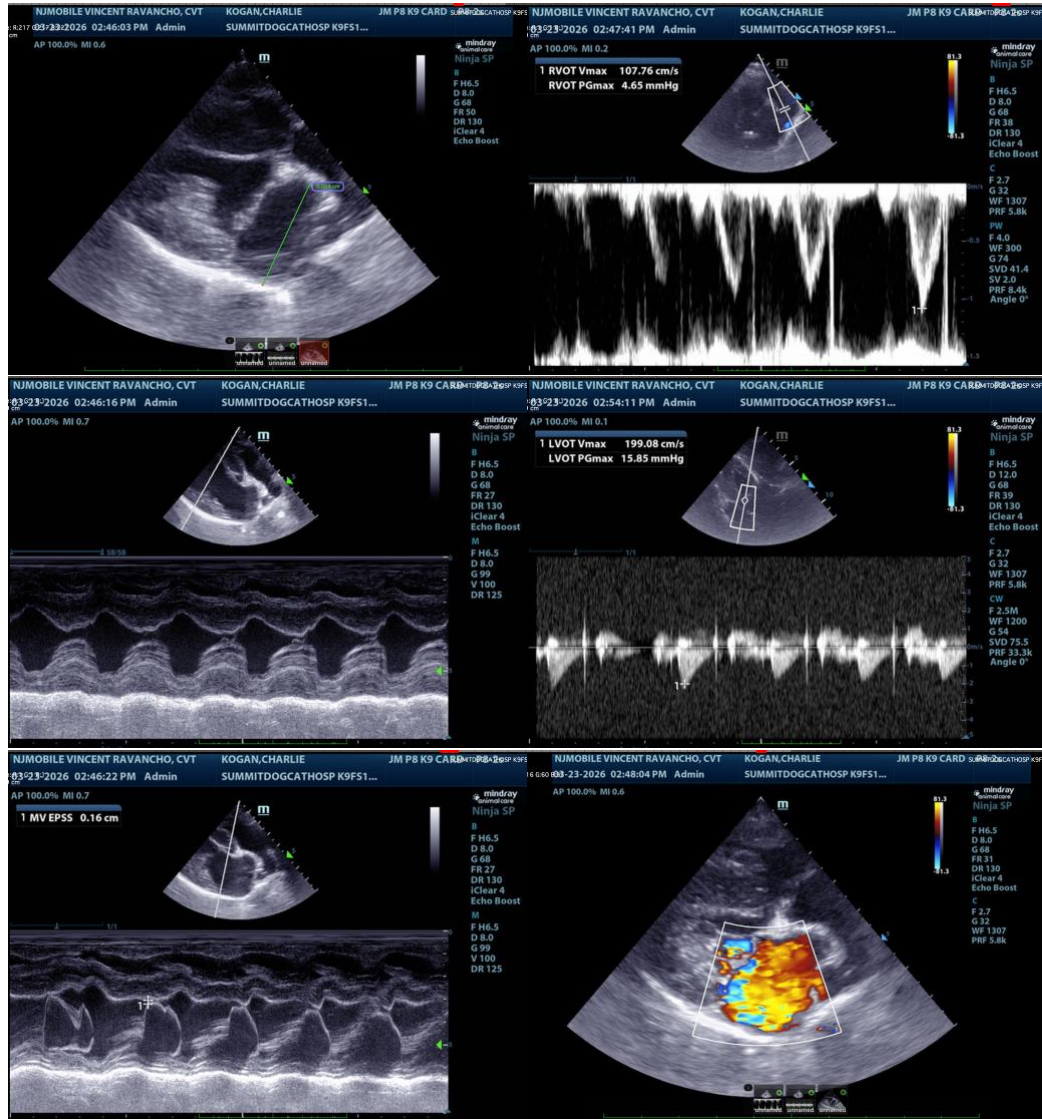
INVOICE

36346

DATE

3/23/26

protocol if anesthesia is desired. Blood pressure recommended if not already performed and target white coat negative systolic pressure of < 160 mmHg. If higher than this ACE-inhibitor is suggested to reach this level. Recheck echocardiogram is recommended in 6 months, earlier if murmur grade increases or clinical signs initiate.





PATIENT

Charlie Kogan

SPECIES

Canine

BREED

Labradoodle

SEX

Spayed Female

AGE

12 Years 5 Months

WEIGHT

13.2 Pounds

INTERPRETED BY

Eric Lindquist, DMV,
 DABVP (Canine &
 Feline), Cert. IVUSS

**IMAGING
 PERFORMED BY**

Vincent Ravancho,
 CVT

HOSPITAL NAME

Summit Dog & Cat
 Hospital

REFERRING VET

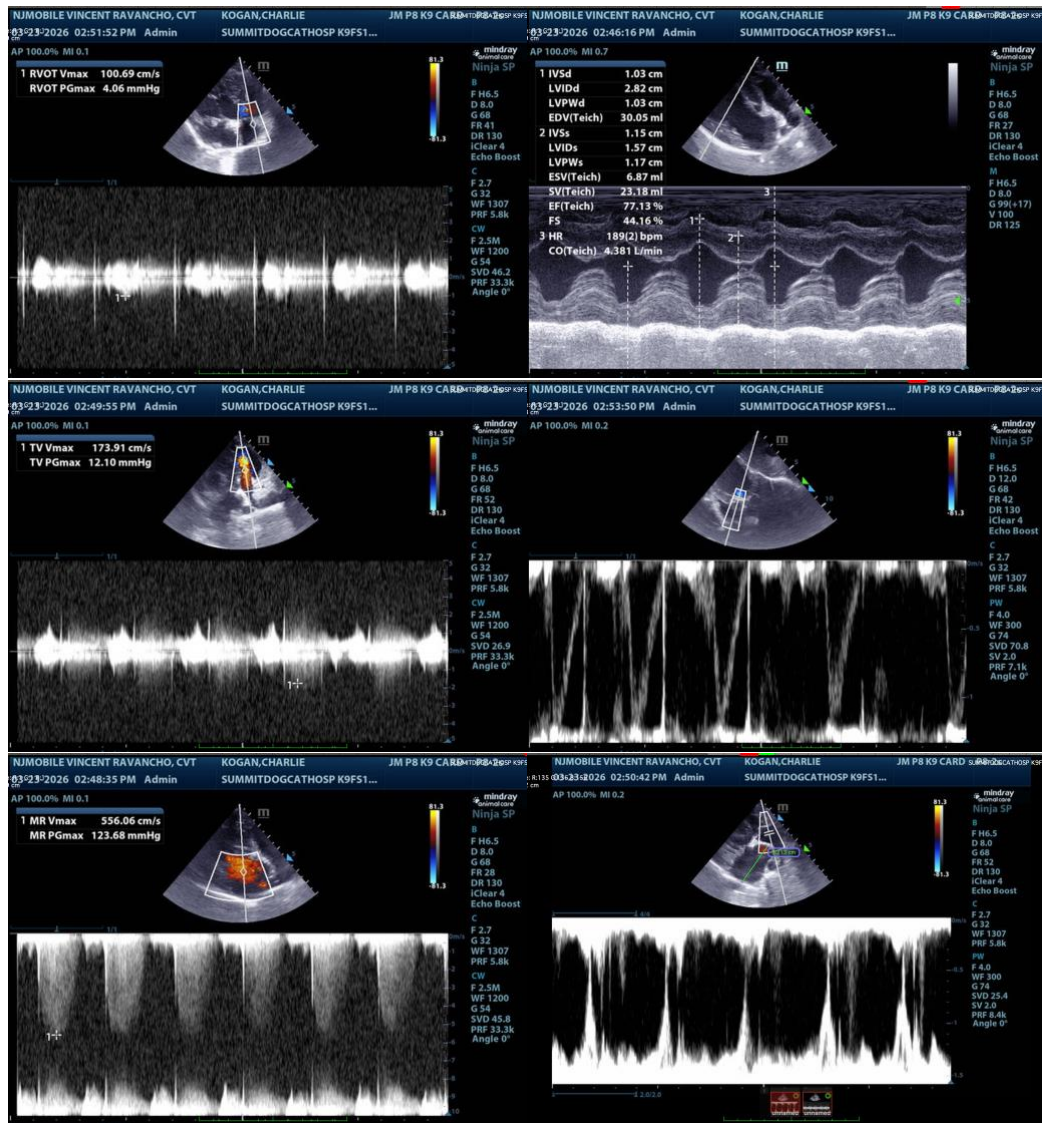
Dr. Baker

INVOICE

36346

DATE

3/23/26



The information and recommendations provided are based on the images presented by the referring veterinarian/sonographer. No evaluation can be communicated regarding pathology that was not visible in the image/video clips provided.

Thank you for this referral. If the clinical or image interpretation does not parallel your findings or if I can be of any further assistance please contact me.

Eric Lindquist, DMV, DABVP(CFM), Cert. IVUSS,
 CEO, Owner, Founder -- SonoPath.com
info@SonoPath.com