

**DATE**

3/23/22

**PRESENTING CLINICAL SIGNS**

P presented for bloody/foul smelling urine (3/2/22), detected UTI with a free catch urine sample. Following a course of Enrofloxacin, o believes p still having urinary issues due to very potent urine (blood appears gone). Due to p high level of aggression, elected for a sedated procedure to collect urine via cystocentesis. While p was sedated, more thorough exam was performed and palpated a large (L) cranial abdominal mass. No further history noted. Intrapet was already here with other scans; therefore, approved this since sedated. Current Medications: Fluoxetine 20mg SID.

Date of Previous IntraPet Ultrasound: No previous.

Sedation: Dexdomitor/Torbugesic.

Stat Report: Not requested.

Imaging Performed By: Stephanie Pearce RDCS, RVT.

**PATIENT**

Anna Beth Parke

**SPECIES**

Canine

**BREED**

Labrador Mix

**SEX**

Spayed Female

**AGE**

5/2/09

**WEIGHT**

43.7 lbs

**INTERPRETED BY**Eric Lindquist, DMV  
DABVP, Cert. IVUSS**ULTRASONOGRAPHIC EXAMINATION OF THE ABDOMEN****Urinary System**

The **urinary bladder**, trigone, and pelvic urethra presented normal thicknesses and normal tone. The ureters were not visible which is normal. No uroliths or sediment were visualized and anechoic urine was present. No evidence of inflammatory or neoplastic changes was noted. Ureteral papillae were normal.

The **kidneys** revealed normal size and structure, corticomedullary definition and ratio for this age. The cortices presented largely uniform texture with normal echogenic relationship to liver and spleen. Medullary structure differed distinctly from the cortex and no evidence of pelvic dilation was present. The capsules were acceptably uniform without significant irregularities. The right kidney measured 5.8 cm with slight pyelectasia. The left kidney measured 6.31 cm.

**Adrenal Glands**

Both **adrenal glands** were visualized and recognized as having largely normal shape, size, position and acceptable echogenicity for this age group and breed. Some heterogeneity was noted within the adrenal parenchyma without concerning capsular distortion. These changes are likely age related but should be monitored by sonogram should the patient be suspected of having adrenal disease. The right adrenal gland measured 3.73 x 0.57 cm at the caudal pole and 0.64 cm at the cranial pole. The left adrenal gland measured 2.85 x 0.72 cm at the caudal pole and 0.49 cm at the cranial pole.

**HOSPITAL NAME**

Fullerton AH

**Spleen**

The **spleen** revealed an expansive parenchymal mass. The splenic mass measured 4.9 x 3.8 cm.

**REFERRING VET**

Dr. Stock

**Liver**

The **liver** presented heterogenous parenchyma with increased portal markings and coarse architecture. Slight undulating capsular contour was noted. Hypoechoic nodular changes were noted and this may be related to the splenic pathology. The gallbladder and common bile duct were unremarkable. This is consistent with chronic inflammatory hepatopathy.

**INVOICE**

97725

**Gastrointestinal**

Examination of the **gastrointestinal tract** revealed a stomach and intestine free of stasis, of normal wall thickness, acceptable curvilinear mural detail, and peristaltic activity. Small and large intestine demonstrated normal luminal chyme and stool consistency respectively. The mesenteric lymph node was reactive and measured 1.43 x 1.0 cm.

### Pancreas

The base and limbs of the **pancreas** were observed to be largely isoechoic to surrounding omental fat. Pancreatic duct and capsular contour were acceptably normal and parenchyma respected normal curvilinear patterns. No overt evidence of active inflammatory or neoplastic disease was noted.

### Heart

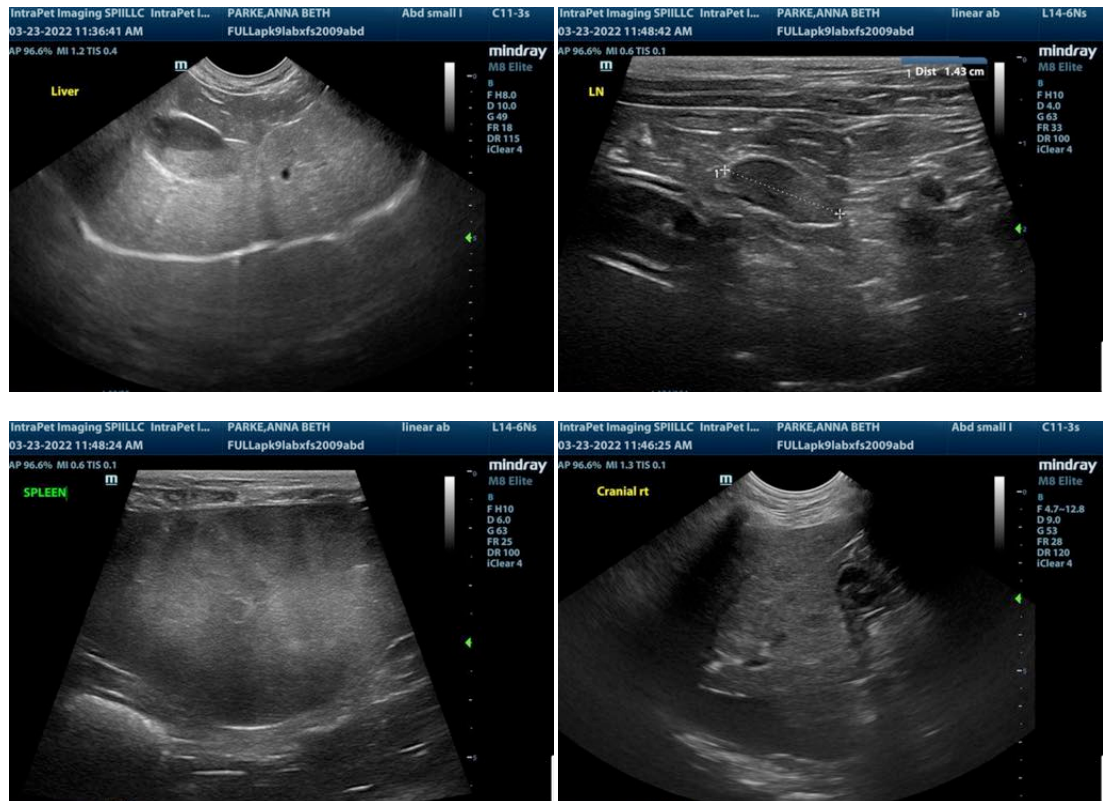
Rapid view of the heart revealed no evidence of pathology.

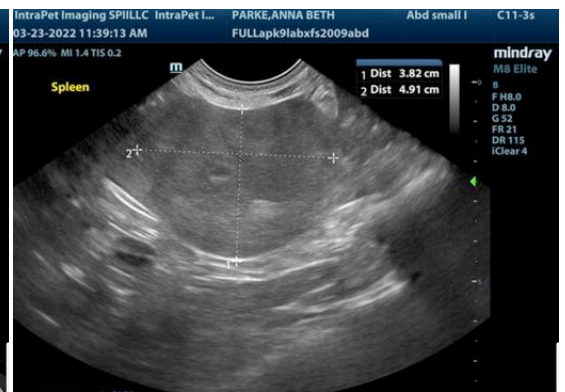
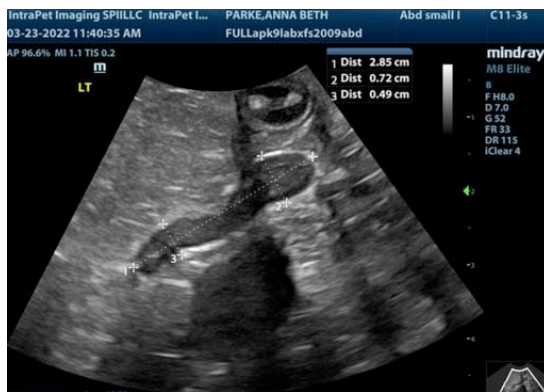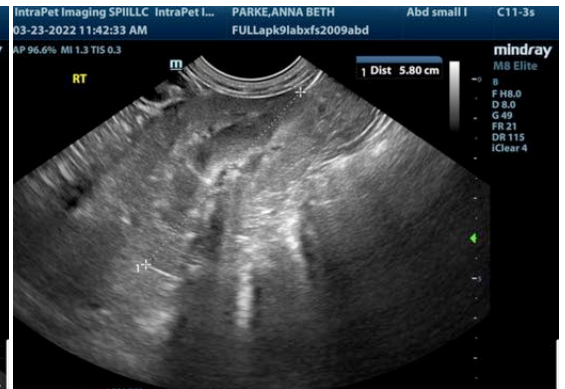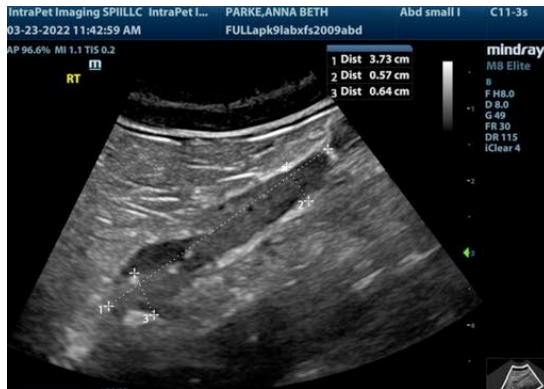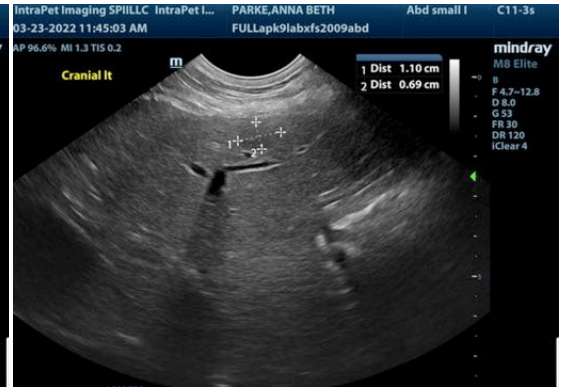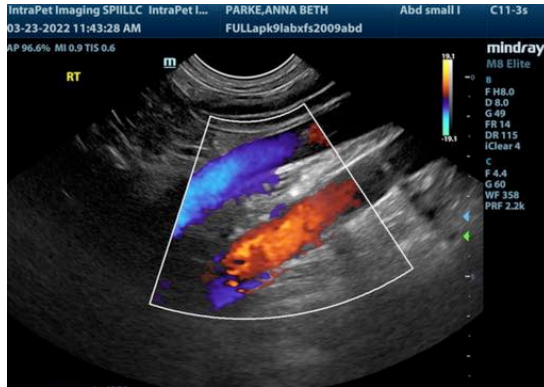### ULTRASONOGRAPHIC FINDINGS

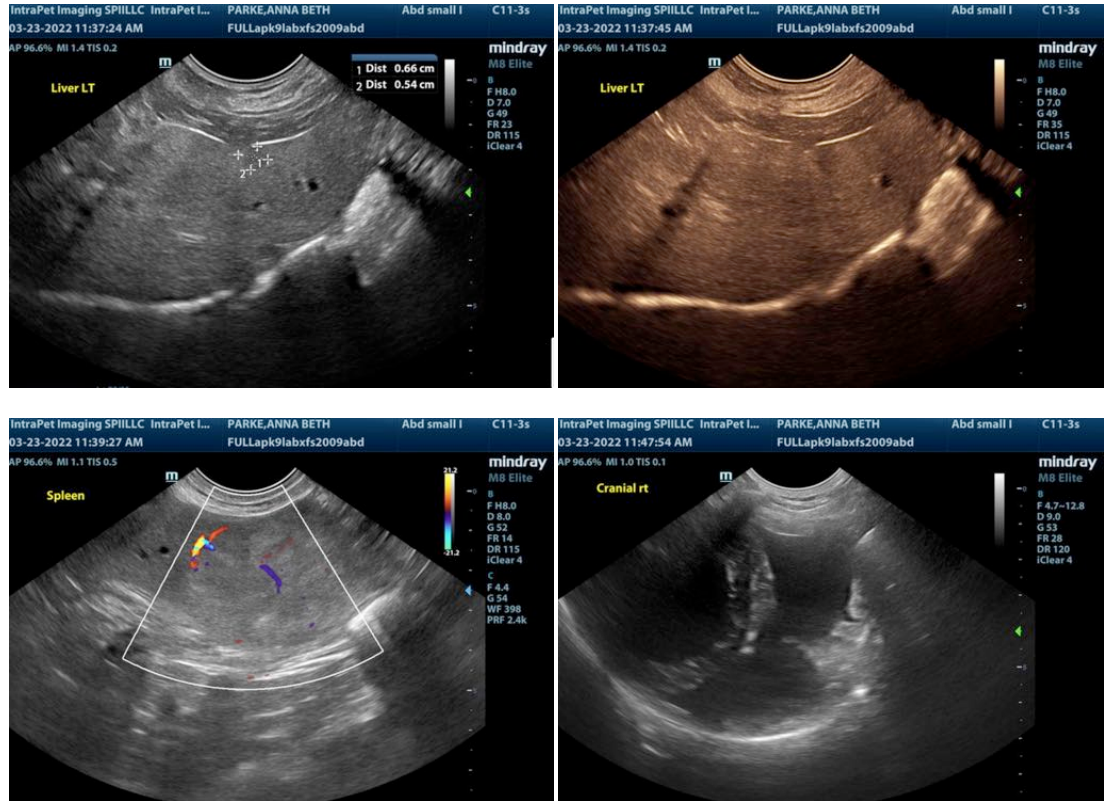
Parenchymal splenic mass with hepatic remodeling and subtle nodular changes. Otherwise, age related abdominal changes.

### INTERPRETATION OF THE FINDINGS & FURTHER RECOMMENDATIONS

FNA of the spleen and liver nodules are recommended. The splenic mass is likely an incidental finding, yet it is precarious and moderately vascular. If the hepatic nodular changes are benign then splenectomy and liver biopsy is indicated or direct splenectomy and liver biopsy could be considered. Subjectively the hepatic nodules are likely benign, yet FNA is warranted to eliminate the potential of malignancy. Three view chest radiographs are warranted prior to surgery or sampling.







The information and recommendations provided are based on the images presented by the referring veterinarian. No evaluation can be communicated regarding pathology that was not visible in the image/video clips provided.

Thank you for this referral. If the clinical or image interpretation does not parallel your findings or if I can be of any further assistance please contact me.

**Eric Lindquist, DMV, DABVP, Cert. IVUSS, CEO of SonoPath.com**  
 Eric.Lindquist@SonoPath.com