



PATIENT

Sophie Ruley

PRESENTING CLINICAL SIGNS

History: Chronic intermittent vomiting and diarrhea that responds to metronidazole
Abnormal PE/Chem/CBC/UA Results: PE: WNL CBC/CHEM performed at other clinics wnl

SPECIES

Canine

ULTRASONOGRAPHIC EXAMINATION OF THE ABDOMEN

Urinary System

BREED

Yorkie

The **urinary bladder**, trigone, and pelvic urethra presented normal thicknesses and normal tone. The pelvic urethra was imaged 2.0 cm beyond the cystourethral junction. The ureters were not visible which is normal. No uroliths or sediment were visualized and anechoic urine was present. No evidence of inflammatory or neoplastic changes was noted. Ureteral papillae were normal.

SEX

Spayed Female

The **kidneys** revealed normal size and structure, corticomedullary definition and ratio for this age. The cortices presented largely uniform texture with normal echogenic relationship to liver and spleen. Medullary structure differed distinctly from the cortex and no evidence of pelvic dilation was present. The capsules were acceptably uniform without significant irregularities. The kidneys measured 4.0 cm each.

AGE

5 years

WEIGHT

9 lbs

Adrenal Glands

The left **adrenal gland** was visualized and recognized as having normal shape, size, position and echogenicity for this breed. The phrenic vasculature, glandular echogenicity and detail were unremarkable. Capsule, cortex, and medullary definition were normal for this age patient. The left adrenal gland measured 0.5 cm. The right adrenal gland was not visualized.

INTERPRETED BY

Eric Lindquist, DMV
DABVP, Cert. IVUSS

Spleen

The **spleen** presented a smooth homogeneous parenchyma hyperechoic to liver and renal cortical parenchyma. The capsule was smooth without noticeable expansion or deviation from within the spleen or adjacent pathology. The splenic vasculature demonstrated normal volume without signs of congestion or thrombosis. No sonographic evidence of acute or chronic inflammatory, neoplastic, or infarctual changes was noted.

IMAGING PERFORMED BY

Dr. Griffin

HOSPITAL NAME

Northside VC

Liver

The **liver** was slightly subnormal in size, yet uniform parenchyma. Mildly increased portal markings and minor remodeling was present. The gallbladder presented acceptably thin walls with primarily anechoic content. The cystic and common bile ducts were normal. No pathological hepatic lymphadenopathy was evident. No overt structural evidence of inflammatory, infiltrative or regenerative pathology was evident.

REFERRING VET

Dr. Griffin

INVOICE

97082

DATE

3/22/22

Gastrointestinal

The **stomach** revealed retention of ingesta. The pylorus was free of evident pathology. Transit of chyme into the small intestine was unremarkable. The colon presented hard stool.



PATIENT

Pancreas

Sophie Ruley

The base and limbs of the **pancreas** were observed to be largely isoechoic to surrounding omental fat. Pancreatic duct and capsular contour were acceptably normal and parenchyma respected normal curvilinear patterns. No overt evidence of active inflammatory or neoplastic disease was noted.

SPECIES

Canine

ULTRASONOGRAPHIC FINDINGS

BREED

Yorkie

Retention of ingesta.

Mild microhepatica.

Structurally unremarkable abdomen.

SEX

Spayed Female

INTERPRETATION OF THE FINDINGS & FURTHER RECOMMENDATIONS

AGE

5 years

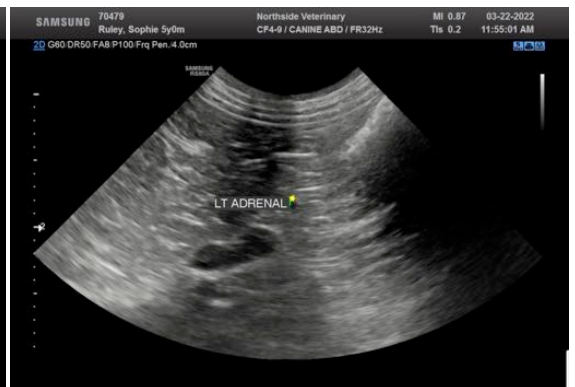
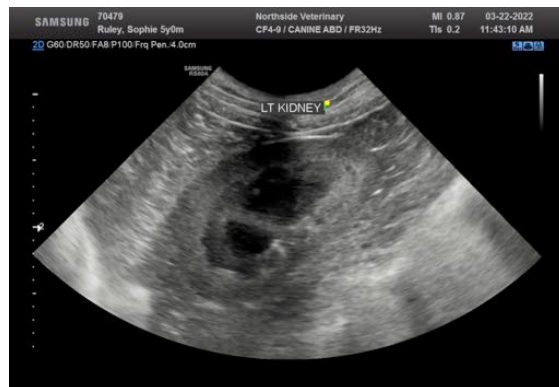
This patient likely has underlying food intolerance. Occult parasitism and Helicobacter are all potentials.

WEIGHT

9 lbs

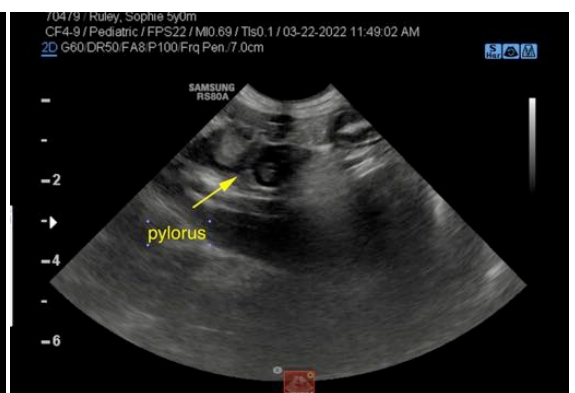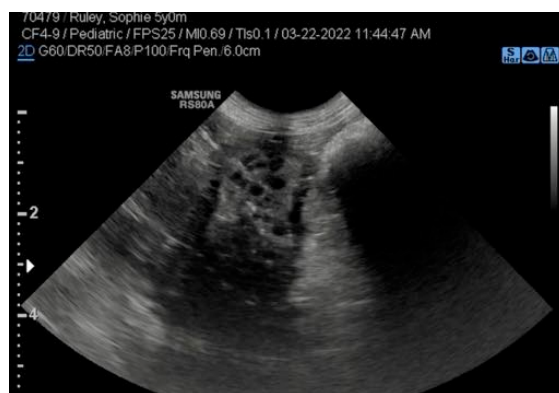INTERPRETED BY

Eric Lindquist, DMV
DABVP, Cert. IVUSS



IMAGING PERFORMED BY

Dr. Griffin



HOSPITAL NAME

Northside VC

REFERRING VET

Dr. Griffin

INVOICE

97082

DATE

3/22/22



PATIENT

Sophie Ruley

SPECIES

Canine

BREED

Yorkie

SEX

Spayed Female

AGE

5 years

WEIGHT

9 lbs

INTERPRETED BY

Eric Lindquist, DMV
DABVP, Cert. IVUSS

**IMAGING
PERFORMED BY**

Dr. Griffin

HOSPITAL NAME

Northside VC

REFERRING VET

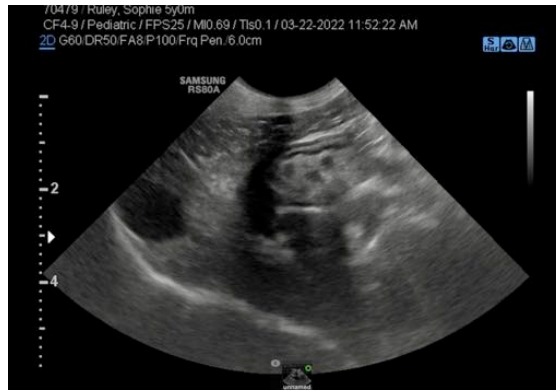Dr. Griffin

INVOICE

97082

DATE

3/22/22



The information and recommendations provided are based on the images presented by the referring veterinarian/sonographer. No evaluation can be communicated regarding pathology that was not visible in the image/video clips provided.

Thank you for this referral. If the clinical or image interpretation does not parallel your findings or if I can be of any further assistance please contact me.

Eric Lindquist, DMV, DABVP, Cert. IVUSS, CEO of SonoPath.com
info@SonoPath.com