



**PATIENT**

Emmy Delli Bovi

**PRESENTING CLINICAL SIGNS**

History: vomiting, anorexia lethargy

**SPECIES**

Canine

**ULTRASONOGRAPHIC EXAMINATION OF THE ABDOMEN**

**Urinary System**

**BREED**

Brussels Griffon

The **urinary bladder**, trigone, and pelvic urethra presented normal thicknesses and normal tone. The pelvic urethra was imaged 1.0 cm beyond the cystourethral junction. The ureters were not visible which is normal. No uroliths or sediment were visualized and anechoic urine was present. No evidence of inflammatory or neoplastic changes was noted. Ureteral papillae were normal.

**SEX**

Spayed Female

The **kidneys** presented a relatively uniform cortical hyperechogenicity when compared to the renal medulla, spleen and liver. No overt masses were noted. Corticomedullary definition was nebulous and the ratio favored the cortex slightly. The ureters were not visible and assumed to be normal. These changes are most consistent with chronic interstitial nephritis yet infiltrative disease could not be entirely ruled out without biopsy though neoplasia is not suspected. The left kidney revealed pyelectasia that measured 1.0 x 0.6 cm. The right kidney measured 4.5 cm with a cortical infarct.

**AGE**

7 years

**WEIGHT**

11.8 lbs

**Adrenal Glands**

Both **adrenal glands** were visualized and recognized as having normal shape, size, position and echogenicity for this breed. The phrenic vasculature, glandular echogenicity and detail were unremarkable. Capsule, cortex, and medullary definition were normal for this age patient. The right adrenal gland measured 1.64 x 0.56 cm at the caudal pole and 0.91 cm at the cranial pole. The left adrenal gland measured 1.68 x 0.51 cm at the caudal pole and 0.56 cm at the cranial pole.

**INTERPRETED BY**

Eric Lindquist, DMV  
DABVP, Cert. IVUSS

**IMAGING PERFORMED BY**

Jenn

**Spleen**

The **spleen** presented a smooth homogeneous parenchyma hyperechoic to liver and renal cortical parenchyma. The capsule was smooth without noticeable expansion or deviation from within the spleen or adjacent pathology. The splenic vasculature demonstrated normal volume without signs of congestion or thrombosis. No sonographic evidence of acute or chronic inflammatory, neoplastic, or infarctual changes was noted.

**HOSPITAL NAME**

Rockaway AH

**REFERRING VET**

Dr. Maniar

**Liver**

The **liver** images from right and left intercostal as well as subcostal views revealed subjectively normal liver size, contour, and structure. Some age-related parenchymal remodeling was noted but likely not clinically significant at this time. Vascular and biliary tracts were of normal volume and no evidence of congestion was noted. The gallbladder presented some dependent debris with essentially normal contour. The cystic and common bile ducts were normal. No overt evidence of active inflammatory, infiltrative or regenerative pathology was noted but should be paired with current or past LE elevations regarding any clinical significance to this presentation. The hepatic lymph nodes were unremarkable.

**INVOICE**

97060

**DATE**

3/22/22



**PATIENT**

Emmy Delli Bovi

**Gastrointestinal**

The **gastric** wall was particularly thickened. The small intestines and colon were unremarkable. The pancreatic pathology tethered the upper gastrointestinal tract.

**SPECIES**

Canine

**Pancreas**

The left limb of the **pancreas** was hypoechoic and irregular with ill-defined, hypoechoic parenchymal changes. The left limb measured 2.0 cm with regional inflammation. This is consistent with pancreatic necrosis, potential abscessation. This extends to the right limb and right base.

**BREED**

Brussels Griffon

**SEX**

Spayed Female

**ULTRASONOGRAPHIC FINDINGS**

Extensive pancreatitis and pancreatic necrosis with concurrent gastroenteritis. Potential for underlying neoplasia.

**AGE**

7 years

**INTERPRETATION OF THE FINDINGS & FURTHER RECOMMENDATIONS**

Aggressive treatment for pancreatitis with plasma expanders, plasma transfusion and pain management, broad spectrum antibiotics are all indicated. Recheck sonogram is recommended in 48-72 hours with 24 hour n.p.o. followed by slurry feeding. GI protectants are also indicated.

**WEIGHT**

11.8 lbs

**INTERPRETED BY**

Eric Lindquist, DMV  
DABVP, Cert. IVUSS

**IMAGING PERFORMED BY**

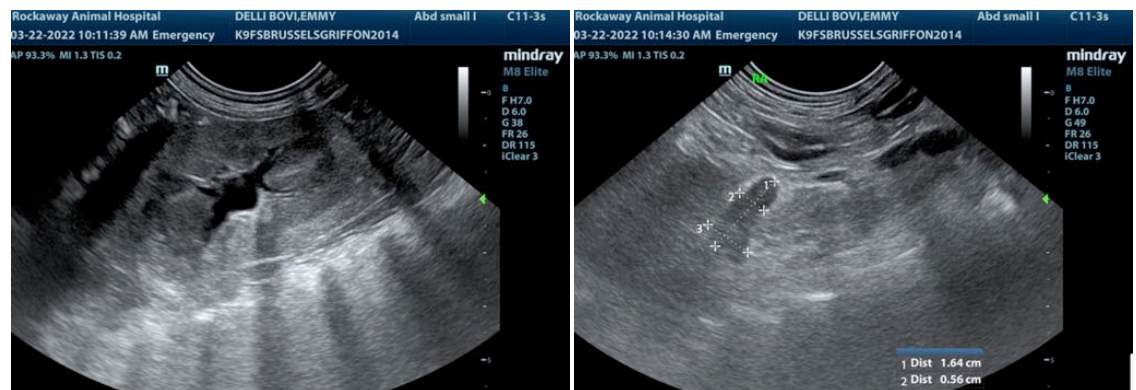
Jenn

**HOSPITAL NAME**

Rockaway AH

**REFERRING VET**

Dr. Maniar

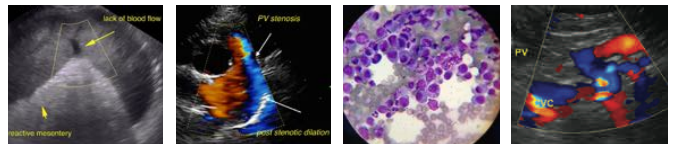


**INVOICE**

97060

**DATE**

3/22/22



**PATIENT**

Emmy Delli Bovi

**SPECIES**

Canine

**BREED**

Brussels Griffon

**SEX**

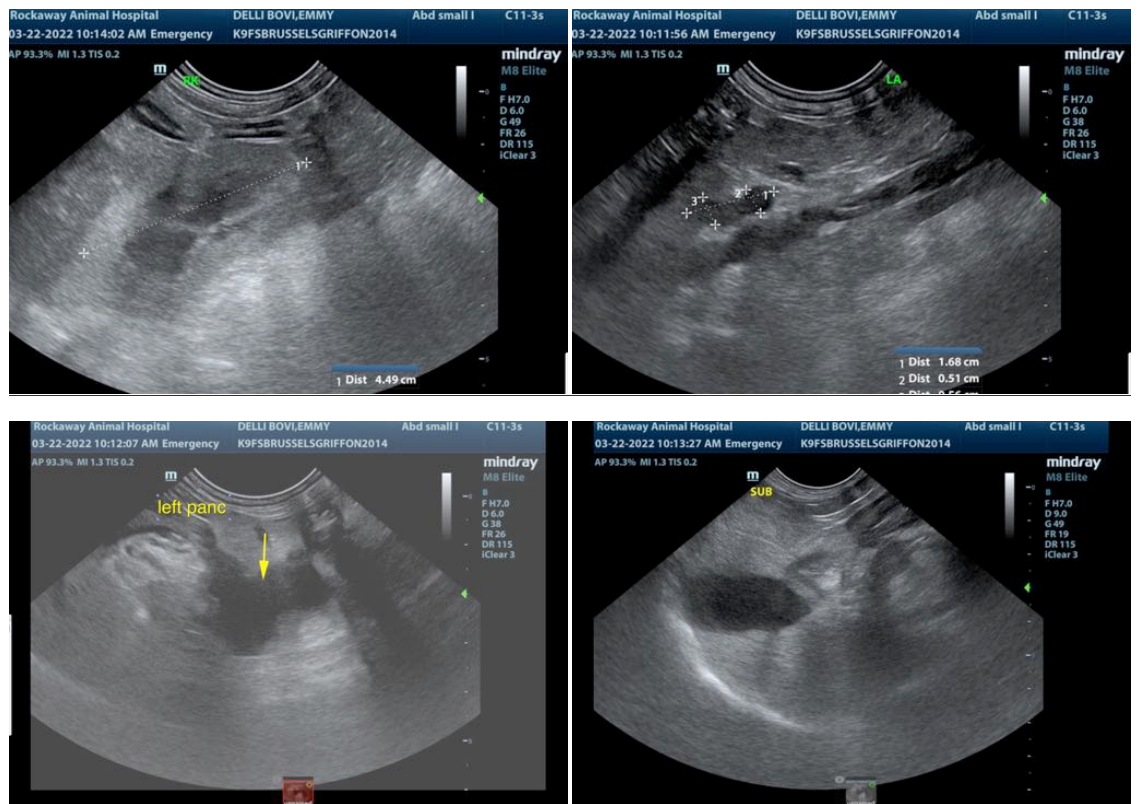
Spayed Female

**AGE**

7 years

**WEIGHT**

11.8 lbs



**INTERPRETED BY**

Eric Lindquist, DMV  
DABVP, Cert. IVUSS

The information and recommendations provided are based on the images presented by the referring veterinarian/sonographer. No evaluation can be communicated regarding pathology that was not visible in the image/video clips provided.

**IMAGING PERFORMED BY**

Jenn

Thank you for this referral. If the clinical or image interpretation does not parallel your findings or if I can be of any further assistance please contact me.

**HOSPITAL NAME**

Rockaway AH

**Eric Lindquist, DMV, DABVP, Cert. IVUSS, CEO of SonoPath.com**  
info@SonoPath.com

**REFERRING VET**

Dr. Maniar

**INVOICE**

97060

**DATE**

3/22/22