

**DATE PRESENTING CLINICAL SIGNS**

3/22/22

Saturday P do not want lunch P had a small amount of soft dog food and he did eat a little bit of that on Saturday. Sunday P did not want to eat any food P was very lethargic O had to pick patient up and carry P has no past medical history

PATIENT

Bella Hoskins

Current Medications: Potassium Chloride, Vitamin B, Gabapentin, Cerenia, Protonix, Buprenorphine.
Lab Results: See attached.

SPECIES

Feline

Date of Previous IntraPet Ultrasound: No previous.
Sedation: IV propofol.
Stat Report: Not requested.

BREED

DLH

ULTRASONOGRAPHIC EXAMINATION OF THE ABDOMEN**Urinary System**

The urinary bladder is moderately distended with anechoic urine. The Bladder wall, trigone, ureteral papillae and visible urethra (to a depth of 2cm) appear normal with no evidence of wall thickening, mucosal irregularities, masses or cystic calculi.

SEX

Spayed Female

The left kidney has a normal shape and size (4.01 cm). Overall echogenicity is slightly hyperechoic with poor corticomedullary distinction and a typical 1:3 cortex:medulla ratio. There is no evidence of perinephric inflammation or effusion. There is no evidence of pyelectasia, nephroliths, infarcts or hydroureter. Renal vasculature is normal.

AGE

2/20/13

WEIGHT

9.4 Pounds

The right kidney has a normal shape and size (3.81 cm.). Overall echogenicity is slightly hyperechoic with poor corticomedullary distinction and a typical 1:3 cortex:medulla ratio. There is no evidence of perinephric inflammation or effusion. There is no evidence of pyelectasia, nephroliths, infarcts or hydroureter. Renal vasculature is normal.

INTERPRETED BY

Kathleen Sennello DVM,
MS, Diplomate ACVIM
(Small Animal Internal
Medicine)

Adrenal Glands

The left adrenal gland is normal in size measuring 0.43 cm at the caudal pole. It is observed in its normal position cranial to the left renal artery. It is normal in appearance (uniformly hypoechoic) and shape with no evidence of a mass effect.

IMAGING PERFORMED BY

Rachel Brilhart RDMS

The right adrenal gland is normal in size measuring 0.45 cm at the caudal pole. It is observed in its normal position between the cranial aspect of the right kidney and the caudal vena cava. It is normal in appearance (uniformly hypoechoic) and shape with no evidence of a mass effect.

HOSPITAL NAME

Animal Emergency
Hospital

Spleen

The spleen is subjectively normal in size, echotexture is homogenous, and the splenic capsule is smooth with no irregularities. The blood flow through the hilus and splenic parenchyma appears normal. No focal parenchymal abnormalities are visualized.

REFERRING VET

Dr. Roper

Liver

The liver is large in size with smooth peripheral margins. The parenchyma is heterogenous in echotexture with subtle, indistinct focal mottling. There are numerous hyperechoic shadowing foci within the hepatic parenchyma, most consistent with intrahepatic biliary stones. Additionally, there are stones shadowing within the gallbladder and within a thickened, dilated, tortuous bile duct. The visible portions of the vasculature and biliary tract appear normal. No focal nodules or cystic lesions are observed.

INVOICE

36352

The gallbladder lumen is moderately distended. The wall of the gall bladder is mildly thickened, measuring 0.15 cm with a smooth mucosal surface. There is a moderate amount of shadowing dependent debris within

the gallbladder, most consistent with stones/sandy debris. The bile duct is dilated and tortuous with a thick wall, and intraluminal sandy debris and stones are evident.

Gastrointestinal

The stomach contains minimal luminal contents. It measures at a normal thickness of <0.36cm with some variability due to the presence of rugal folds. The distinction of the gastric wall layers is adequate and there is no impression of reduced peristaltic activity. No masses or focal lesions were observed.

The visualized areas of duodenum, jejunum and ileum have a relatively uniform diameter with minimal fluid distension. Wall thickness is normal. Bowel loops follow a curvilinear path with distinct wall layering maintaining the typical 1:3 muscularis:mucosa layer ratio. The duodenum measured as normal (between 0.13-0.38cm in wall thickness) and the jejunum measured as normal (between 0.15-0.36cm.) Visualized peristalsis appears appropriate. There were no focal lesions consistent with obstruction or a mass effect observed.

The ileocecal junction was visualized and exhibited normal intact wall layering and is subjectively of normal thickness. Sections of colon are visualized with formed fecal material and gas shadowing distally. There is no observed focal or generalized colon wall thickening or loss of layering.

Pancreas

The pancreas is large and hypoechoic to surrounding mesentery. There is no evidence of nodules or cystic lesions. There is evidence of regional mesenteric inflammation. Consistent with moderate pancreatitis.

Free Abdomen

Evaluation of the peritoneal cavity did not reveal any evidence of effusion, or subjective lymphadenomegaly. The Medial iliac nodes appear normal and there was no evidence of a caudal aortic thrombus at the bifurcation. The omentum is of normal uniform echogenicity.

PRIMARY FINDINGS

- Heterogeneous liver with intrahepatic biliary stones and stones visualized within the gallbladder and bile duct (which is thickened and dilated) – Findings are most consistent with inflammation/infection combined with partial obstruction.
- Large, hypoechoic pancreas with surrounding hyperechoic mesentery – The pancreatic changes are most consistent with moderate pancreatitis/pancreatic inflammation. Recommend fPLI testing and continued monitoring for improvement or possible development of a pancreatic abscess. Consider fine needle aspirate if not improving.

SECONDARY FINDINGS

- Decreased corticomedullary distinction in both kidneys – Mild loss of corticomedullary distinction in both kidneys could be consistent with chronic degenerative disease or interstitial nephrosis.

INTERPRETATION OF THE FINDINGS & FURTHER RECOMMENDATIONS

The liver is heterogeneous with intrahepatic stones in addition to a bile duct with mineralizations and a dilated tortuous/thickened bile duct with intraluminal stones. Findings are concerning for possible infection/inflammation and partial obstruction as well as moderate pancreatitis.

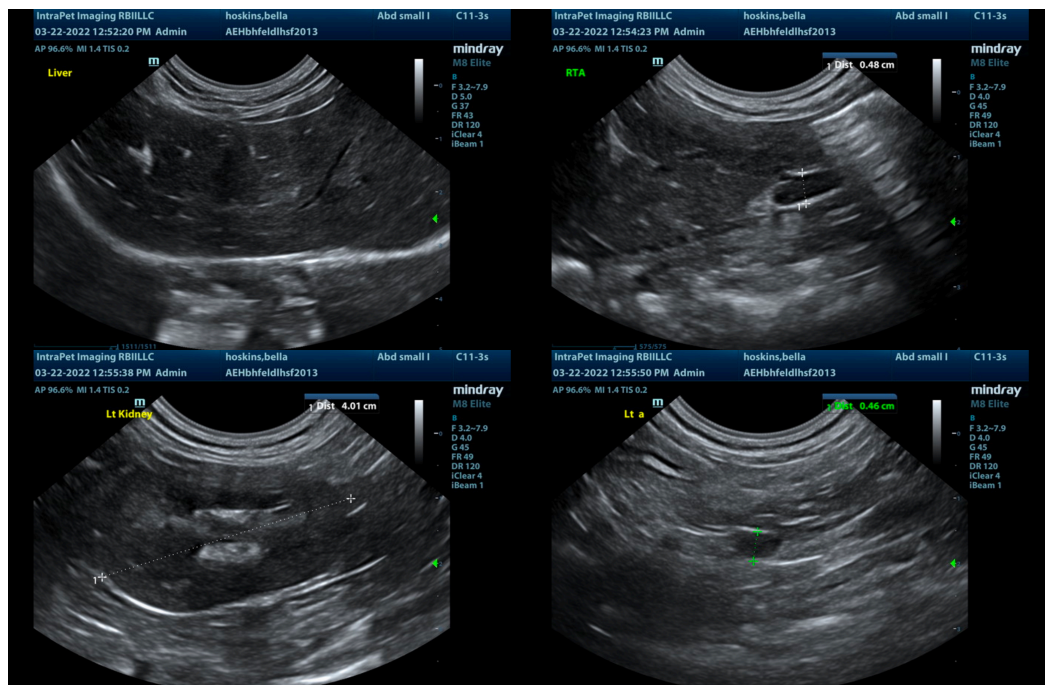
The combination of the hepatic changes, biliary disease, and pancreatic changes are concerning for possible Triaditis and primary biliary disease. Additionally, there is reduced distinction in the kidneys, which could be incidental, but should be monitored.

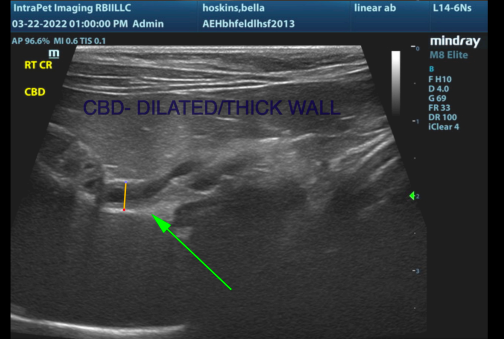
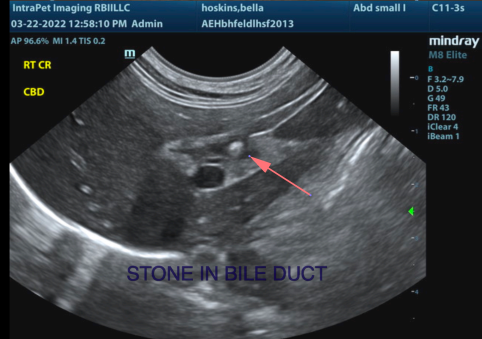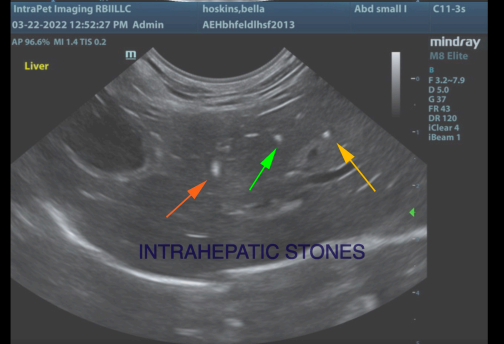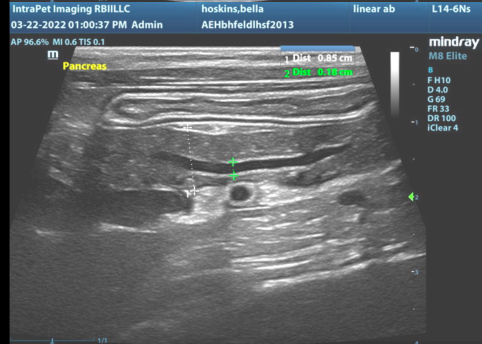
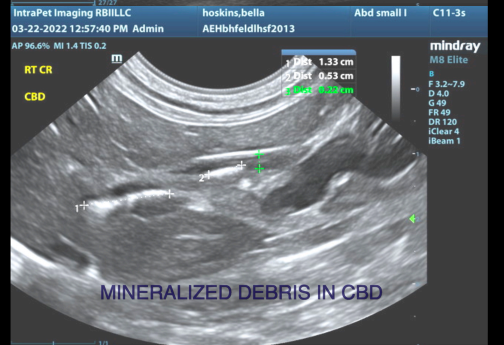
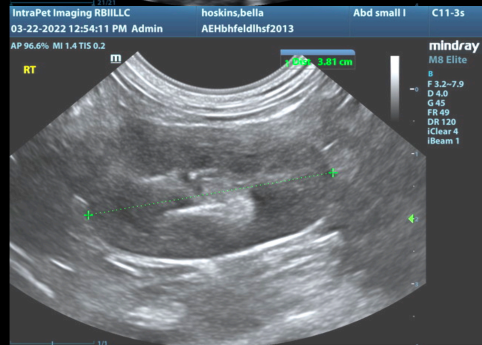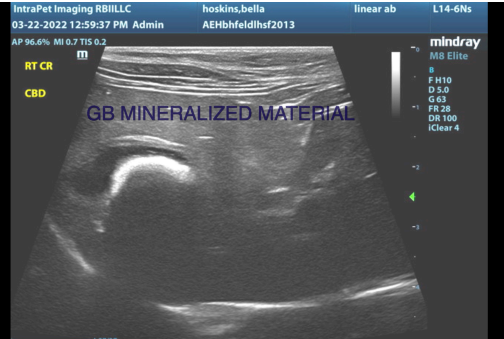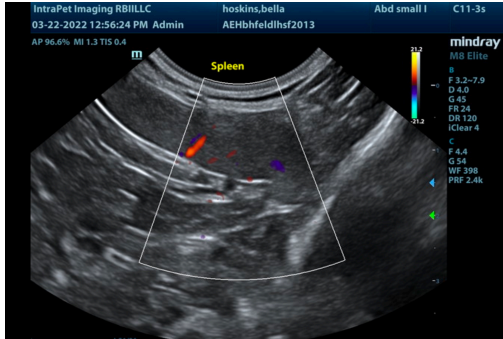
- Recommend a fine needle aspirate of the liver (provided coagulation parameters allow for this).
- Recommend aggressive medical management with antibiotics, supportive care if needed, treatment for pancreatitis, and starting Ursodiol.
- Recommend continued evaluation of the biliary tract with ultrasound (recheck in approximately 48 hours, sooner if concerned).
- If liver values are not improving, or there is progressive dilation of the biliary tract, then surgical intervention may need to be considered. If possible, it would be ideal to avoid surgical intervention, as there are so many stones present that surgical resolution would be difficult to achieve (it would likely be temporary).

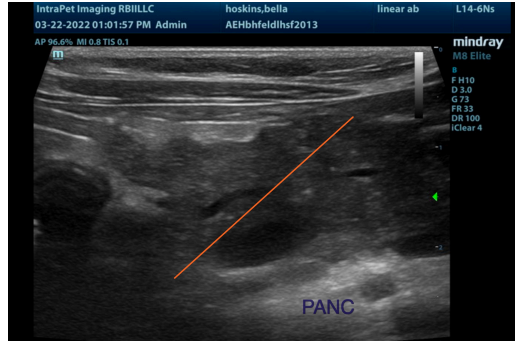
Recommend fine needle aspirate of the liver, as underlying infiltrative disease could be present, and this should be identified prior to therapy. If there is no response to antibiotics, Ursodiol, and treatment of pancreatitis, then you could consider an anti-inflammatory dose of steroids (0.5 mg/kg per day of Prednisolone) to try and reduce some of the inflammatory changes.

Consider three view thoracic radiographs to rule out concurrent thoracic disease/involvement.

Long-term prognosis is guarded due to the likely chronicity of this condition.







The information and recommendations provided are based on the images presented by the referring veterinarian/sonographer. No evaluation can be communicated regarding pathology that was not visible in the image/video clips provided.

Thank you for this referral. If the clinical or image interpretation does not parallel your findings or if I can be of any further assistance please contact me.

Kathleen Sennello DVM,MS, Diplomate ACVIM (Small animal Internal Medicine)
kathleen.sennello@sonopath.com