



PATIENT

Olive Rein

SPECIES

Feline

BREED

DSH

SEX

Spayed Female

AGE

4 Years 7 Months

WEIGHT

11.5 lbs

INTERPRETED BY

Eric Lindquist, DMV,
DABVP (CFM), Cert.
IVUSS

IMAGING PERFORMED BY

Dr. Kathleen Laux

HOSPITAL NAME

Rondout Valley
Veterinary Associates

REFERRING VET

Dr. Kathleen Laux

INVOICE

73903

DATE

3/21/26

PRESENTING CLINICAL SIGNS

Follow up gallbladder/liver US after being on baytril and clindamycin for 10 days.

Abnormal PE/Chem/CBC/UA Results: Repeat BW pending.

LIMITED ULTRASONOGRAPHIC EXAMINATION

The **liver** presented largely uniform parenchyma with slight increased portal markings.. The gallbladder was persistently edematous yet mildly improved from the prior sonogram. Slight biliary mineralization noted, non-obstructive, measuring approximately 4.0 mm. Slight free fluid noted adjacent to the gallbladder. No overt obstruction. The common bile duct was slightly thickened yet no overdistended. The duodenal papilla was unremarkable.

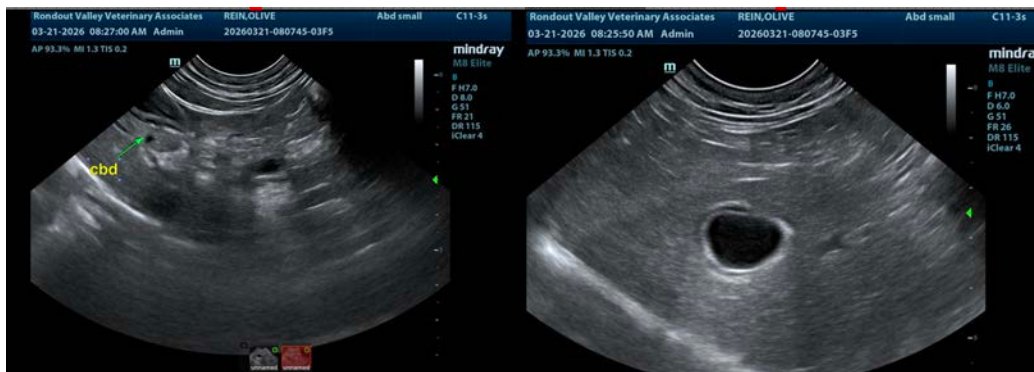
The upper **gastrointestinal tract** was unremarkable.

ULTRASONOGRAPHIC FINDINGS

- Persistent non-specific gallbladder edema, slightly improved.
- Slight free fluid adjacent to the gallbladder.
- Minor hepatic remodeling.

INTERPRETATION OF THE FINDINGS & FURTHER RECOMMENDATIONS

The liver appears fairly stable. However, I am concerned about the minor fluid adjacent to the gallbladder. The hyperechoic change in the mid liver appears to be consistent with mineralization. Management to be based on liver enzymes and any clinical signs. If the patient is stable, general recheck in 6-8 weeks indicated.





PATIENT

Olive Rein

SPECIES

Feline

BREED

DSH

SEX

Spayed Female

AGE

4 Years 7 Months

WEIGHT

11.5 lbs

INTERPRETED BY

Eric Lindquist, DMV,
DABVP (CFM), Cert.
IVUSS

IMAGING PERFORMED BY

Dr. Kathleen Laux

HOSPITAL NAME

Rondout Valley
Veterinary Associates

REFERRING VET

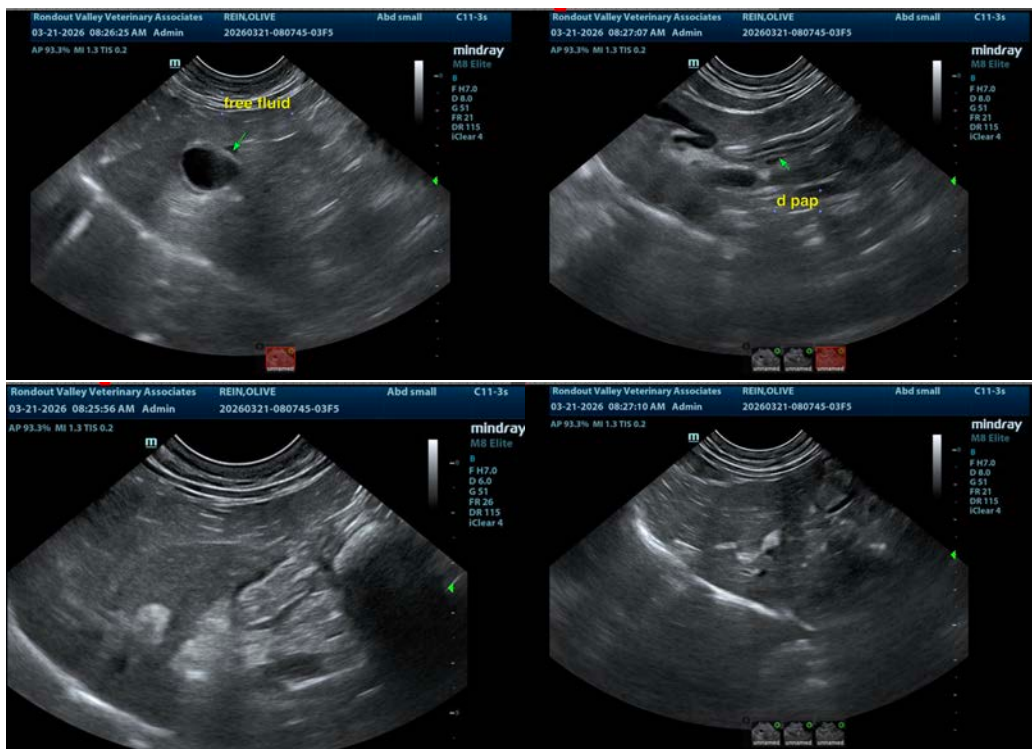
Dr. Kathleen Laux

INVOICE

73903

DATE

3/21/26



The information and recommendations provided are based on the images presented by the referring veterinarian/sonographer. No evaluation can be communicated regarding pathology that was not visible in the image/video clips provided.

Thank you for this referral. If the clinical or image interpretation does not parallel your findings or if I can be of any further assistance please contact me.

Eric Lindquist, DMV, DABVP(CFM), Cert. IVUSS,
CEO, Owner, Founder -- SonoPath.com
info@SonoPath.com