



PATIENT

Beatrice Briscotti

SPECIES

Feline

BREED

DSH

SEX

Spayed Female

AGE

12

WEIGHT

7.76

INTERPRETED BY

Eric Lindquist, DMV,
DABVP (Canine &
Feline), Cert. IVUSS

IMAGING PERFORMED BY

Dr. Melinda Persson

HOSPITAL NAME

At Home Veterinary

REFERRING VET

Dr. Melinda Persson

INVOICE

36331

DATE

3/21/26

PRESENTING CLINICAL SIGNS

- Increased respiratory effort noted Tuesday
- Mild HCM on echo in October 2025 - last check
- Undergoing treatment for retrobulbar lymphoma - chemo and radiation - chemo course almost finished
- Asthma
- Allergic skin disease
- Hyperthyroid - recently out of control but back in control for the last few weeks
- Prednisolone 2.5 mg once per day
- Methimazole 2.5 mg twice per day

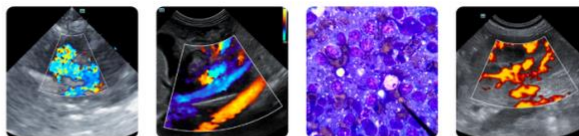
Abnormal PE/Chem/CBC/UA Results: Crackles left chest; clicking right chest; no wheezes RR 28 breaths per minutes - increased effort HR 148 On gabapentin 100 mg

ULTRASONOGRAPHIC EXAMINATION OF THE HEART

FELINE CARDIAC PARAMETERS	BODY WEIGHT	HR (BPM)	IVSd (cm)	LVIDd (cm)	LVWd (cm)	FS (%)	EF (%)
NORMAL PARAMETER	-----	150-240	0.3-0.6	1.0-2.1	0.25-0.6	35-67	80-100
PATIENT	7.76	180	0.58	1.1	0.52	50	--
FELINE CARDIAC PARAMETERS	LA/AO (M-mode)	LA/AO HEART BASE (Sisson)	LAD LA MAX 4 Chamber	LVOT VEL (m/s)	RVOT VEL (m/s)	IVRT (m/)	
NORMAL PARAMETER	<1.5	1.6	0.7-1.7	<1.6	<1.3	40-60	
PATIENT	1.0	1.1	1.37	--	1.40	NM	
Adapted from June Boon, Veterinary Echocardiography, 1998 Sisson D et al. JVIM 1991; 5: 232, Jacobs et al. Am J Vet Res 1985; 46:1705							

Cardiac Presentation

The cardiac presentation in this patient presented normal volumes and minor left ventricular hypertrophy. Contractility was adequate. No pericardial effusion was noted; however, pleural effusion was present. This is noncardiogenic in nature. The right atrium, right ventricle and tricuspid valve were unremarkable. Comet tail lung pattern was noted in the extracardiac space.



PATIENT

Beatrice Briscotti

SPECIES

Feline

BREED

DSH

SEX

Spayed Female

AGE

12

WEIGHT

7.76

INTERPRETED BY

Eric Lindquist, DMV,
DABVP (Canine &
Feline), Cert. IVUSS

IMAGING PERFORMED BY

Dr. Melinda Persson

HOSPITAL NAME

At Home Veterinary

REFERRING VET

Dr. Melinda Persson

INVOICE

36331

DATE

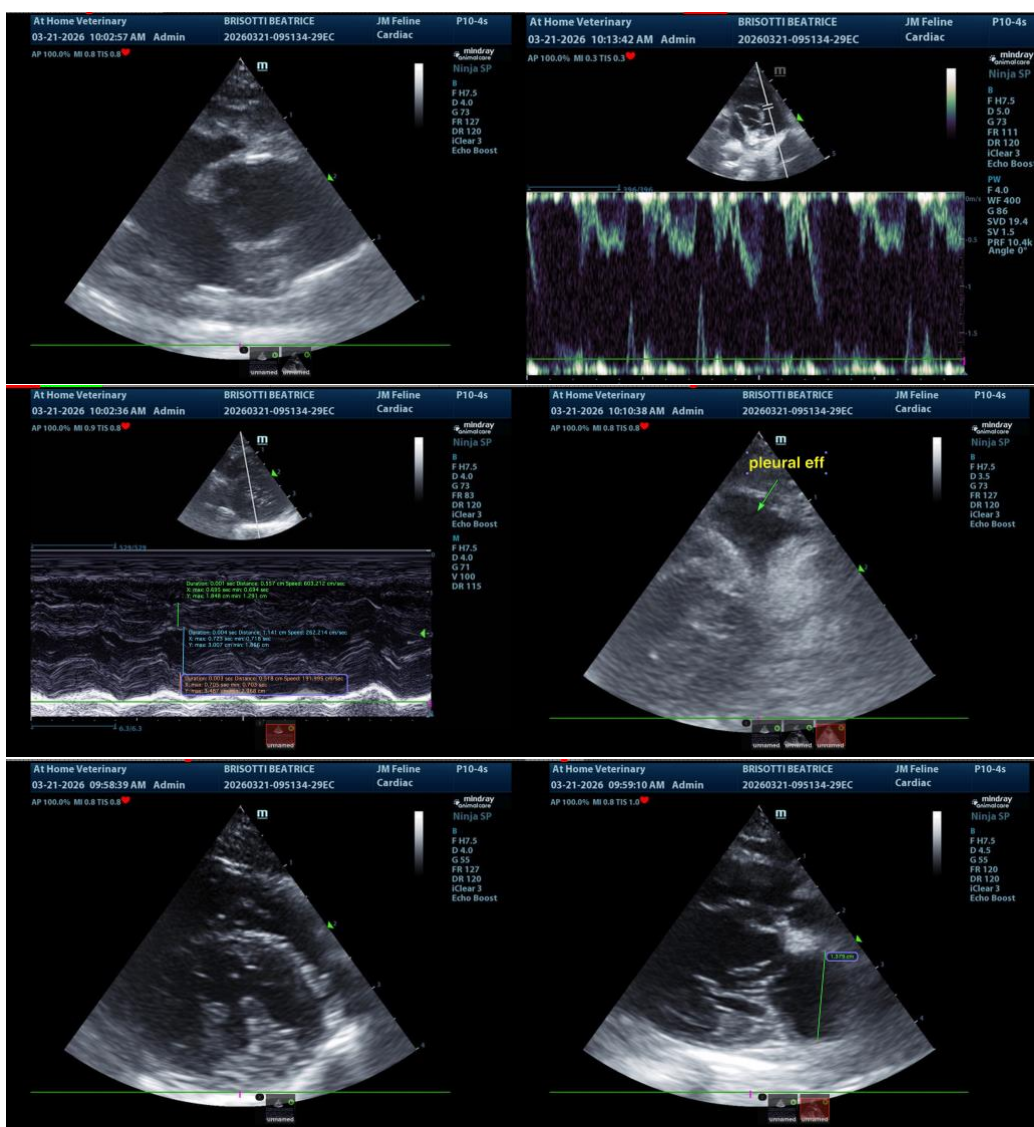
3/21/26

ULTRASONOGRAPHIC FINDINGS

- Noncardiogenic pleural effusion
- Pulmonary edema

INTERPRETATION OF THE FINDINGS & FURTHER RECOMMENDATIONS

Given the patient's history, I'm concerned for a neoplastic event in the thorax. Pneumonitis and thromboembolic disease are also possible. Pleurocentesis and cytospin are warranted to assess for exfoliating neoplasia. There is no cardiac component in this patient.





PATIENT

Beatrice Briscotti

SPECIES

Feline

BREED

DSH

SEX

Spayed Female

AGE

12

WEIGHT

7.76

INTERPRETED BY

Eric Lindquist, DMV,
DABVP (Canine &
Feline), Cert. IVUSS

IMAGING PERFORMED BY

Dr. Melinda Persson

HOSPITAL NAME

At Home Veterinary

REFERRING VET

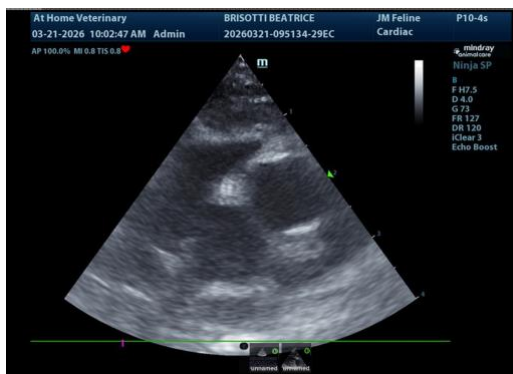
Dr. Melinda Persson

INVOICE

36331

DATE

3/21/26



The information and recommendations provided are based on the images presented by the referring veterinarian/sonographer. No evaluation can be communicated regarding pathology that was not visible in the image/video clips provided.

Thank you for this referral. If the clinical or image interpretation does not parallel your findings or if I can be of any further assistance please contact me.

Eric Lindquist, DMV, DABVP(CFM), Cert. IVUSS,
CEO, Owner, Founder -- SonoPath.com
info@SonoPath.com