



PATIENT

Princess Elkayam

SPECIES

Feline

BREED

Domestic Longhair

SEX

Spayed female

AGE

14 years

WEIGHT

14.5 lbs

INTERPRETED BY

Eric Lindquist, DMV
DABVP, Cert. IVUSS

IMAGING PERFORMED BY

Mayra Sanchez

HOSPITAL NAME

Sunset AH

REFERRING VET

Dr. Polit

INVOICE

43426

DATE

3/21/23

PRESENTING CLINICAL SIGNS

History: Hx of intermittent chronic vomiting
Abnormal PE/Chem/CBC/UA Results: PE: BCS 7/9; remainder WNL CBC: mild anemia HCT 28.97
Chem: ALT 267, AMY 1223 Radiographs (abdominal): mild constipation, kidneys appears small

ULTRASONOGRAPHIC EXAMINATION OF THE ABDOMEN

Urinary System

The **urinary bladder**, trigone, and pelvic urethra presented normal thicknesses and normal tone. The ureters were not visible which is normal. No uroliths or sediment were visualized and anechoic urine was present. No evidence of inflammatory or neoplastic changes was noted. Ureteral papillae were normal.

The **kidneys** presented a relatively uniform cortical hyperechogenicity when compared to the renal medulla, spleen and liver. No overt masses were noted. Corticomedullary definition was nebulous and the ratio favored the cortex slightly. The ureters were not visible and assumed to be normal. These changes are most consistent with chronic interstitial nephritis yet infiltrative disease could not be entirely ruled out without biopsy though neoplasia is not suspected. Corticomedullary mineralization was noted. The left kidney measured 3.39 cm with cortical infarcts. The right kidney measured 3.78 cm.

Adrenal Glands

Both **adrenal glands** were visualized and recognized as having normal shape, size, position and echogenicity for this breed. The phrenic vasculature, glandular echogenicity and detail were unremarkable. Capsule, cortex, and medullary definition were normal for this age patient.

Spleen

The **spleen** presented a smooth homogeneous parenchyma hyperechoic to liver and renal cortical parenchyma. The capsule was smooth without noticeable expansion or deviation from within the spleen or adjacent pathology. The splenic vasculature demonstrated normal volume without signs of congestion or thrombosis. No sonographic evidence of acute or chronic inflammatory, neoplastic, or infarctual changes was noted.

Liver

The **liver** images from right and left intercostal as well as subcostal views revealed subjectively normal liver size, contour, and structure. Some age-related parenchymal remodeling was noted but likely not clinically significant at this time. Vascular and biliary tracts were of normal volume and no evidence of congestion was noted. The gallbladder presented some dependent debris with essentially normal contour. The cystic and common bile ducts were normal. No overt evidence of active inflammatory, infiltrative or regenerative pathology was noted but should be paired with current or past LE elevations regarding any clinical significance to this presentation. The hepatic lymph nodes were unremarkable.



PATIENT

Princess Elkayam

SPECIES

Feline

BREED

Domestic Longhair

SEX

Spayed female

AGE

14 years

WEIGHT

14.5 lbs

INTERPRETED BY

Eric Lindquist, DMV
DABVP, Cert. IVUSS

IMAGING PERFORMED BY

Mayra Sanchez

HOSPITAL NAME

Sunset AH

REFERRING VET

Dr. Polit

INVOICE

43426

DATE

3/21/23

Gastrointestinal

Examination of the **gastrointestinal tract** revealed a stomach and intestine free of stasis, of normal wall thickness, acceptable curvilinear mural detail, and peristaltic activity. Small and large intestine demonstrated normal luminal chyme and stool consistency respectively. No obstructive or overt infiltrative disease was noted. No associated abnormal lymphatic activity was noted.

Pancreas

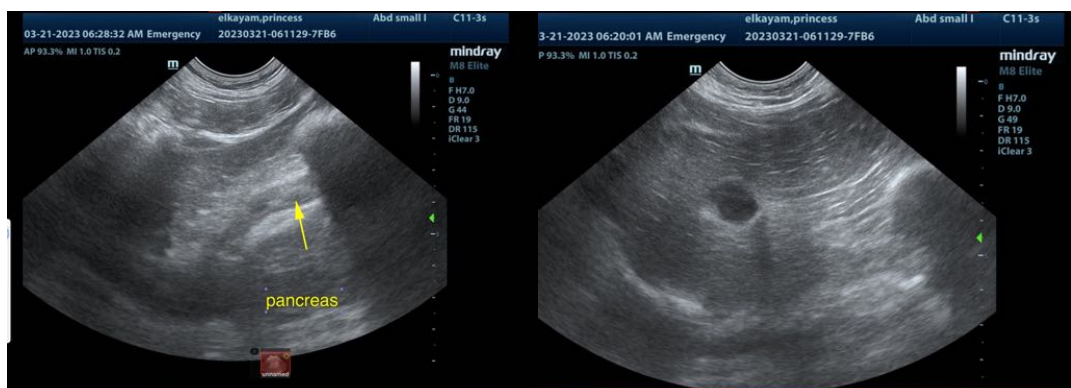
The base and limbs of the **pancreas** were observed to be largely isoechoic to surrounding omental fat. Some parenchymal remodeling, however, with mild deviation from curvilinear normalcy was observed. Pancreatic duct and capsular irregularities were present consistent with age related changes. If pain upon imaging (+ Murphy sign) was present or if the patient is focally painful in subxiphoid palpation then low-grade smoldering chronic pancreatitis should be suspected.

ULTRASONOGRAPHIC FINDINGS

Chronic degenerative renal changes. Subjectively 50-60% compromised.
Mild inflammatory hepatopathy liver pattern.

INTERPRETATION OF THE FINDINGS & FURTHER RECOMMENDATIONS

Supportive care should prove effective in this patient. Geriatric management regarding diet and supportive care is indicated. Prognosis long term is guarded given the state of the kidneys. Renal values, inflammatory sediment and urine specific gravity should be monitored carefully in this patient.





PATIENT

Princess Elkayam

SPECIES

Feline

BREED

Domestic Longhair

SEX

Spayed female

AGE

14 years

WEIGHT

14.5 lbs

INTERPRETED BY

Eric Lindquist, DMV
DABVP, Cert. IVUSS

IMAGING PERFORMED BY

Mayra Sanchez

HOSPITAL NAME

Sunset AH

REFERRING VET

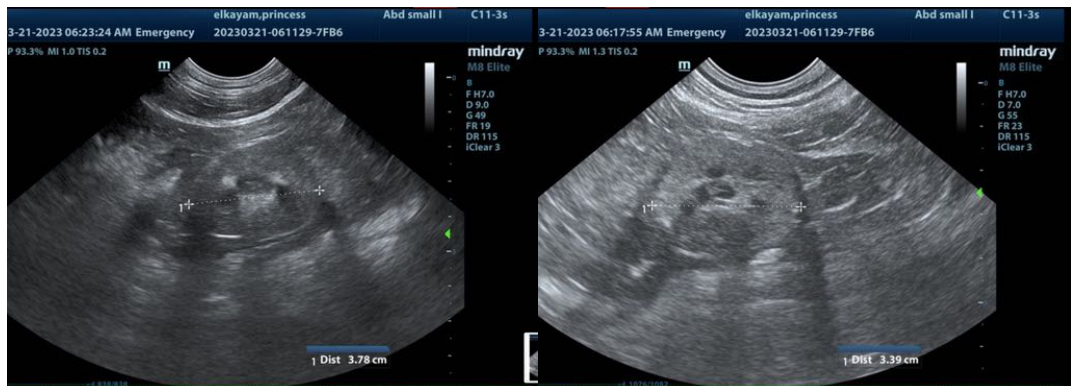
Dr. Polit

INVOICE

43426

DATE

3/21/23



The information and recommendations provided are based on the images presented by the referring veterinarian/sonographer. No evaluation can be communicated regarding pathology that was not visible in the image/video clips provided.

Thank you for this referral. If the clinical or image interpretation does not parallel your findings or if I can be of any further assistance please contact me.

Eric Lindquist, DMV, DABVP, Cert. IVUSS, CEO of SonoPath.com
info@SonoPath.com