



**PATIENT**

Bella Moss

**PRESENTING CLINICAL SIGNS**

History: V/D acute, liver failure per BW

**SPECIES**

Canine

**ULTRASONOGRAPHIC EXAMINATION OF THE ABDOMEN**

**Urinary System**

The **urinary bladder** presented multiple calculi, nonobstructive at the time of the sonogram.

**BREED**

Chihuahua

The **kidneys** revealed largely normal size and structure, corticomedullary definition and ratio (cortex 1/3 of medulla) were essentially maintained with some moderate age-related loss of curvilinear patterns regarding the capsule and C/M junction. The cortices presented largely uniform texture with some increased echogenicity expected for his age patient. Medullary structure differed distinctly from that of the cortex. Slight mineralization was noted in both kidneys. Slight pyelectasia in the left kidney noted. The right kidney measured 4.4 cm. The left kidney measured 4.4 cm.

**SEX**

Spayed Female

**Adrenal Glands**

**AGE**

12 Years

Both **adrenal glands** were visualized and recognized as having normal shape, size, position and echogenicity for this breed. The phrenic vasculature, glandular echogenicity and detail were unremarkable. Capsule, cortex, and medullary definition were normal for this age patient. The right adrenal gland measured 1.97cm x 0.91 cm at the cranial pole and 0.6 cm at the caudal pole. The left adrenal gland measured 1.26 cm x 0.48 cm at the caudal pole and 0.44 cm at the cranial pole.

**WEIGHT**

7.6 Pounds

**Spleen**

**INTERPRETED BY**

Eric Lindquist, DMV  
DABVP, Cert. IVUSS

The **spleen** revealed an infiltrative pattern with multifocal micronodular changes.

**Liver**

The **liver** revealed similar micronodular changes with a honeycomb type pattern and swollen irregular contour. Increased portal markings present. The gallbladder and common bile duct were unremarkable.

**IMAGING PERFORMED BY**

Jenn

**Gastrointestinal**

Examination of the **gastrointestinal tract** revealed a stomach and intestine free of stasis, of normal wall thickness, acceptable curvilinear mural detail, and peristaltic activity. Small and large intestine demonstrated normal luminal chyme and stool consistency respectively. No obstructive or overt infiltrative disease was noted. No associated abnormal lymphatic activity was noted.

**HOSPITAL NAME**

Rockaway AH

**Pancreas**

**REFERRING VET**

Dr. Maniar

The base and limbs of the **pancreas** were observed to be largely isoechoic to surrounding omental fat. Pancreatic duct and capsular contour were acceptably normal and parenchyma respected normal curvilinear patterns. No overt evidence of active inflammatory or neoplastic disease was noted.

**INVOICE**

14394

**ULTRASONOGRAPHIC FINDINGS**

- Infiltrative splenic and hepatic patterns. Round cell neoplasia suspected. Splenitis and cholangiohepatitis possible
- Bladder calculi

**DATE**

3/21/22

**INTERPRETATION OF THE FINDINGS & FURTHER RECOMMENDATIONS**



**PATIENT**

FNA of the spleen and liver recommended. Prognosis is guarded to poor.

Bella Moss

**SPECIES**

Canine

**BREED**

Chihuahua

**SEX**

Spayed Female

**AGE**

12 Years

**WEIGHT**

7.6 Pounds

**INTERPRETED BY**

Eric Lindquist, DMV  
DABVP, Cert. IVUSS

**IMAGING PERFORMED BY**

Jenn

**HOSPITAL NAME**

Rockaway AH

**REFERRING VET**

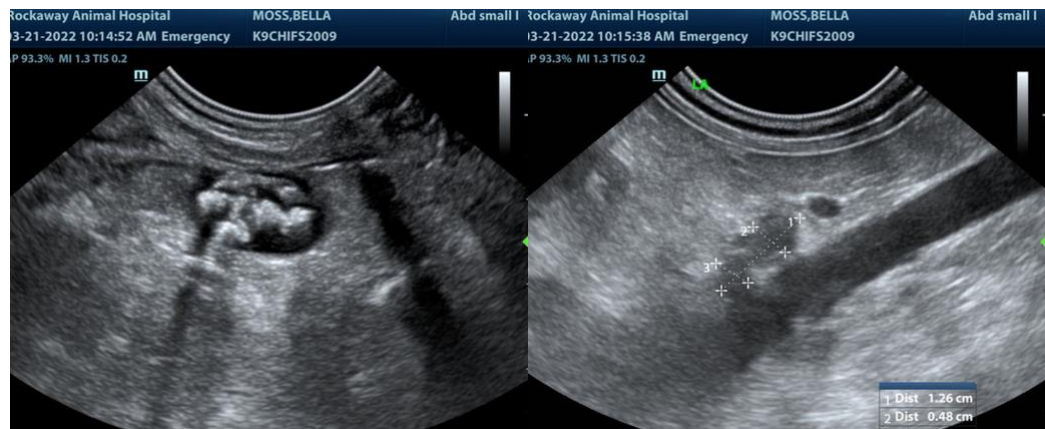
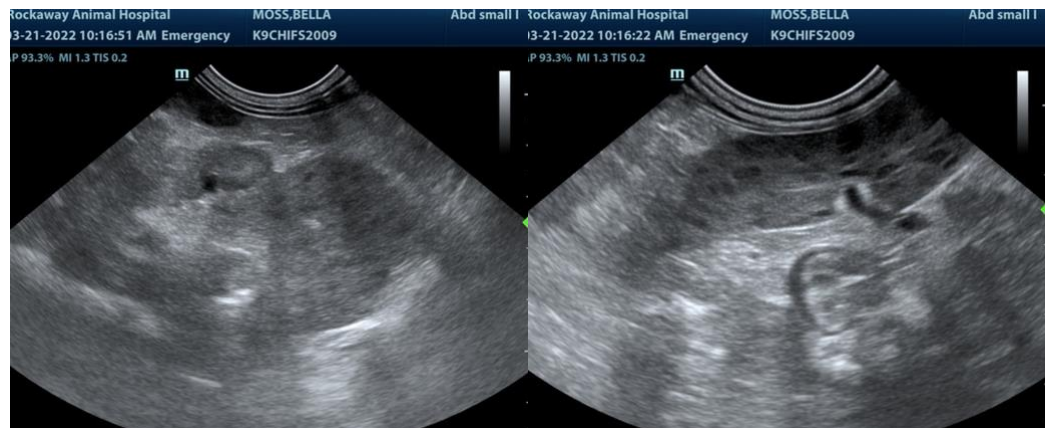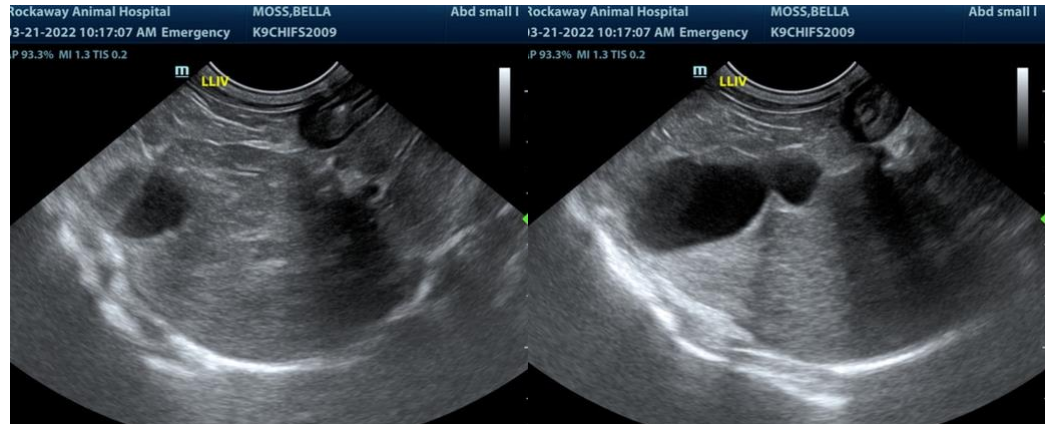
Dr. Maniar

**INVOICE**

14394

**DATE**

3/21/22





**PATIENT**

Bella Moss

**SPECIES**

Canine

**BREED**

Chihuahua

**SEX**

Spayed Female

**AGE**

12 Years

**WEIGHT**

7.6 Pounds

**INTERPRETED BY**

Eric Lindquist, DMV  
DABVP, Cert. IVUSS

**IMAGING PERFORMED BY**

Jenn

**HOSPITAL NAME**

Rockaway AH

**REFERRING VET**

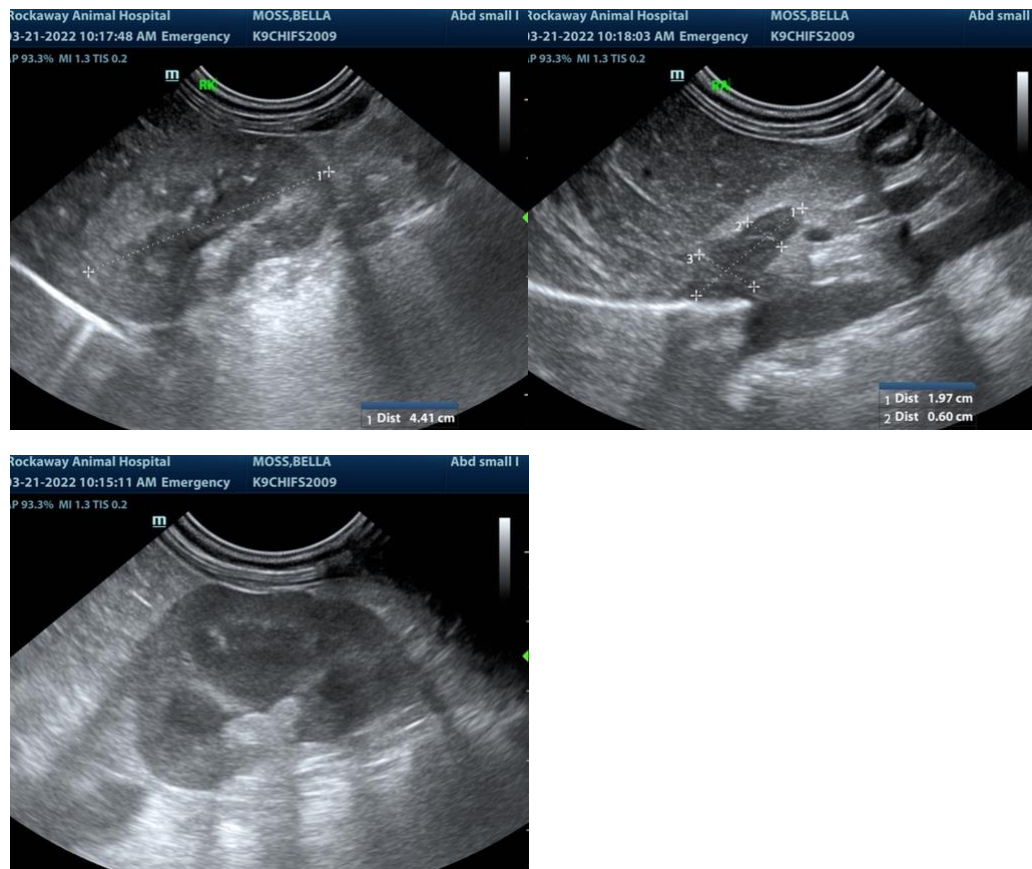
Dr. Maniar

**INVOICE**

14394

**DATE**

3/21/22



The information and recommendations provided are based on the images presented by the referring veterinarian. No evaluation can be communicated regarding pathology that was not visible in the image/video clips provided.

Thank you for this referral. If the clinical or image interpretation does not parallel your findings or if I can be of any further assistance please contact me.

**Eric Lindquist**, DMV, DABVP, Cert. IVUSS, CEO of SonoPath.com  
info@SonoPath.com