**DATE**

3/21/22

**PRESENTING CLINICAL SIGNS**

Mass left ventrolateral neck region, deep, 3cm in diameter, mobile. Has been present for >2 months and no change in size. Also, just finished radiation therapy of nerve sheath tumor at L7. Torn ACL right hind leg.

Current Medications: None listed.

**PATIENT**

Bear Shapiro

Date of Previous IntraPet Ultrasound: 12/29/21. See attached.

Sedation: Not required to complete full diagnostic ultrasound.

Stat Report: Not requested.

Imaging Performed By: Andi Parkinson, RDMS.

**SPECIES**

Canine

**BREED**

Pitbull

**SEX**

Neutered male

**AGE**

4/17/12

**WEIGHT**

75 lbs

**ULTRASONOGRAPHIC EXAMINATION OF THE THYROID**

Mixed echogenic parenchymal and highly vascular thyroid mass was noted in this patient and occupied the left thyroid lobe. The right thyroid lobe was uniform with a hypoechoic nodule at the mid caudal body. This is likely adenoma and measured 2.27 x 0.52 cm. A left thyroid mass measured 4.0 x 2.6 cm and appears encapsulated. Regional structures appear unaffected. Trachea, esophagus, salivary glands and lymph nodes all appear unaffected.

**ULTRASONOGRAPHIC FINDINGS**

Normal right thyroid lobe with nodules suspicious for parathyroid adenoma.

Left thyroid mass, strongly consistent with carcinoma, appears resectable.

**INTERPRETATION OF THE FINDINGS & FURTHER RECOMMENDATIONS**

Calcium levels should be monitored. Surgical consult is recommended. Non-functional thyroid carcinoma is suspected.

**INTERPRETED BY**

Eric Lindquist, DMV  
DABVP, Cert. IVUSS

**HOSPITAL NAME**

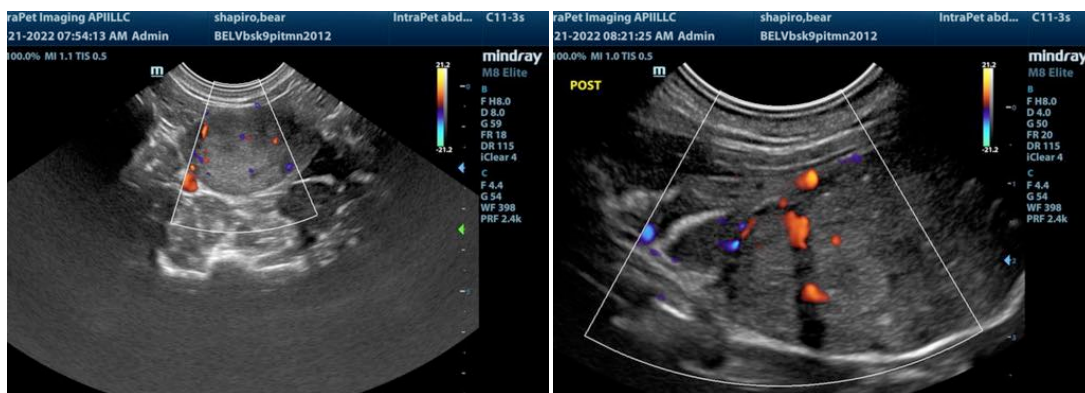
Belvedere VC

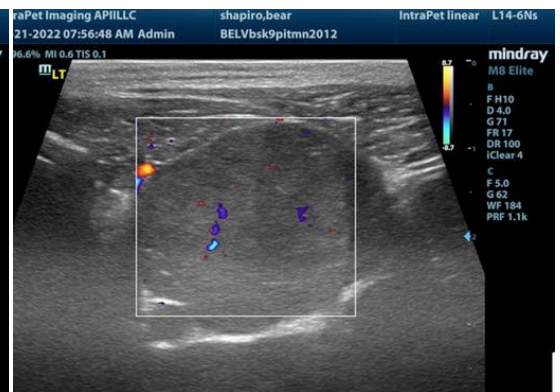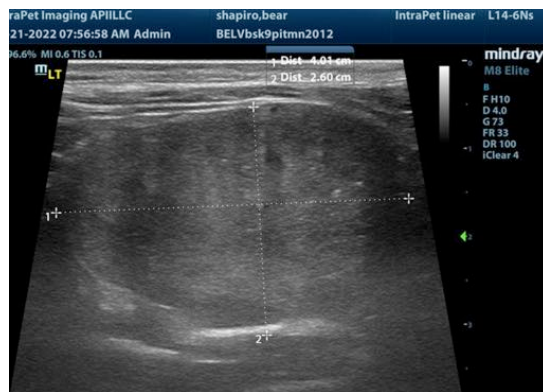
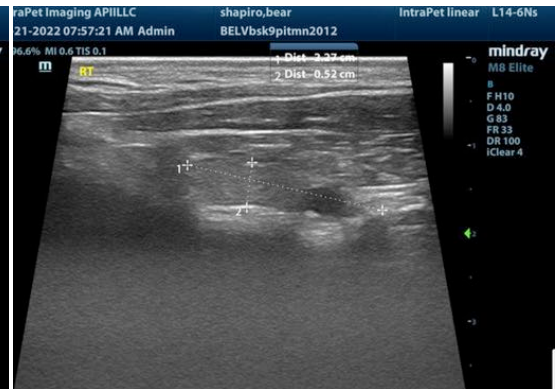
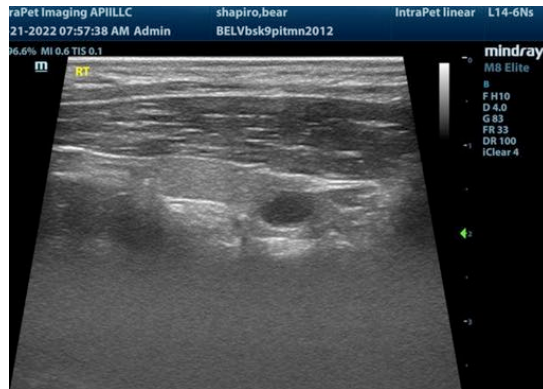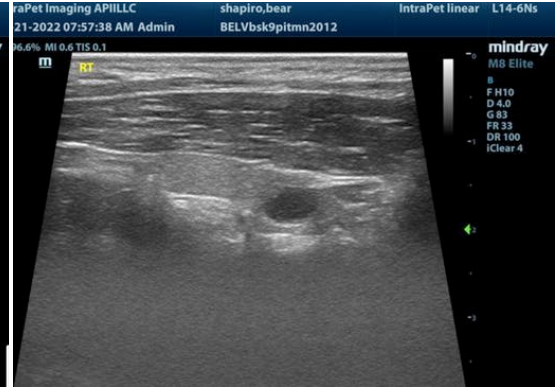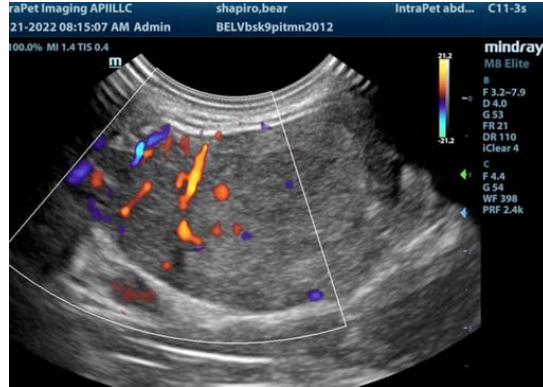
**REFERRING VET**

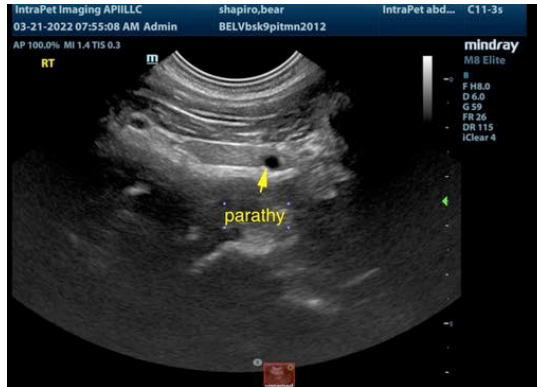Dr. Amstalden

**INVOICE**

97013







The information and recommendations provided are based on the images presented by the referring veterinarian. No evaluation can be communicated regarding pathology that was not visible in the image/video clips provided.

Thank you for this referral. If the clinical or image interpretation does not parallel your findings or if I can be of any further assistance please contact me.

**Eric Lindquist**, DMV, DABVP, Cert. IVUSS, CEO of SonoPath.com  
Eric.Lindquist@SonoPath.com