



## PATIENT

Chase Ballard

## SPECIES

Canine

## BREED

Mixed

## SEX

Neutered Male

## AGE

9 Years 9 Months

## WEIGHT

72 pounds

## INTERPRETED BY

Eric Lindquist, DMV,  
DABVP(CFM), Cert.  
IVUSS

## IMAGING PERFORMED BY

Dr. Kevin Moon DVM

## HOSPITAL NAME

Shiloh Veterinary  
Hospital

## REFERRING VET

Dr. Kevin Moon DVM

## INVOICE

14471

## DATE

03/20/26

## PRESENTING CLINICAL SIGNS

- P presented acutely painful in cranial abdomen with hunched posture. P had eaten 1hr prior with no concerns. Temperature normal
- Radiographs showed full cranial stomach, gaseous pylorus, Generalized loss of serosal detail.

Abnormal PE/Chem/CBC/UA Results: UA normal Chem normal including albumin and liver values CBC- WBC count 4.45 K/uL (5.0-16.7) Banded neutrophils suspected, confirmed on cPL negative Cytology of abdominal fluid: Abundant RBCs on a proteinaceous background with band neutrophils, and rare monocytes Bilirubin negative, Urobilinogen negative, koetones negative, Prot +++, nitrite negative, Glucose +, pH 6.5, occult blood neg, leuk negative

## ULTRASONOGRAPHIC EXAMINATION OF THE ABDOMEN

### Urinary System

The **urinary bladder**, trigone, and pelvic urethra to a depth of 1.0 cm presented normal thicknesses and normal tone. The ureters were not visible which is normal. No uroliths or sediment were visualized, and anechoic urine was present. No evidence of inflammatory or neoplastic changes were noted. Ureteral papillae were normal.

The **kidneys** revealed normal size and structure, corticomedullary definition and ratio for this age. The cortices presented largely uniform texture with normal echogenic relationship to liver and spleen. Medullary structure differed distinctly from the cortex and no evidence of pelvic dilation was present. The capsules were acceptably uniform without significant irregularities. The left kidney measured 6.9 cm in length. The right kidney measured 6.5 cm in length.

### Adrenal Glands

Both **adrenal glands** were visualized and recognized as having normal shape, size, position and echogenicity for this breed. The phrenic vasculature, glandular echogenicity and detail were unremarkable. Capsule, cortex, and medullary definition were normal for this age patient. The left adrenal gland measured 0.50 cm width. The right adrenal gland measured 0.90 cm width at the cranial pole and 0.85 cm width at the caudal pole.

### Spleen

The **spleen** presented slightly heterogenous and mildly irregular. No overt masses were present, however, cannot rule out a potential mass out of view and obscured by the reactive mesentery.

### Liver

The **liver** images submitted revealed subjectively normal liver size, contour, and structure. Parenchymal echogenicity was naturally coarse and hypoechoic to the spleen. Vascular and biliary tracts were of normal volume with no evidence of congestion. The gallbladder presented acceptably thin walls with primarily anechoic content. The cystic and common bile ducts were normal. No pathological hepatic lymphadenopathy was evident. No overt structural evidence of inflammatory, infiltrative or regenerative pathology was evident.

### Gastrointestinal



**PATIENT**

Chase Ballard

The **stomach** revealed some retention of ingesta and mild gastric wall thickening measuring up to 1.2 cm. No overt obstruction was present. The small intestine and colon were slightly thickened yet unremarkable otherwise.

**SPECIES**

Canine

**Pancreas**

The base and limbs of the **pancreas** were observed to be largely isoechoic to surrounding omental fat. Pancreatic duct and capsular contour were acceptably normal and parenchyma respected normal curvilinear patterns.

**BREED**

Mixed

**Free Abdomen**

Echogenic free fluid was noted in the abdomen. Hyperechoic fat was present associated with the spleen and liver. Hyperechoic reactive mesentery was coalesced in the region of the pancreas with concern for underlying neoplastic process.

**SEX**

Neutered Male

**AGE**

9 Years 9 Months

**ULTRASONOGRAPHIC FINDINGS**

- Undefined free fluid- potential neoplastic event or possible peritonitis.
- Potential penetrating foreign body given the gastric thickening and reactive mesentery around the upper GI tract.
- Heterogenous spleen.

**WEIGHT**

72 pounds

**INTERPRETATION OF THE FINDINGS & FURTHER RECOMMENDATIONS**

Ultrasound guided abdominocentesis and cytospin is warranted. Exploratory surgery may be the best option in this patient depending upon abdominocentesis findings. Full coagulation panel is warranted if any hemorrhage is found in the abdomen to assess for underlying coagulopathy.

**INTERPRETED BY**

Eric Lindquist, DMV,  
DABVP(CFM), Cert.  
IVUSS

**IMAGING PERFORMED BY**

Dr. Kevin Moon DVM

**HOSPITAL NAME**

Shiloh Veterinary  
Hospital

**REFERRING VET**

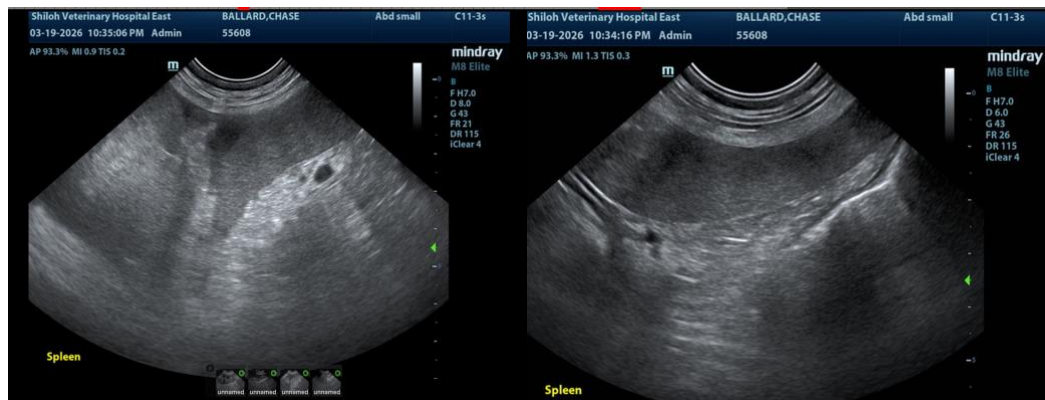Dr. Kevin Moon DVM

**INVOICE**

14471

**DATE**

03/20/26





## PATIENT

Chase Ballard

## SPECIES

Canine

## BREED

Mixed

## SEX

Neutered Male

## AGE

9 Years 9 Months

## WEIGHT

72 pounds

## INTERPRETED BY

Eric Lindquist, DMV,  
DABVP(CFM), Cert.  
IVUSS

## IMAGING PERFORMED BY

Dr. Kevin Moon DVM

## HOSPITAL NAME

Shiloh Veterinary  
Hospital

## REFERRING VET

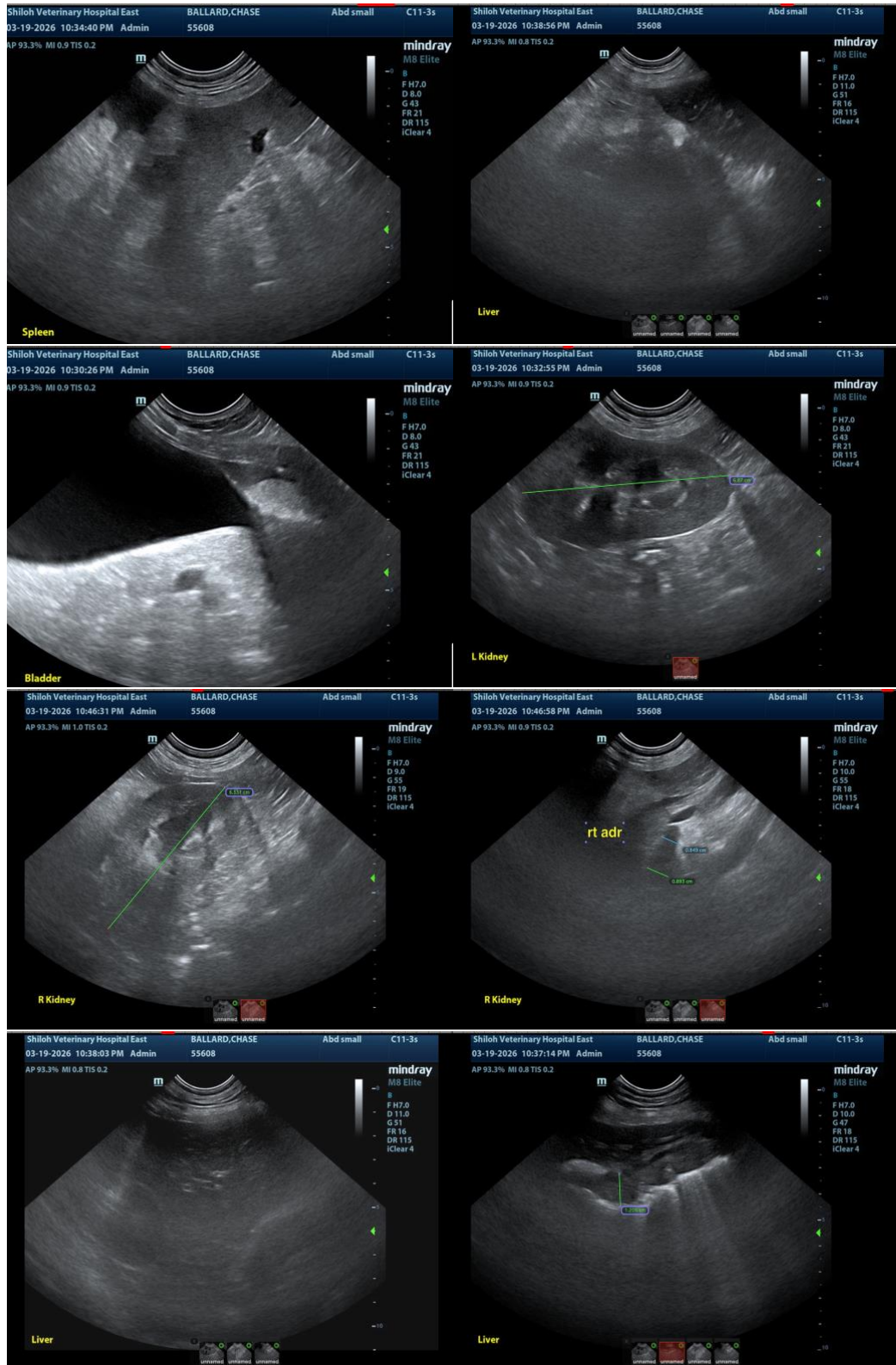
Dr. Kevin Moon DVM

## INVOICE

14471

## DATE

03/20/26





## PATIENT

Chase Ballard

## SPECIES

Canine

## BREED

Mixed

## SEX

Neutered Male

## AGE

9 Years 9 Months

## WEIGHT

72 pounds

## INTERPRETED BY

Eric Lindquist, DMV,  
DABVP(CFM), Cert.  
IVUSS

## IMAGING PERFORMED BY

Dr. Kevin Moon DVM

## HOSPITAL NAME

Shiloh Veterinary  
Hospital

## REFERRING VET

Dr. Kevin Moon DVM

## INVOICE

14471

## DATE

03/20/26

The information and recommendations provided are based on the images presented by the referring veterinarian/sonographer. No evaluation can be communicated regarding pathology that was not visible in the image/video clips provided.

Thank you for this referral. If the clinical or image interpretation does not parallel your findings or if I can be of any further assistance, please contact me.

**Eric Lindquist, DMV, DABVP(CFM), Cert. IVUSS,**

CEO, Owner, Founder -- SonoPath.com

[info@SonoPath.com](mailto:info@SonoPath.com)