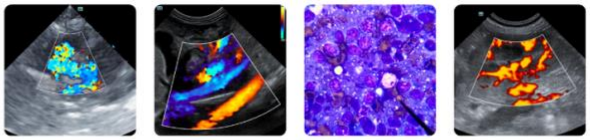

PATIENT
Boots Everett

SPECIES
Feline

BREED
DSH

SEX
Spayed Female

AGE
8.5

WEIGHT
13.09

INTERPRETED BY
Eric Lindquist, DMV, DABVP (CFM), Cert. IVUSS

IMAGING PERFORMED BY
Dr. Cassels-Conway

HOSPITAL NAME
Central Broward AH

REFERRING VET
Dr. Lara Oms

INVOICE
36329

DATE
3/20/26

PRESENTING CLINICAL SIGNS

Chronic intermittent vomiting, no weight loss. PE wnl.

Abnormal PE/Chem/CBC/UA Results: Cbc- Wnl Chem- Amylase 1258 H PSL- 52 H T4-2.5 NH Fecal NPS

ULTRASONOGRAPHIC EXAMINATION OF THE ABDOMEN

Urinary System

The **urinary bladder**, trigone, and pelvic urethra presented normal thicknesses and normal tone. The ureters were not visible which is normal. No uroliths or sediment were visualized and anechoic urine was present. No evidence of inflammatory or neoplastic changes were noted. Ureteral papillae were normal.

The **kidneys** revealed normal size and structure, corticomedullary definition and ratio for this age. The cortices presented largely uniform texture with normal echogenic relationship to liver and spleen. Medullary structure differed distinctly from the cortex, and no evidence of pelvic dilation was present. The capsules were acceptably uniform without significant irregularities. The right kidney measured 4.16 cm. The left kidney measured 3.85 cm.

Adrenal Glands

Both **adrenal glands** were visualized and recognized as having normal shape, size, position and echogenicity for this breed. The phrenic vasculature, glandular echogenicity and detail were unremarkable. Capsule, cortex, and medullary definition were normal for this age patient. The right adrenal gland measured 0.38 cm. The left adrenal gland measured 0.35 cm.

Spleen

The **spleen** was mildly enlarged (1.09 cm) with uniform, but subtly micronodular parenchyma, and undulating capsular contour. This is consistent with reactive spleen owing to immune stimulus or early infiltrative disease such as mast cell disease or lymphoma. 25-gauge FNA would be ideal if weight loss is an issue to differentiate early round cell neoplasia versus splenitis or reactive spleen all of which can present in this manner.

Liver

The **liver** images submitted revealed subjectively normal liver size, contour, and structure. Parenchymal echogenicity was naturally coarse and hypoechoic to the spleen. Vascular and biliary tracts were of normal volume with no evidence of congestion. The gallbladder presented acceptably thin walls with primarily anechoic content. The cystic and common bile ducts were normal. No pathological hepatic lymphadenopathy was evident. No overt structural evidence of inflammatory, infiltrative or regenerative pathology was evident.

Gastrointestinal

The **gastrointestinal tract** revealed minor variable thickening and echogenic submucosal changes most consistent with low grade end result of chronic GI disease such as IBD and may be related to malassimilation of nutrients if any weight loss is present. No obvious neoplastic patterns were noted and luminal content as unremarkable.

PATIENT

Boots Everett

SPECIES

Feline

BREED

DSH

SEX

Spayed Female

AGE

8.5

WEIGHT

13.09

INTERPRETED BY

Eric Lindquist, DMV, DABVP (CFM), Cert. IVUSS

IMAGING PERFORMED BY

Dr. Cassels-Conway

HOSPITAL NAME

Central Broward AH

REFERRING VET

Dr. Lara Oms

INVOICE

36329

DATE

3/20/26

Pancreas

The base and limbs of the **pancreas** were observed to be largely isoechoic to surrounding omental fat. Pancreatic duct and capsular contour were acceptably normal and parenchyma respected normal curvilinear patterns. No overt evidence of active inflammatory or neoplastic disease was noted.

Free Abdomen

The mesenteric **lymph nodes** measured up to 1.06 cm x 1.4 cm.

ULTRASONOGRAPHIC FINDINGS

- Splenomegaly
- Mesenteric lymphadenopathy
- Age-related GI changes

INTERPRETATION OF THE FINDINGS & FURTHER RECOMMENDATIONS

FNA of both the spleen and lymph nodes with cytology and culture indicate. Splenitis/lymphadenitis versus emerging round cell neoplasia. Prognosis is guarded depending upon cytology results.

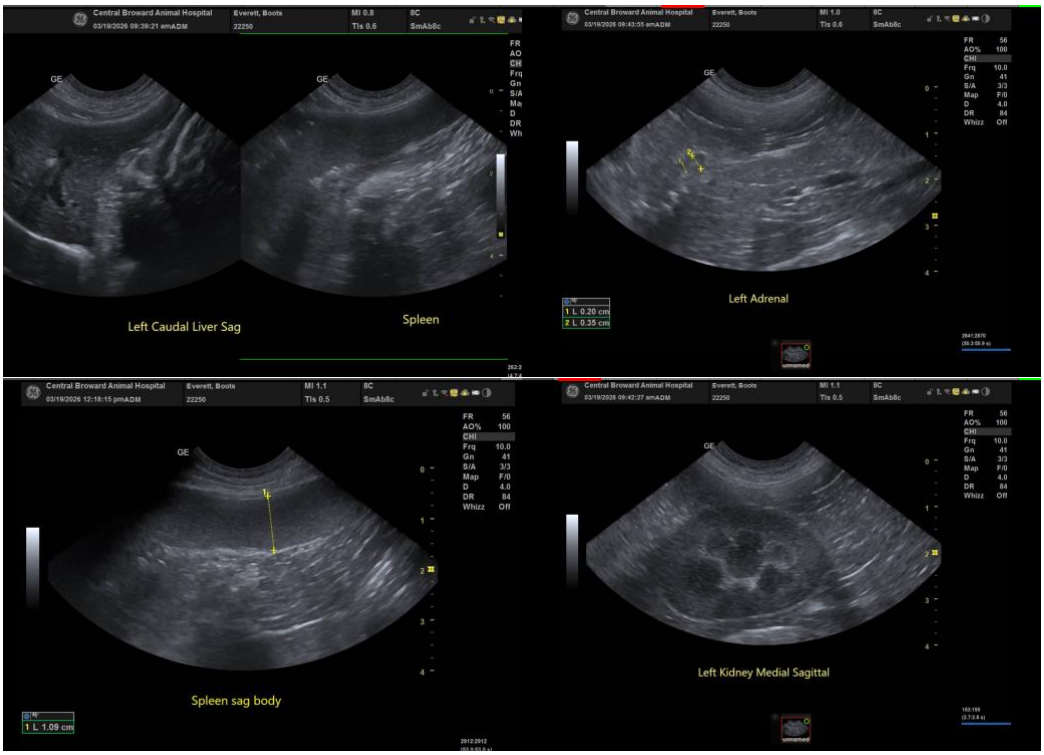

PATIENT

Boots Everett

SPECIES

Feline

BREED

DSH

SEX

Spayed Female

AGE

8.5

WEIGHT

13.09

INTERPRETED BY

Eric Lindquist, DMV, DABVP (CFM), Cert. IVUSS

IMAGING PERFORMED BY

Dr. Cassels-Conway

HOSPITAL NAME

Central Broward AH

REFERRING VET

Dr. Lara Oms

INVOICE

36329

DATE

3/20/26

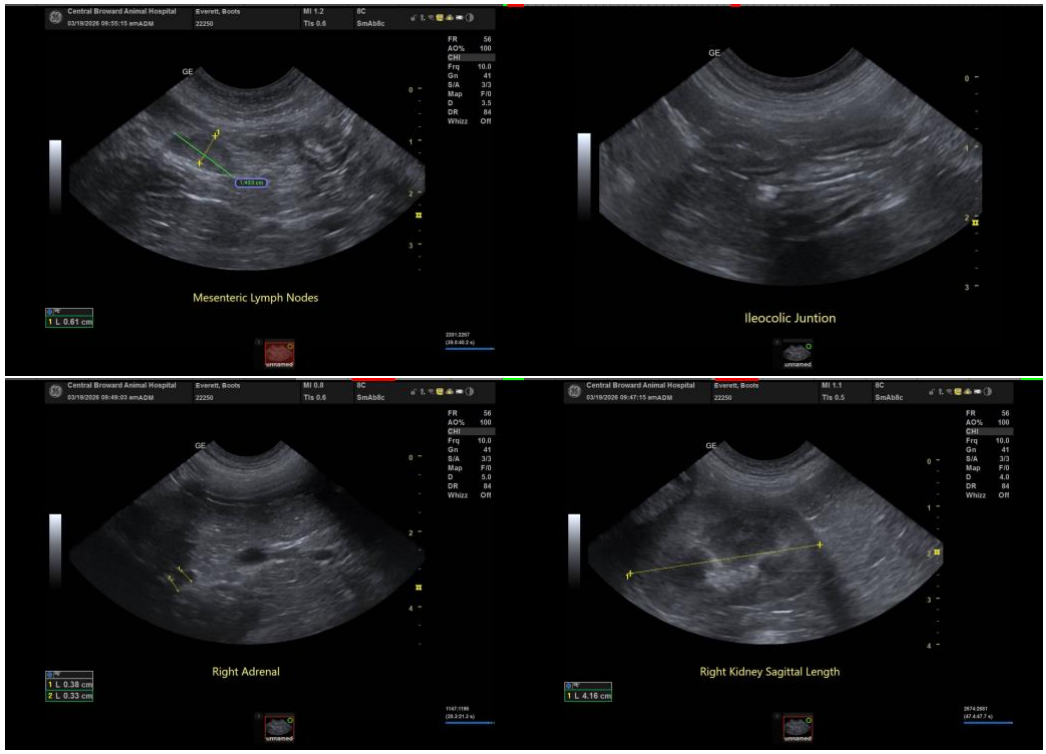

The information and recommendations provided are based on the images presented by the referring veterinarian/sonographer. No evaluation can be communicated regarding pathology that was not visible in the image/video clips provided.

Thank you for this referral. If the clinical or image interpretation does not parallel your findings or if I can be of any further assistance please contact me.

Eric Lindquist, DMV, DABVP(CFM), Cert. IVUSS,
CEO, Owner, Founder -- SonoPath.com
info@SonoPath.com