



## PATIENT

Duke Kingdom

## SPECIES

Canine

## BREED

Yorkshire Terrier

## SEX

Intact male

## AGE

12 years

## WEIGHT

4.72 kg

## INTERPRETED BY

Eric Lindquist, DMV  
DABVP, Cert. IVUSS

## IMAGING PERFORMED BY

Dr. Lemanski

## HOSPITAL NAME

Animal Emergency  
Hospital of Deland

## REFERRING VET

Dr. Lemanski

## INVOICE

43353

## DATE

3/20/23

## PRESENTING CLINICAL SIGNS

History: O presents pet today for straining to urinate with urgency for the last few days. O notes that the pet seems painful. Pet has hx of UTI dx on Feb 2. Pet is on a urinary diet.

Abnormal PE/Chem/CBC/UA Results: CBC: mild leukopenia COMP: mild elevated cholesterol, mild elevated ALP EPOC: nsf

## ULTRASONOGRAPHIC EXAMINATION OF THE ABDOMEN

### Urinary System

The cranial **urinary bladder** was largely unremarkable; however, the ventral caudal wall of the bladder appeared to have proliferative tissue deriving from the prostate.

The prostate in this patient was enlarged, irregular and mineralized measuring 2.8 cm with proliferative tissue that was superimposing or invading the cystourethral junction in this patient and trigone. This would not be typical behavior of BPH. This may still be benign prostatic hyperplasia with superimposition of proliferative tissue; however, I recommend traumatic catheterization or minimize the potential for trailing with ultrasound-guidance or ultrasound-guided FNA of the tissue. If carcinoma is present there is some risk of trailing of the tumor.

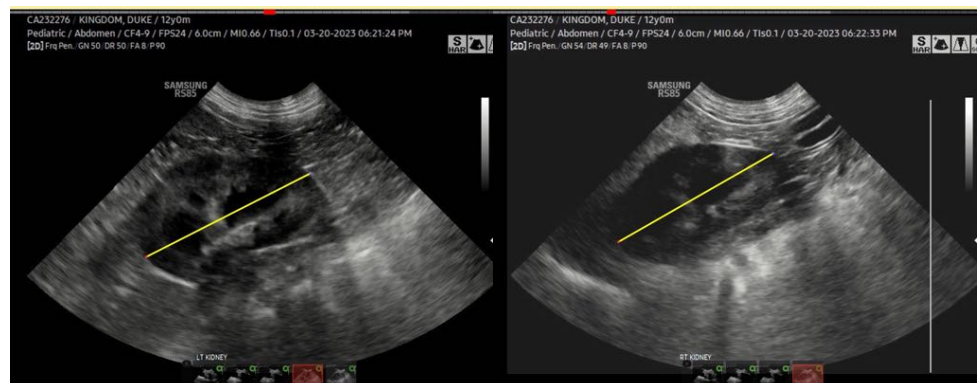
The **kidneys** are normal in size and contour measuring 4.0 cm each. The ureters were not dilated and there was no obstructive disease noted.

## ULTRASONOGRAPHIC FINDINGS

Proliferative prostate, pronounced BPH with cystourethral junction involvement or possible carcinoma.

## INTERPRETATION OF THE FINDINGS & FURTHER RECOMMENDATIONS

Sampling is essential in this patient with traumatic catheterization or ultrasound-guided FNA.





**PATIENT**

Duke Kingdom

**SPECIES**

Canine

**BREED**

Yorkshire Terrier

**SEX**

Intact male

**AGE**

12 years

**WEIGHT**

4.72 kg

**INTERPRETED BY**

Eric Lindquist, DMV  
DABVP, Cert. IVUSS

**IMAGING PERFORMED BY**

Dr. Lemanski

**HOSPITAL NAME**

Animal Emergency Hospital of Deland

**REFERRING VET**

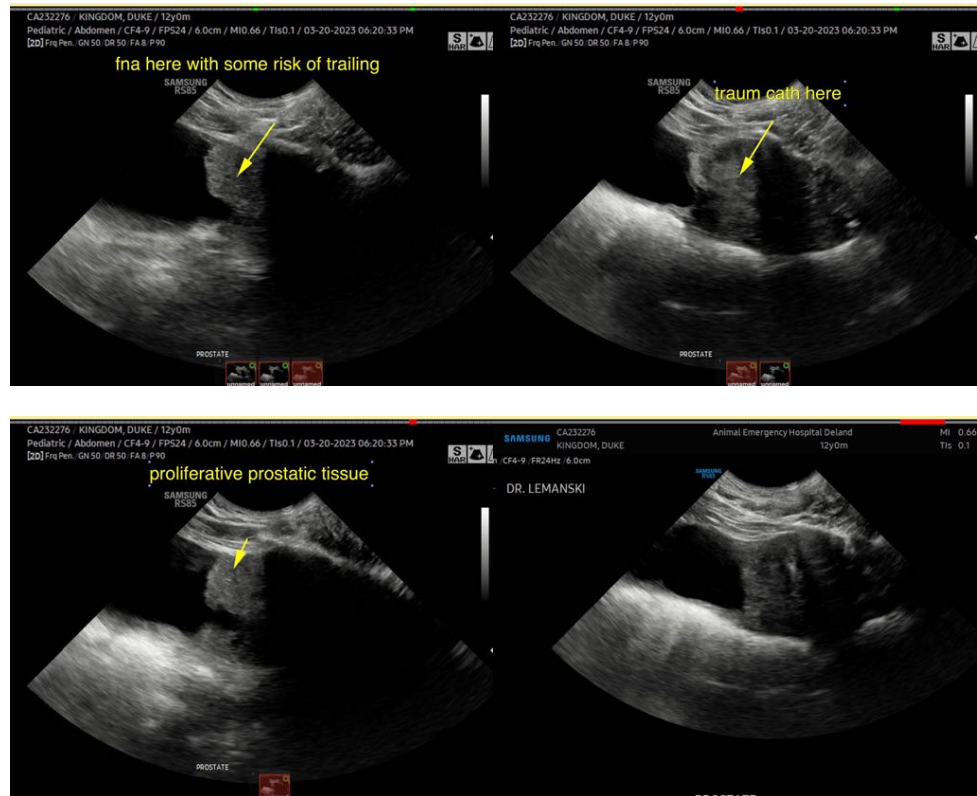
Dr. Lemanski

**INVOICE**

43353

**DATE**

3/20/23



The information and recommendations provided are based on the images presented by the referring veterinarian/sonographer. No evaluation can be communicated regarding pathology that was not visible in the image/video clips provided.

Thank you for this referral. If the clinical or image interpretation does not parallel your findings or if I can be of any further assistance please contact me.

**Eric Lindquist, DMV, DABVP, Cert. IVUSS, CEO of SonoPath.com**  
info@SonoPath.com