



PATIENT

Ianto Anderson

SPECIES

Feline

BREED

DSH

SEX

Neutered Male

AGE

9 Years

WEIGHT

7.2 kg

INTERPRETED BY

Eric Lindquist, DMV
DABVP, Cert. IVUSS

IMAGING PERFORMED BY

Dr. Callihan

HOSPITAL NAME

Animal Emergency
Care

REFERRING VET

Dr. Bailey

INVOICE

14389

DATE

3/20/22

PRESENTING CLINICAL SIGNS

History: Presented for inappetence and diarrhea, last solid stool 2 days ago; no known prior medical issues

Abnormal PE/Chem/CBC/UA Results: Mild non regenerative anemia 27%, mild lymphopenia, mild hypokalemia, USG 1.050 On PE, alert, apprehensive, obese, otherwise unremarkable

ULTRASONOGRAPHIC EXAMINATION OF THE ABDOMEN

Urinary System

The **urinary bladder**, trigone, and pelvic urethra presented normal thicknesses and normal tone. The ureters were not visible which is normal. No uroliths or sediment were visualized, and anechoic urine was present. No evidence of inflammatory or neoplastic changes were noted. Ureteral papillae were normal.

The **kidneys** revealed largely normal size and structure, corticomedullary definition and ratio (cortex 1/3 of medulla) were essentially maintained with some mild age-related loss of curvilinear patterns regarding the capsule and C/M junction. The cortices presented largely uniform texture with some increased echogenicity expected for his age patient. Medullary structure differed distinctly from that of the cortex and no evidence of pelvic dilation was present. The left kidney measured 4.86 cm. The right kidney measured 4.92 cm.

Adrenal Glands

The regions of the **adrenal glands** revealed no evident pathology.

Spleen

The **spleen** was slightly enlarged, measuring 1.22 cm.

Liver

The **liver** images submitted revealed subjectively normal liver size, contour, and structure. Parenchymal echogenicity was naturally coarse and hypoechoic to the spleen. Vascular and biliary tracts were of normal volume with no evidence of congestion. The gallbladder presented acceptably thin walls with primarily anechoic content. The cystic and common bile ducts were normal. No pathological hepatic lymphadenopathy was evident. No overt structural evidence of inflammatory, infiltrative or regenerative pathology was evident.

Gastrointestinal

Minor hyperperistalsis was noted in the **small intestine** with transiting fluid from the stomach through the small intestine, consistent with nonspecific gastroenteritis. Minor intestinal thickening noted without loss of detail. Soft stool was noted in the colon.

Pancreas

The base and limbs of the **pancreas** were observed to be largely isoechoic to surrounding omental fat. Pancreatic duct and capsular contour were acceptably normal and parenchyma respected normal curvilinear patterns. No overt evidence of active inflammatory or neoplastic disease was noted.

ULTRASONOGRAPHIC FINDINGS



PATIENT

Ianto Anderson

- Nonspecific gastroenteritis presentation, likely acute on chronic inflammatory bowel
- Age-related renal changes
- Enlarged spleen
- Unremarkable abdomen otherwise

SPECIES

Feline

INTERPRETATION OF THE FINDINGS & FURTHER RECOMMENDATIONS

Supportive care should prove effective.

BREED

DSH

SEX

Neutered Male

AGE

9 Years

WEIGHT

7.2 kg

INTERPRETED BY

Eric Lindquist, DMV
DABVP, Cert. IVUSS

IMAGING PERFORMED BY

Dr. Callihan

HOSPITAL NAME

Animal Emergency
Care

REFERRING VET

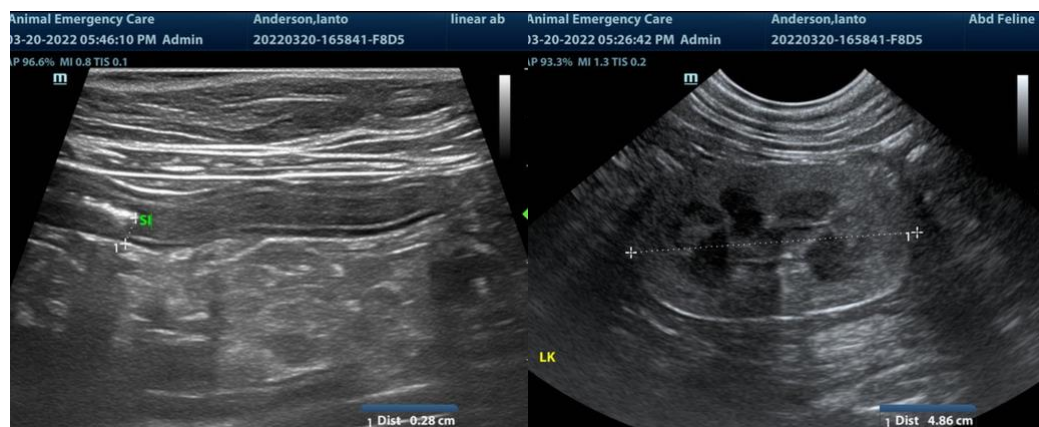
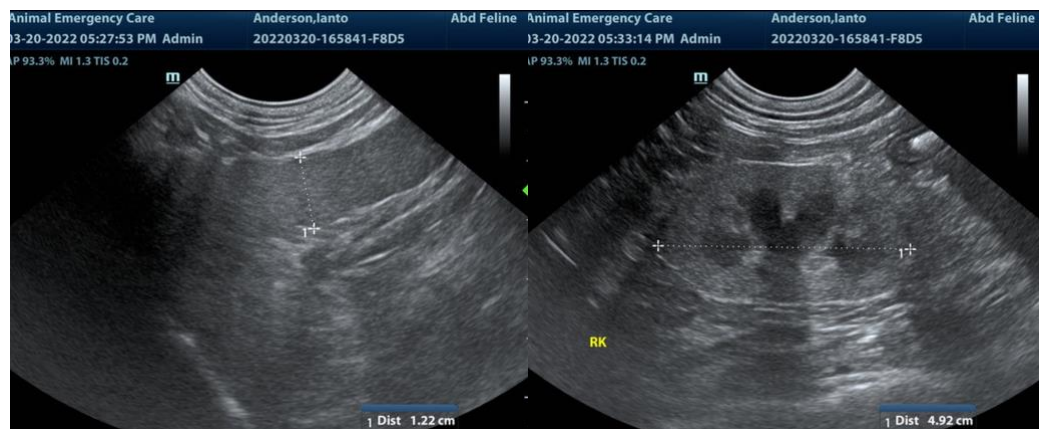
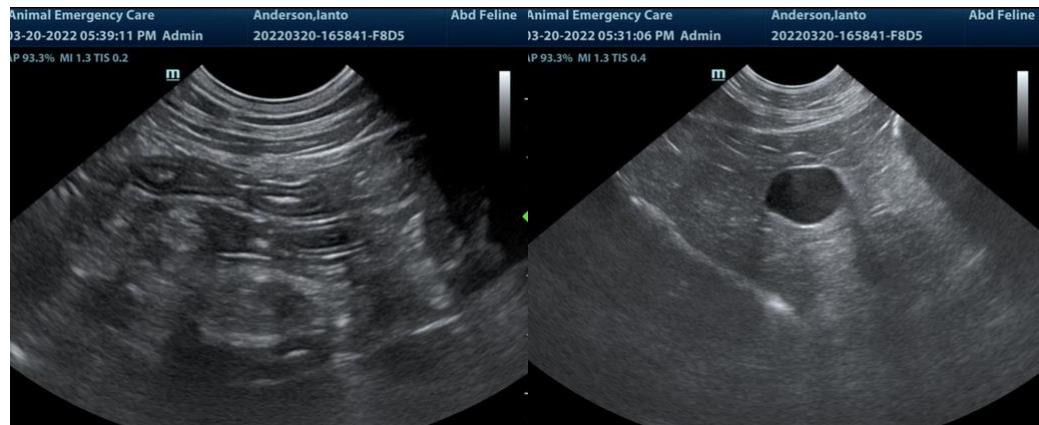
Dr. Bailey

INVOICE

14389

DATE

3/20/22



The information and recommendations provided are based on the images presented by the referring veterinarian. No evaluation can be communicated regarding pathology that was not



PATIENT

visible in the image/video clips provided.

Ianto Anderson

Thank you for this referral. If the clinical or image interpretation does not parallel your findings or if I can be of any further assistance please contact me.

SPECIES

Feline

Eric Lindquist, DMV, DABVP, Cert. IVUSS, CEO of SonoPath.com
info@SonoPath.com

BREED

DSH

SEX

Neutered Male

AGE

9 Years

WEIGHT

7.2 kg

INTERPRETED BY

Eric Lindquist, DMV
DABVP, Cert. IVUSS

**IMAGING
PERFORMED BY**

Dr. Callihan

HOSPITAL NAME

Animal Emergency
Care

REFERRING VET

Dr. Bailey

INVOICE

14389

DATE

3/20/22