



PATIENT

Marley Ghisalberi

SPECIES

Canine

BREED

St. Bernard

SEX

Intact Male

AGE

1 Year

WEIGHT

163 Pounds

INTERPRETED BY

Eric Lindquist, DMV

DABVP, Cert. IVUSS

IMAGING PERFORMED BY

Kelly Vazquez

HOSPITAL NAME

Westwood Regional

REFERRING VET

Dr. Silver

INVOICE

35802

DATE

3/2/22

PRESENTING CLINICAL SIGNS

Vomiting despite antiemetics and fluids. No known dietary indiscretion. Current meds: metronidazole and prochlorperazine.

Abnormal PE/Chem/CBC/UA Results: PSL 290.

ULTRASONOGRAPHIC EXAMINATION OF THE ABDOMEN

Urinary System

The **urinary bladder**, trigone, and pelvic urethra presented normal thicknesses and normal tone. The ureters were not visible which is normal. No uroliths or sediment were visualized and anechoic urine was present. No evidence of inflammatory or neoplastic changes were noted. Ureteral papillae were normal.

The **kidneys** revealed normal size and structure, corticomedullary definition and ratio for this age. The cortices presented largely uniform texture with normal echogenic relationship to liver and spleen. Medullary structure differed distinctly from the cortex and no evidence of pelvic dilation was present. The capsules were acceptably uniform without significant irregularities. The right kidney measured 8.14 cm. The left kidney measured 9.0 cm.

Adrenal Glands

Both **adrenal glands** were visualized and recognized as having normal shape, size, position and echogenicity for this breed. The phrenic vasculature, glandular echogenicity and detail were unremarkable. Capsule, cortex, and medullary definition were normal for this age patient. The right adrenal gland measured 3.03 cm x 0.93 cm at the cranial pole and 0.59 cm at the caudal pole. The left adrenal gland measured 2.42 cm x 0.50 cm at the caudal pole and 0.57 cm at the cranial pole.

Spleen

The **spleen** presented a smooth homogeneous parenchyma hyperechoic to liver and renal cortical parenchyma. The capsule was smooth without noticeable expansion or deviation from within the spleen or adjacent pathology. The splenic vasculature demonstrated normal volume without signs of congestion or thrombosis. No sonographic evidence of acute or chronic inflammatory, neoplastic, or infarctual changes were noted.

Liver

The **liver** images submitted revealed subjectively normal liver size, contour, and structure. Parenchymal echogenicity was naturally coarse and hypoechoic to the spleen. Vascular and biliary tracts were of normal volume with no evidence of congestion. The gallbladder presented acceptably thin walls with primarily anechoic content. The cystic and common bile ducts were normal. No pathological hepatic lymphadenopathy was evident. No overt structural evidence of inflammatory, infiltrative or regenerative pathology was evident.

Gastrointestinal

Examination of the **gastrointestinal tract** revealed an unremarkable stomach and small intestine regarding structure. There were minor areas of luminal fluid noted. There was no evidence of obstructive pattern. Curvilinear patterns were retained throughout the gastrointestinal tract. Areas of hyperperistalsis were noted. This is consistent with response to irritation. The colon was unremarkable. No evidence of foreign body.



PATIENT

Marley Ghisalberti

Pancreas

Minor nebulous changes noted in the region of the **pancreas** base. Some level of pancreatitis likely.

SPECIES

Canine

ULTRASONOGRAPHIC FINDINGS

- Gastroenteritis – no evidence of foreign body.
- Possible pancreatitis

BREED

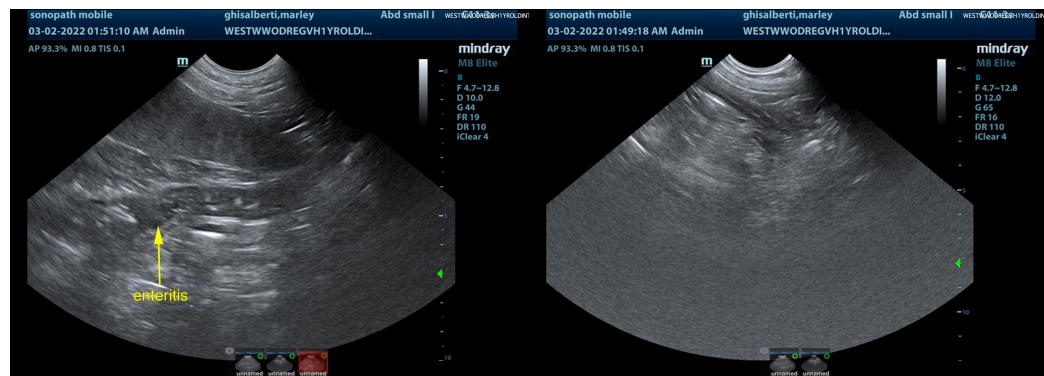
St. Bernard

INTERPRETATION OF THE FINDINGS & FURTHER RECOMMENDATIONS

24-hour NPO, treatment for enterotoxins, parasites, dietary indiscretion all indicated.

SEX

Intact Male

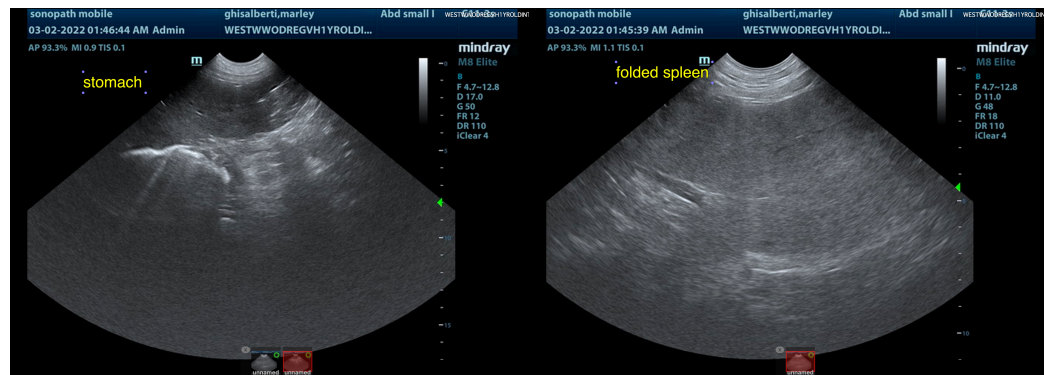


AGE

1 Year

WEIGHT

163 Pounds



INTERPRETED BY

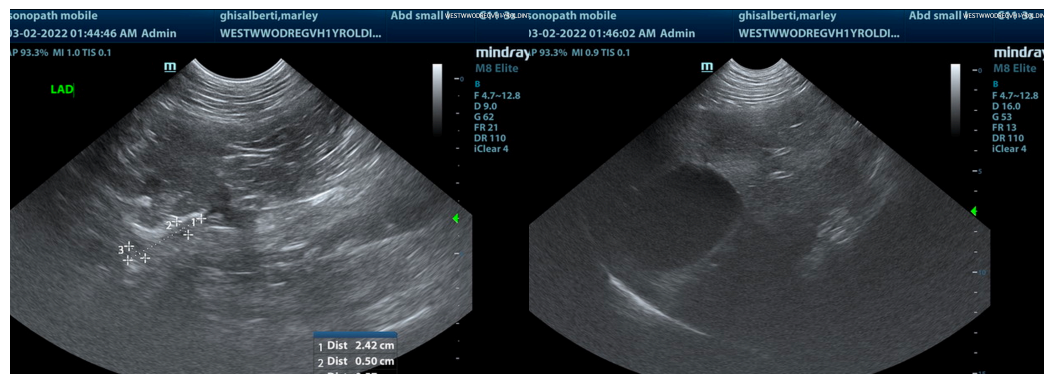
Eric Lindquist, DMV
DABVP, Cert. IVUSS

IMAGING PERFORMED BY

Kelly Vazquez

HOSPITAL NAME

Westwood Regional



REFERRING VET

Dr. Silver

INVOICE

35802

DATE

3/2/22



PATIENT

Marley Ghisalberi

SPECIES

Canine

BREED

St. Bernard

SEX

Intact Male

AGE

1 Year

WEIGHT

163 Pounds

INTERPRETED BY

Eric Lindquist, DMV

DABVP, Cert. IVUSS

IMAGING PERFORMED BY

Kelly Vazquez

HOSPITAL NAME

Westwood Regional

REFERRING VET

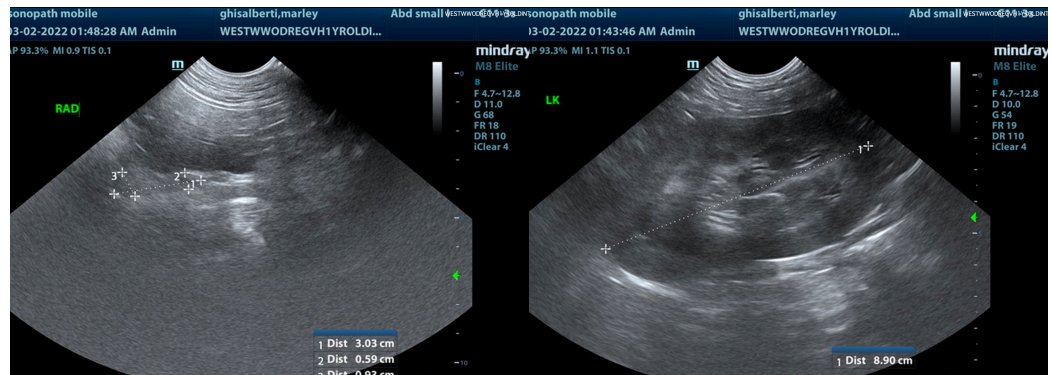
Dr. Silver

INVOICE

35802

DATE

3/2/22



The information and recommendations provided are based on the images presented by the referring veterinarian/sonographer. No evaluation can be communicated regarding pathology that was not visible in the image/video clips provided.

Thank you for this referral. If the clinical or image interpretation does not parallel your findings or if I can be of any further assistance please contact me.

Eric Lindquist, DMV, DABVP, Cert. IVUSS, CEO of SonoPath.com

info@SonoPath.com