



PATIENT

Maggie Rose Devries

SPECIES

Canine

BREED

Cocker Spaniel

SEX

Spayed Female

AGE

8 years

WEIGHT

21 lbs

INTERPRETED BY

Eric Lindquist, DMV
DABVP, Cert. IVUSS

IMAGING PERFORMED BY

Dr. Anderson

HOSPITAL NAME

Elizabeth AH

REFERRING VET

Dr. Anderson

PRESENTING CLINICAL SIGNS

No issues at home. Cardiac murmur (Trivial Mitral insufficiency) in 10/2016. Checking now as she needs a dental treatment under anesthesia.

Abnormal PE/Chem/CBC/UA Results: PE: Sclerosis of lenses normal for age. Stage II to III dental disease. Left heart base end systolic grade II/VI cardiac murmur. Anal gland fill. Labs drawn today.

ULTRASONOGRAPHIC EXAMINATION OF THE HEART

The echocardiogram in this patient demonstrated normal **left atrial** size based on 3 separate methods of LA evaluation. The cranial and caudal **mitral** valve leaflets presented normal linear structure, extension in systole, and union in diastole with normal kinesis. The **left ventricle** presented thicknesses with linear contour and was not dilated nor restricted. The **myocardium** presented normal echogenicity without subjective evidence of significant fibrotic or ischemic disease. **Contractility** of the ventricular walls was adequate and in normal range for this patient evidenced by the fractional shortening measurement and subjective evaluation of the different regions of the myocardium. The **left ventricular outflow** tract demonstrated normal laminar flow and subjective structural integrity. The **right atrium** and auricle revealed normal size, structure and content. No evidence of masses was noted. Trivial **tricuspid** insufficiency was noted. The **right ventricle** was of normal size (1/3 diameter of LV), chordae structure, myocardial echogenicity and thickness. **Pulmonary outflow** tract assessment revealed normal valve structure, laminar flow, and diameter (approx.1:1 pa/ao ratio). No visible **pericardial** or free pleura fluid was noted. The cranial **mediastinum** and **pericardial** and **extra-cardiac** regions were free of masses in the visible window.

CANINE CARDIAC PARAMETERS	MR VMAX (m/s)	TR VMAX (m/s)	LA/AO (Boon method)	LA/AO (Heart Base; Swe)	FS (%)	EF (%)	EPSS (cm)
NORMAL PARAMETER	4.5-5.5	<2.7	1.3	<1.6	28-40	40-100	<0.6
PATIENT		1.5	1.19		24	45	0.1
CANINE CARDIAC PARAMETERS	HR (BPM)	AV VMAX (m/s)	PV MAX (m/s)	BODY WEIGHT	LA (2D short axis Base view) (cm)	LVIDd (Avg; 2D and m-mode short axis) (cm)	LVIDs (Avg; 2D and m-mode short axis) (cm)
NORMAL PARAMETER	50-100	0.7-1.7	0.7-1.6				
PATIENT		1.99	1.06	21 lbs	2.18	2.27	

INVOICE

96543

DATE

3/2/22

ULTRASONOGRAPHIC FINDINGS

Essentially normal echocardiogram with trivial tricuspid insufficiency.

INTERPRETATION OF THE FINDINGS & FURTHER RECOMMENDATIONS

There is no contraindication to anesthetic procedure.



PATIENT

Maggie Rose Devries

SPECIES

Canine

BREED

Cocker Spaniel

SEX

Spayed Female

AGE

8 years

WEIGHT

21 lbs

INTERPRETED BY

Eric Lindquist, DMV
DABVP, Cert. IVUSS

IMAGING PERFORMED BY

Dr. Anderson

HOSPITAL NAME

Elizabeth AH

REFERRING VET

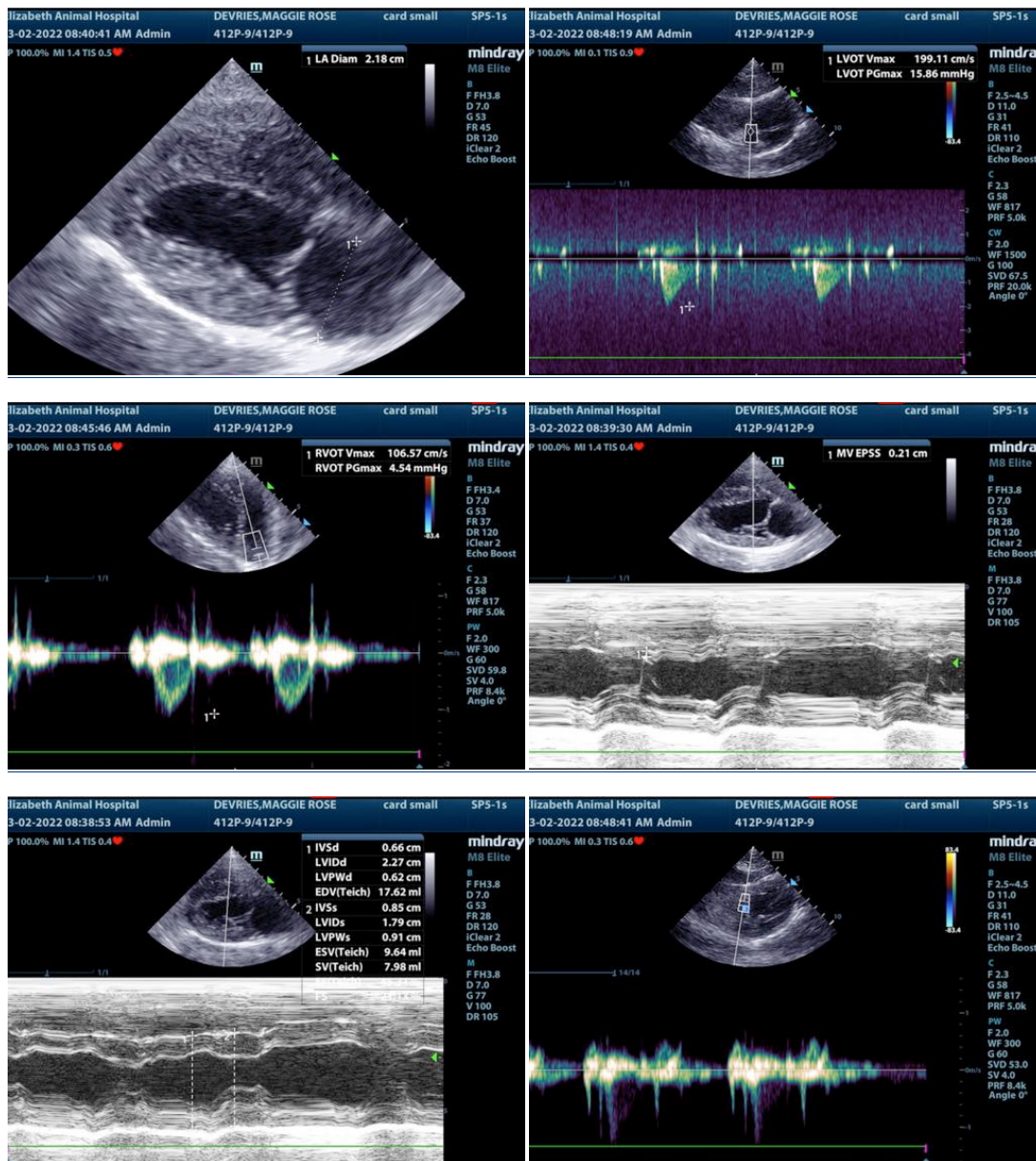
Dr. Anderson

INVOICE

96543

DATE

3/2/22



The information and recommendations provided are based on the images presented by the referring veterinarian/sonographer. No evaluation can be communicated regarding pathology that was not visible in the image/video clips provided.

Thank you for this referral. If the clinical or image interpretation does not parallel your findings or if I can be of any further assistance please contact me.

Eric Lindquist, DMV, DABVP, Cert. IVUSS, CEO of SonoPath.com
info@SonoPath.com