



PATIENT

Laguna Sullivan

SPECIES

Canine

BREED

Labrador Mix

SEX

Spayed Female

AGE

11 years

WEIGHT

60.3 lbs

INTERPRETED BY

Eric Lindquist, DMV
DABVP, Cert. IVUSS

IMAGING PERFORMED BY

Emily Kirk

HOSPITAL NAME

Shiloh AH

REFERRING VET

Audra Alley

INVOICE

96541

DATE

3/2/22

PRESENTING CLINICAL SIGNS

History of lung lobectomy to remove carcinoma and abdominal surgery to remove leiomyoma. Routine diagnostics to screen for recurrence (no symptoms at this time). Chest x-rays clear. Recent lab work however has shown mild increase in liver enzymes.

Abnormal PE/Chem/CBC/UA Results: ALT 180 (18 - 121 U/L) AST 37 (16 - 55 U/L) ALP 169 (5 - 160 U/L)

ULTRASONOGRAPHIC EXAMINATION OF THE ABDOMEN

Urinary System

The **urinary bladder**, trigone, and pelvic urethra presented normal thicknesses and normal tone. The ureters were not visible which is normal. No uroliths or sediment were visualized and anechoic urine was present. No evidence of inflammatory or neoplastic changes was noted. Ureteral papillae were normal.

The **left kidney** revealed normal size and structure, corticomedullary definition and ratio for this age. The cortices presented largely uniform texture with normal echogenic relationship to liver and spleen. Medullary structure differed distinctly from the cortex and no evidence of pelvic dilation was present. The capsules were acceptably uniform without significant irregularities. The right kidney measured 8.31 cm. The left kidney measured 7.23 cm.

Adrenal Glands

The **left adrenal gland** was visualized and recognized as having normal shape, size, position and echogenicity for this breed. The phrenic vasculature, glandular echogenicity and detail were unremarkable. Capsule, cortex, and medullary definition were normal for this age patient. The left adrenal gland measured 0.34 cm. The right adrenal gland was obscured by colonic artifact.

Spleen

The **spleen** presented a smooth homogeneous parenchyma hyperechoic to liver and renal cortical parenchyma. The capsule was smooth without noticeable expansion or deviation from within the spleen or adjacent pathology. The splenic vasculature demonstrated normal volume without signs of congestion or thrombosis. No sonographic evidence of acute or chronic inflammatory, neoplastic, or infarctual changes was noted.

Liver

The **liver** was largely normal with uniform parenchyma. The gallbladder and common bile duct were unremarkable. There was no evidence of visceral pathology.



PATIENT

Gastrointestinal

Laguna Sullivan

Examination of the **gastrointestinal tract** revealed a stomach and intestine free of stasis, of normal wall thickness, acceptable curvilinear mural detail, and peristaltic activity. Small and large intestine demonstrated normal luminal chyme and stool consistency respectively. Intestinal wall measured up to 0.55 cm. No obstructive or overt infiltrative disease was noted. No associated abnormal lymphatic activity was noted.

SPECIES

Canine

BREED

Labrador Mix

Pancreas

The base and limbs of the **pancreas** were observed to be largely isoechoic to surrounding omental fat. Pancreatic duct and capsular contour were acceptably normal and parenchyma respected normal curvilinear patterns. No overt evidence of active inflammatory or neoplastic disease was noted.

SEX

Spayed Female

ULTRASONOGRAPHIC FINDINGS

AGE

11 years

Unremarkable abdomen.

INTERPRETATION OF THE FINDINGS & FURTHER RECOMMENDATIONS

WEIGHT

60.3 lbs

No specific therapy is recommended at this time.

INTERPRETED BY

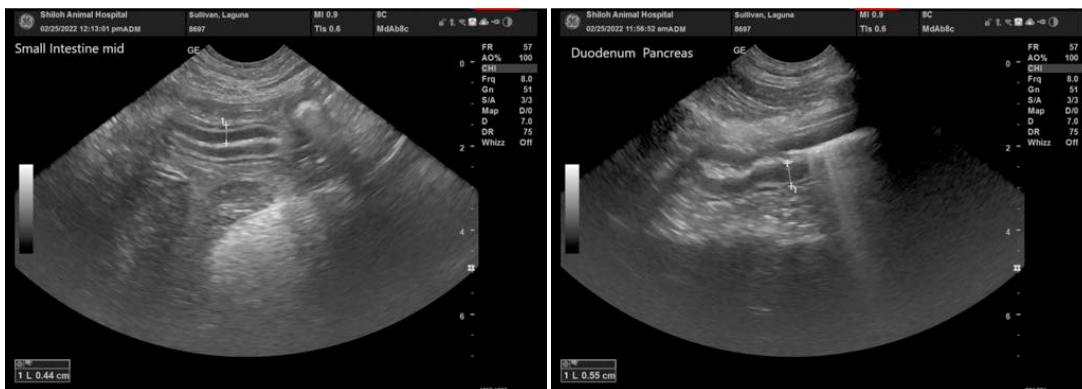
Eric Lindquist, DMV
DABVP, Cert. IVUSS

IMAGING PERFORMED BY

Emily Kirk

HOSPITAL NAME

Shiloh AH



REFERRING VET

Audra Alley

INVOICE

96541

DATE

3/2/22



PATIENT

Laguna Sullivan

SPECIES

Canine

BREED

Labrador Mix

SEX

Spayed Female

AGE

11 years

WEIGHT

60.3 lbs

INTERPRETED BY

Eric Lindquist, DMV
DABVP, Cert. IVUSS

IMAGING PERFORMED BY

Emily Kirk

HOSPITAL NAME

Shiloh AH

REFERRING VET

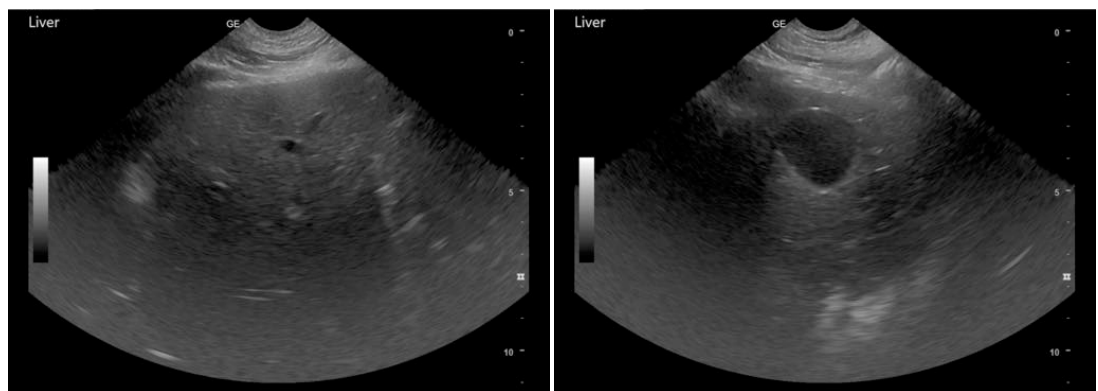
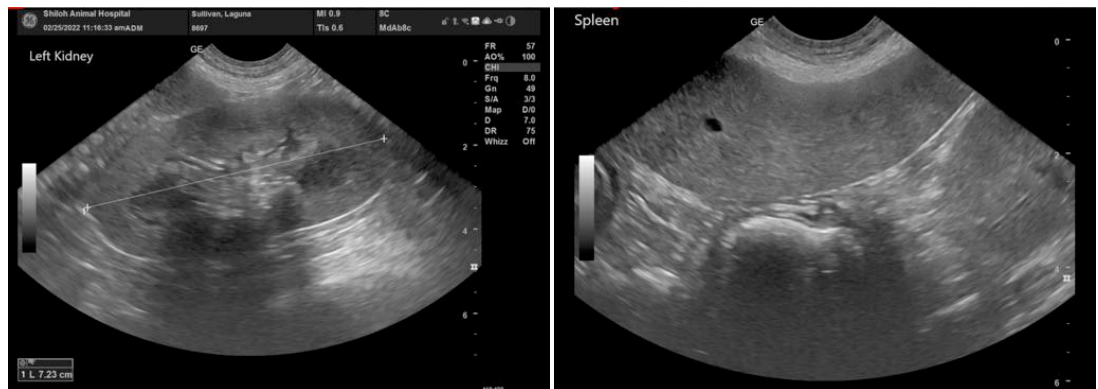
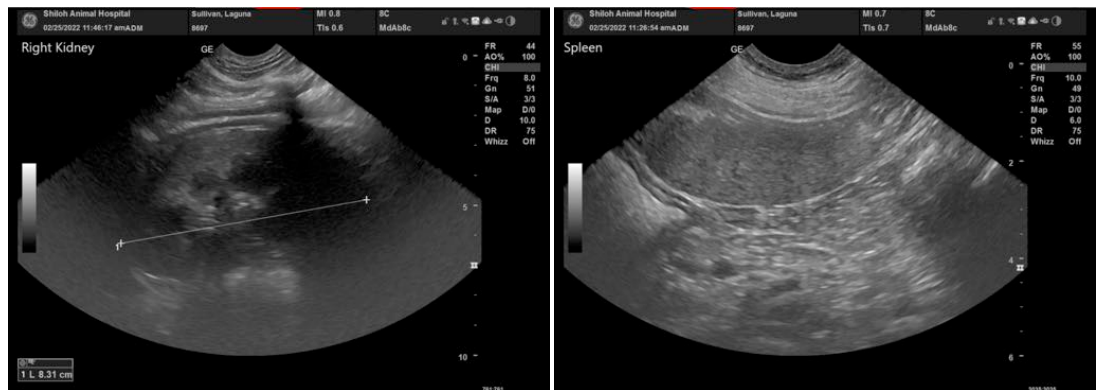
Audra Alley

INVOICE

96541

DATE

3/2/22



The information and recommendations provided are based on the images presented by the referring veterinarian/sonographer. No evaluation can be communicated regarding pathology that was not visible in the image/video clips provided.

Thank you for this referral. If the clinical or image interpretation does not parallel your findings or if I can be of any further assistance please contact me.

Eric Lindquist, DMV, DABVP, Cert. IVUSS, CEO of SonoPath.com



PATIENT

info@SonoPath.com

Laguna Sullivan

SPECIES

Canine

BREED

Labrador Mix

SEX

Spayed Female

AGE

11 years

WEIGHT

60.3 lbs

INTERPRETED BY

Eric Lindquist, DMV
DABVP, Cert. IVUSS

**IMAGING
PERFORMED BY**

Emily Kirk

HOSPITAL NAME

Shiloh AH

REFERRING VET

Audra Alley

INVOICE

96541

DATE

3/2/22