

**PATIENT**

Jax Rauscher

**PRESENTING CLINICAL SIGNS**

presently doing well at home, has history of licking the air a lot, hx of atopic dermatitis has stomach flare ups as well. On Hydrolyzed protein diet

**SPECIES**

Canine

**ULTRASONOGRAPHIC EXAMINATION OF THE ABDOMEN**

**Urinary System**

**BREED**

Mix

The **urinary bladder** revealed small calculi, non-obstructive, a grouping of which measured approximately 1.3 cm. The pelvic urethra was imaged 2.0 cm beyond the cystourethral junction.

**SEX**

Neutered Male

The **kidneys** revealed normal size and structure, corticomedullary definition and ratio for this age. The cortices presented largely uniform texture with normal echogenic relationship to liver and spleen. Medullary structure differed distinctly from the cortex and no evidence of pelvic dilation was present. The capsules were acceptably uniform without significant irregularities. The left kidney measured 4.67 cm. The right kidney measured 5.55 cm. Slight pinpoint mineralizations noted in the kidneys.

**AGE**

6 Years

**Adrenal Glands**

Both **adrenal glands** were visualized and recognized as having normal shape, size, position and echogenicity for this breed. The phrenic vasculature, glandular echogenicity and detail were unremarkable. Capsule, cortex, and medullary definition were normal for this age patient. The right adrenal gland measured 1.97 cm x 0.54 cm at the caudal pole and 0.72 cm at the cranial pole. The left adrenal gland measured 1.83 cm x 0.39 cm at the caudal pole and 0.34 cm at the cranial pole.

**WEIGHT**

23 Pounds

**Spleen**

The **spleen** presented a smooth homogeneous parenchyma hyperechoic to liver and renal cortical parenchyma. The capsule was smooth without noticeable expansion or deviation from within the spleen or adjacent pathology. The splenic vasculature demonstrated normal volume without signs of congestion or thrombosis. No sonographic evidence of acute or chronic inflammatory, neoplastic, or infarctual changes were noted.

**INTERPRETED BY**

Eric Lindquist, DMV

DABVP, Cert. IVUSS

**Liver**

The **liver** images submitted revealed subjectively normal liver size, contour, and structure. Parenchymal echogenicity was naturally coarse and hypoechoic to the spleen. Vascular and biliary tracts were of normal volume with no evidence of congestion. The gallbladder presented acceptably thin walls with primarily anechoic content. The cystic and common bile ducts were normal. No pathological hepatic lymphadenopathy was evident. No overt structural evidence of inflammatory, infiltrative or regenerative pathology was evident.

**IMAGING PERFORMED BY**

Jenn

**HOSPITAL NAME**

Rockaway AH

**Gastrointestinal**

Examination of the **gastrointestinal tract** revealed a stomach and intestine free of stasis, of normal wall thickness, acceptable curvilinear mural detail, and peristaltic activity. Small and large intestine demonstrated normal luminal chyme and stool consistency respectively. No obstructive or overt infiltrative disease was noted. No associated abnormal lymphatic activity was noted.

**REFERRING VET**

Dr. Maniar

**INVOICE**

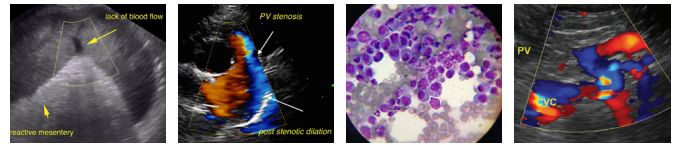
35808

**Pancreas**

The base and limbs of the **pancreas** were observed to be largely isoechoic to surrounding omental fat. Pancreatic duct and capsular contour were acceptably normal and parenchyma respected normal curvilinear patterns. No overt evidence of active inflammatory or neoplastic disease was noted.

**DATE**

3/2/22



**PATIENT**

Jax Rauscher

**ULTRASONOGRAPHIC FINDINGS**

- Structurally unremarkable abdomen and GI tract
- Slight pinpoint renal mineralizations and small bladder calculi

**SPECIES**

Canine

**INTERPRETATION OF THE FINDINGS & FURTHER RECOMMENDATIONS**

The patient may be passing calculi periodically. Given the patient history, underlying low-grade gastritis is possible without structural changes sonographically.

**BREED**

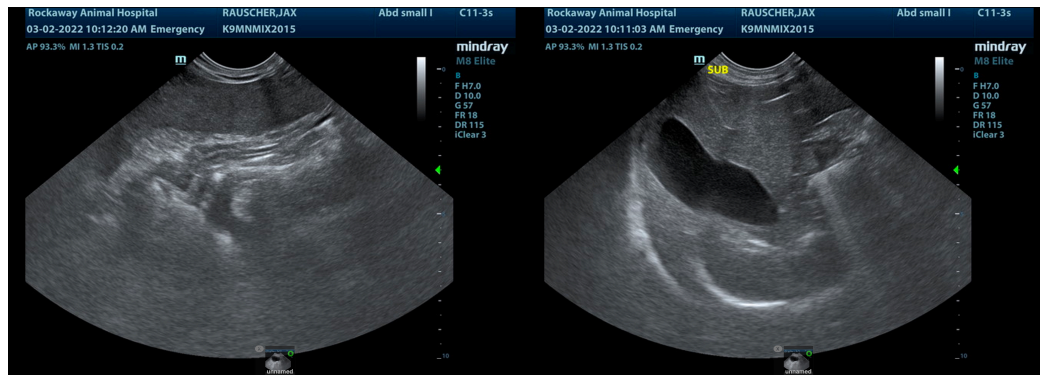
Mix

**SEX**

Neutered Male

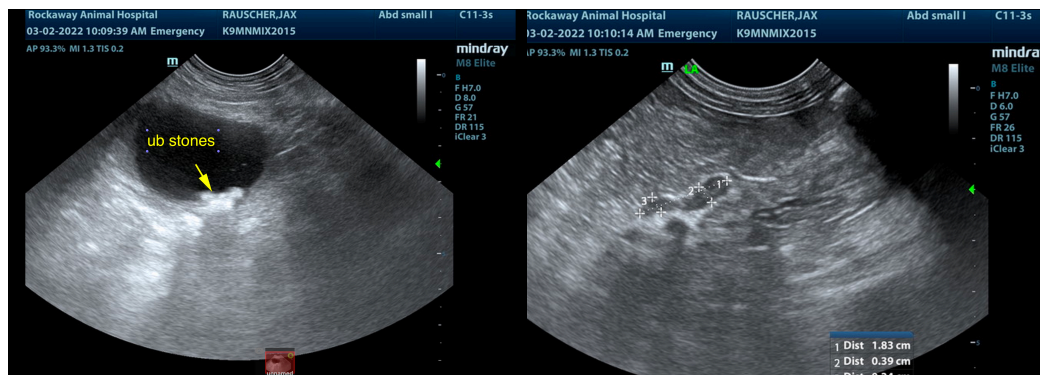
**AGE**

6 Years



**WEIGHT**

23 Pounds



**INTERPRETED BY**

Eric Lindquist, DMV  
DABVP, Cert. IVUSS

**IMAGING PERFORMED BY**

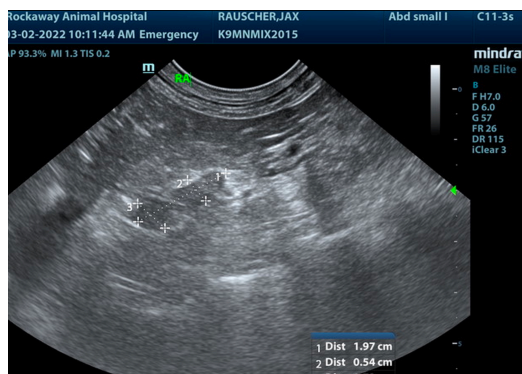
Jenn

**HOSPITAL NAME**

Rockway AH

**REFERRING VET**

Dr. Maniar

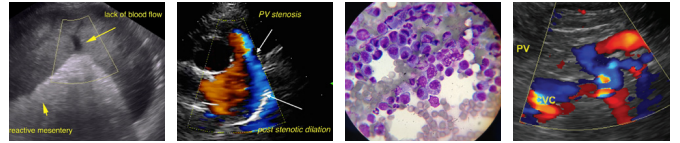


**INVOICE**

35808

**DATE**

3/2/22



**PATIENT**

Jax Rauscher

The information and recommendations provided are based on the images presented by the referring veterinarian/sonographer. No evaluation can be communicated regarding pathology that was not visible in the image/video clips provided.

**SPECIES**

Canine

Thank you for this referral. If the clinical or image interpretation does not parallel your findings or if I can be of any further assistance please contact me.

**Eric Lindquist**, DMV, DABVP, Cert. IVUSS, CEO of SonoPath.com

[info@SonoPath.com](mailto:info@SonoPath.com)

**BREED**

Mix

**SEX**

Neutered Male

**AGE**

6 Years

**WEIGHT**

23 Pounds

**INTERPRETED BY**

Eric Lindquist, DMV

DABVP, Cert. IVUSS

**IMAGING PERFORMED BY**

Jenn

**HOSPITAL NAME**

Rockaway AH

**REFERRING VET**

Dr. Maniar

**INVOICE**

35808

**DATE**

3/2/22