



**PATIENT**

Piper Weisman

**SPECIES**

Canine

**BREED**

Cavalier

**SEX**

Spayed Female

**AGE**

10 Years

**WEIGHT**

19.6 Pounds

**INTERPRETED BY**

Eric Lindquist, DMV,  
 DABVP (Canine & Feline), Cert. IVUSS

**IMAGING PERFORMED BY**

Meghan Morse, LVT

**HOSPITAL NAME**

Rondout Valley VA

**REFERRING VET**

Dr. Laux

**INVOICE**

36297

**DATE**

3/19/26

**PRESENTING CLINICAL SIGNS**

- Hasn't had an echo in 1.5 years
- Hx of degenerative mitral valve disease- ACVIM stage B2 and pulmonary hypertension
- Current meds: Enalapril and Vetmedin
- BP: 178, 176

**ULTRASONOGRAPHIC EXAMINATION OF THE HEART**

CANINE CARDIAC PARAMETERS	MR VMAX (m/s)	TR VMAX (m/s)	LA/AO (M-Mode)	LA/AO (Heart Base; Swe)	FS (%)	EF (%)	EPSS (cm)
NORMAL PARAMETER	4.5-5.5	<2.7	1.3	Up to 1.6	28-40	40-100	<0.6
PATIENT	5.8	--	1.4	1.3	43	75	0.1
CANINE CARDIAC PARAMETERS	HR (BPM)	AV VMAX (m/s)	PV MAX (m/s)	BODY WEIGHT (lbs)	LAD LA MAX 4 Chamber	LVIDd Avg; 2D and m-mode short axis (cm)	LVIDs Avg; 2D and m-mode short axis (cm)
NORMAL PARAMETER	50-100	0.7-1.7	0.7-1.6				
PATIENT	--	1.50	1.00	19.6 lbs	3.0	3.31	--

**Cardiac Presentation**

The cardiac presentation in this patient presented normalized volumes. Slight prolapse of the anterior mitral valve leaflet was noted. Contractility was adequate. No further left atrial enlargement was present under the current protocol. Trivial tricuspid regurgitation was noted. The pericardial and pleural space were unremarkable.

**ULTRASONOGRAPHIC FINDINGS**

- Compensated valvular disease on current protocol

**INTERPRETATION OF THE FINDINGS & FURTHER RECOMMENDATIONS**

Recommend maintaining the current protocol, and telmisartan may be appropriate to reduce systolic blood pressure <160 mmHg.



**PATIENT**

Piper Weisman

**SPECIES**

Canine

**BREED**

Cavalier

**SEX**

Spayed Female

**AGE**

10 Years

**WEIGHT**

19.6 Pounds

**INTERPRETED BY**

Eric Lindquist, DMV,  
 DABVP (Canine &  
 Feline), Cert. IVUSS

**IMAGING  
 PERFORMED BY**

Meghan Morse, LVT

**HOSPITAL NAME**

Rondout Valley VA

**REFERRING VET**

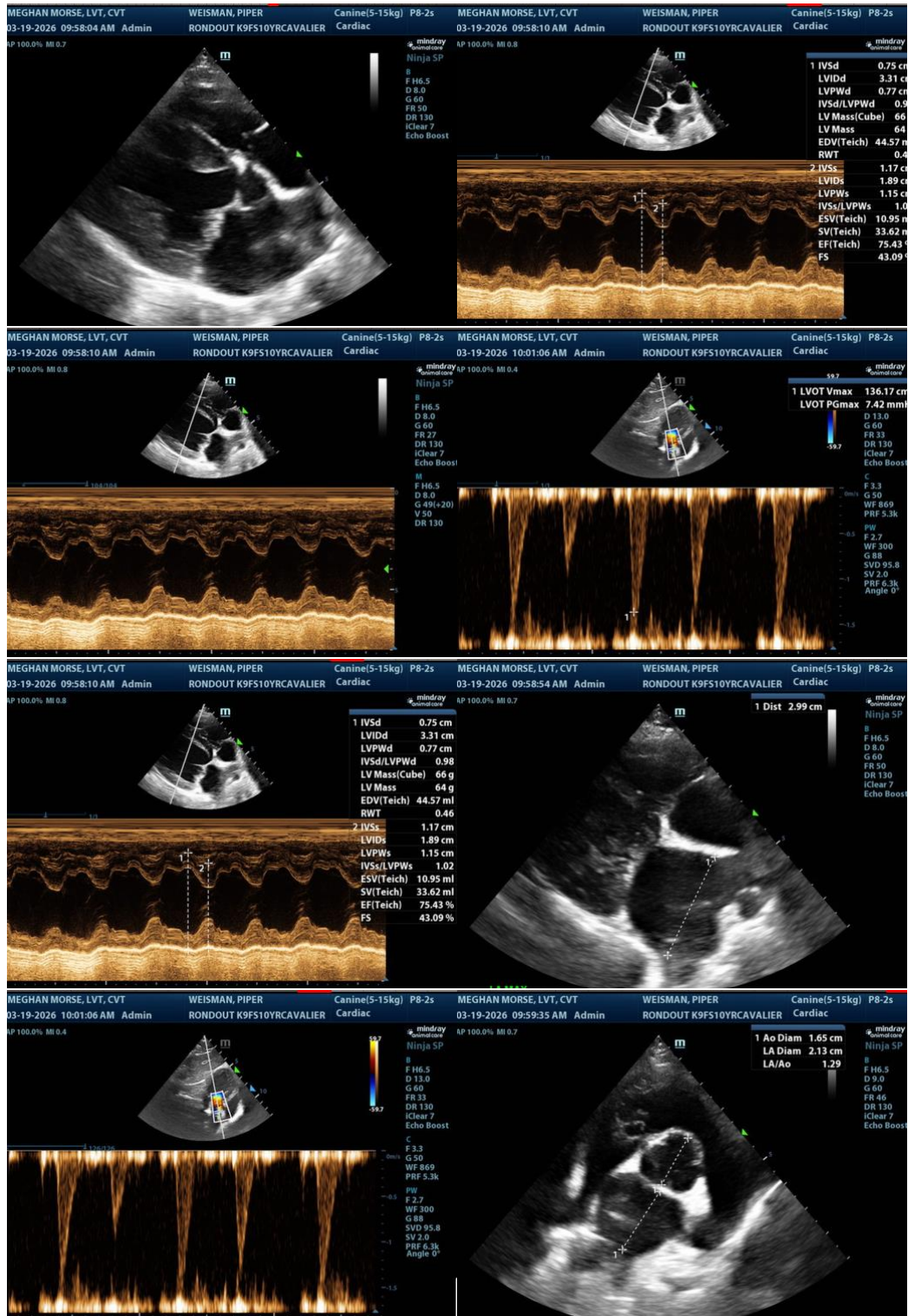
Dr. Laux

**INVOICE**

36297

**DATE**

3/19/26





**PATIENT**

Piper Weisman

**SPECIES**

Canine

**BREED**

Cavalier

**SEX**

Spayed Female

**AGE**

10 Years

**WEIGHT**

19.6 Pounds

**INTERPRETED BY**

Eric Lindquist, DMV,  
 DABVP (Canine &  
 Feline), Cert. IVUSS

**IMAGING PERFORMED BY**

Meghan Morse, LVT

**HOSPITAL NAME**

Rondout Valley VA

**REFERRING VET**

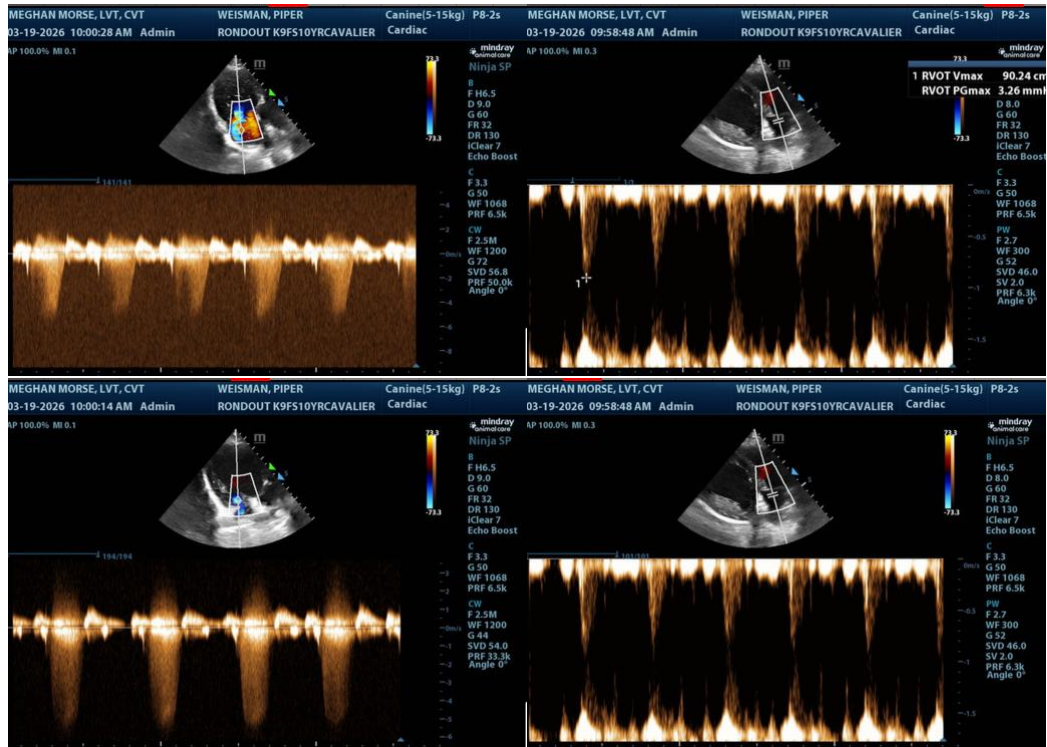
Dr. Laux

**INVOICE**

36297

**DATE**

3/19/26



The information and recommendations provided are based on the images presented by the referring veterinarian/sonographer. No evaluation can be communicated regarding pathology that was not visible in the image/video clips provided.

Thank you for this referral. If the clinical or image interpretation does not parallel your findings or if I can be of any further assistance please contact me.

Eric Lindquist, DMV, DABVP(CFM), Cert. IVUSS,  
 CEO, Owner, Founder -- SonoPath.com  
[info@SonoPath.com](mailto:info@SonoPath.com)