

PATIENT

Milo Grimaldo

SPECIES

Canine

BREED

Doodle

SEX

Neutered Male

AGE

10 Months

WEIGHT

11 kg

INTERPRETED BY

Eric Lindquist, DMV,
DABVP(CFM), Cert.
IVUSS

IMAGING PERFORMED BY

Nicole DeFalco

HOSPITAL NAME

PetMedic Urgent Care-
Westborough

REFERRING VET

Dr. Katie Sakakeeny

INVOICE

14452

DATE

03/19/26

PRESENTING CLINICAL SIGNS

- 3d hx vomiting (cloth)/diarrhea, hx dietary indiscretion/PICA

Abnormal PE/Chem/CBC/UA Results: AXR Radiologist report: CONCLUSION: 1. The gastric contents may represent normal residual ingesta versus foreign material. 2. Mild small intestinal distention - Differentials include infectious or inflammatory enteritis, pancreatitis and early mechanical ileus.

ULTRASONOGRAPHIC EXAMINATION OF THE ABDOMEN

Urinary System

The **urinary bladder**, trigone, and pelvic urethra presented normal thicknesses and normal tone. The ureters were not visible which is normal. No uroliths or sediment were visualized, and anechoic urine was present. No evidence of inflammatory or neoplastic changes were noted. Ureteral papillae were normal.

The **kidneys** revealed normal size and structure, corticomedullary definition and ratio for this age. The cortices presented largely uniform texture with normal echogenic relationship to liver and spleen. Medullary structure differed distinctly from the cortex and no evidence of pelvic dilation was present. The capsules were acceptably uniform without significant irregularities. The left kidney measured 4.9 cm in length. The right kidney measured 4.92 cm in length.

Adrenal Glands

The **left adrenal gland** was subnormal in size measuring 3.0 mm.

The region of the **right adrenal gland** was imaged with no evident pathology.

Spleen

The **spleen** presented a smooth homogeneous parenchyma hyperechoic to liver and renal cortical parenchyma. The capsule was smooth without noticeable expansion or deviation from within the spleen or adjacent pathology. The splenic vasculature demonstrated normal volume without signs of congestion or thrombosis. No sonographic evidence of acute or chronic inflammatory, neoplastic, or infarctual changes were noted.

Liver

The **liver** images submitted revealed subjectively normal liver size, contour, and structure. Parenchymal echogenicity was naturally coarse and hypoechoic to the spleen. Vascular and biliary tracts were of normal volume with no evidence of congestion. The gallbladder presented acceptably thin walls with primarily anechoic content. The cystic and common bile ducts were normal. No pathological hepatic lymphadenopathy was evident. No overt structural evidence of inflammatory, infiltrative or regenerative pathology was evident.

Gastrointestinal

Examination of the **gastrointestinal tract** revealed an unremarkable stomach and small intestine regarding structure. There were minor areas of luminal fluid noted. There was no evidence of obstructive pattern. Curvilinear patterns were retained throughout the gastrointestinal tract. Areas of hyperperistalsis were noted. This is consistent with response to irritation. The colon was unremarkable.



PATIENT

Milo Grimaldo

SPECIES

Canine

BREED

Doodle

SEX

Neutered Male

AGE

10 Months

WEIGHT

11 kg

INTERPRETED BY

Eric Lindquist, DMV,
DABVP(CFM), Cert.
IVUSS

IMAGING PERFORMED BY

Nicole DeFalco

HOSPITAL NAME

PetMedic Urgent Care-
Westborough

REFERRING VET

Dr. Katie Sakakeeny

INVOICE

14452

DATE

03/19/26

Pancreas

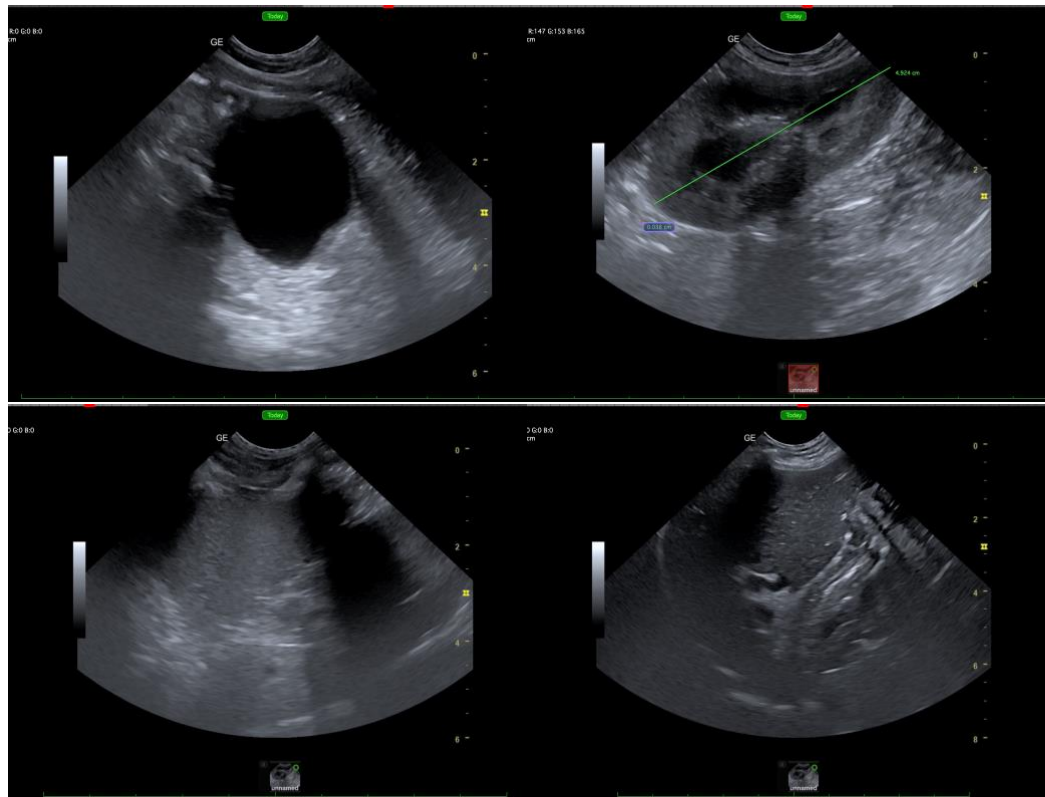
The base and limbs of the **pancreas** were observed to be largely isoechoic to surrounding omental fat. Pancreatic duct and capsular contour were acceptably normal and parenchyma respected normal curvilinear patterns. No overt evidence of active inflammatory or neoplastic disease was noted.

ULTRASONOGRAPHIC FINDINGS

- Gastroenteritis- nonspecific.
- Subnormal left adrenal size.

INTERPRETATION OF THE FINDINGS & FURTHER RECOMMENDATIONS

Screening for occult Addison's given the breed predisposition. Dietary indiscretion, food intolerance, structurally insignificant inflammatory bowel or occult parasitism and occult Addison's are all potentials.





PATIENT

Milo Grimaldo

SPECIES

Canine

BREED

Doodle

SEX

Neutered Male

AGE

10 Months

WEIGHT

11 kg

INTERPRETED BY

Eric Lindquist, DMV,
DABVP(CFM), Cert. IVUSS

IMAGING PERFORMED BY

Nicole DeFalco

HOSPITAL NAME

PetMedic Urgent Care-
Westborough

REFERRING VET

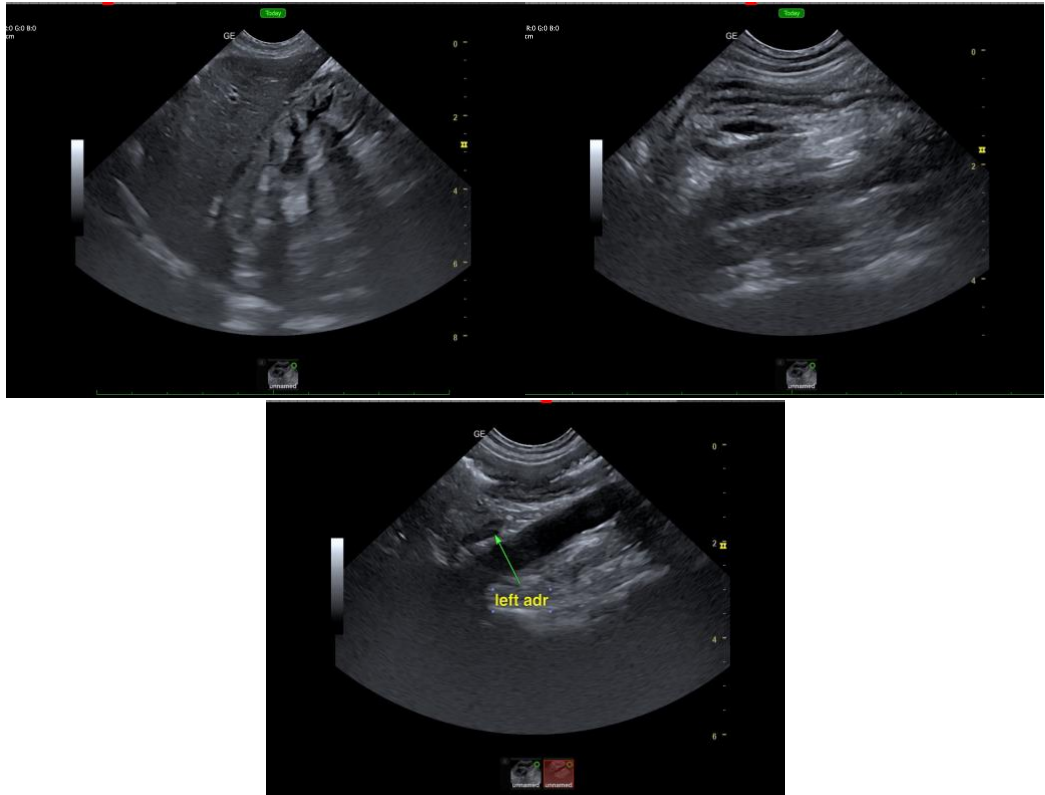
Dr. Katie Sakakeeny

INVOICE

14452

DATE

03/19/26



The information and recommendations provided are based on the images presented by the referring veterinarian/sonographer. No evaluation can be communicated regarding pathology that was not visible in the image/video clips provided.

Thank you for this referral. If the clinical or image interpretation does not parallel your findings or if I can be of any further assistance, please contact me.

Eric Lindquist, DMV, DABVP(CFM), Cert. IVUSS,

CEO, Owner, Founder -- SonoPath.com

info@SonoPath.com