



PATIENT

Lilly Bertacchi

SPECIES

Canine

BREED

German Shepherd Dog

SEX

Spayed Female

AGE

7 Years

WEIGHT

88 Pounds

INTERPRETED BY

Eric Lindquist, DMV,
DABVP (CFM), Cert.
IVUSS

IMAGING PERFORMED BY

Dr. Jeremiah Gabriel

HOSPITAL NAME

Central Jersey AH

REFERRING VET

Dr. Jeremiah Gabriel

INVOICE

36307

DATE

3/19/26

PRESENTING CLINICAL SIGNS

- Had grade 1 mammary gland tumors
- Owner wanna make sure no spread of the cancer specailly in the L.N
- Abnormal PE/Chem/CBC/UA Results: normal blood work

ULTRASONOGRAPHIC EXAMINATION OF THE ABDOMEN

Urinary System

The **urinary bladder**, trigone, and pelvic urethra presented normal thicknesses and normal tone. The ureters were not visible which is normal. No uroliths or sediment were visualized and anechoic urine was present. No evidence of inflammatory or neoplastic changes were noted. Ureteral papillae were normal. The pelvic urethra was imaged 2.0 cm beyond the cystourethral junction.

The **kidneys** revealed normal size and structure, corticomedullary definition and ratio for this age. The cortices presented largely uniform texture with normal echogenic relationship to liver and spleen. Medullary structure differed distinctly from the cortex, and no evidence of pelvic dilation was present. The capsules were acceptably uniform without significant irregularities. The left kidney measured 6.0 cm. The right kidney measured 7.3 cm.

Adrenal Glands

The regions of the **adrenal glands** were imaged, no evident pathology.

Spleen

The **spleen** revealed uniform enlargement and minor heterogenous parenchymal changes. This is typical German Shepherd splenomegaly. However, if any weight loss is present, then FNA is indicated.

Liver

The **liver** images submitted revealed subjectively normal liver size, contour, and structure. Parenchymal echogenicity was naturally coarse and hypoechoic to the spleen. Vascular and biliary tracts were of normal volume with no evidence of congestion. The gallbladder presented acceptably thin walls with primarily anechoic content. The cystic and common bile ducts were normal. No pathological hepatic lymphadenopathy was evident. No overt structural evidence of inflammatory, infiltrative or regenerative pathology was evident.

Gastrointestinal

Examination of the **gastrointestinal tract** revealed a stomach and intestine free of stasis, of normal wall thickness, acceptable curvilinear mural detail, and peristaltic activity. Small and large intestine demonstrated normal luminal chyme and stool consistency respectively. No obstructive or overt infiltrative disease was noted. No associated abnormal lymphatic activity was noted.

Pancreas

The base and limbs of the **pancreas** were observed to be largely isoechoic to surrounding omental fat. Pancreatic duct and capsular contour were acceptably normal and parenchyma respected normal curvilinear patterns. No overt evidence of active inflammatory or neoplastic disease was noted.



PATIENT

Lilly Bertacchi

SPECIES

Canine

BREED

German Shepherd Dog

SEX

Spayed Female

AGE

7 Years

WEIGHT

88 Pounds

INTERPRETED BY

Eric Lindquist, DMV,
DABVP (CFM), Cert.
IVUSS

IMAGING PERFORMED BY

Dr. Jeremiah Gabriel

HOSPITAL NAME

Central Jersey AH

REFERRING VET

Dr. Jeremiah Gabriel

INVOICE

36307

DATE

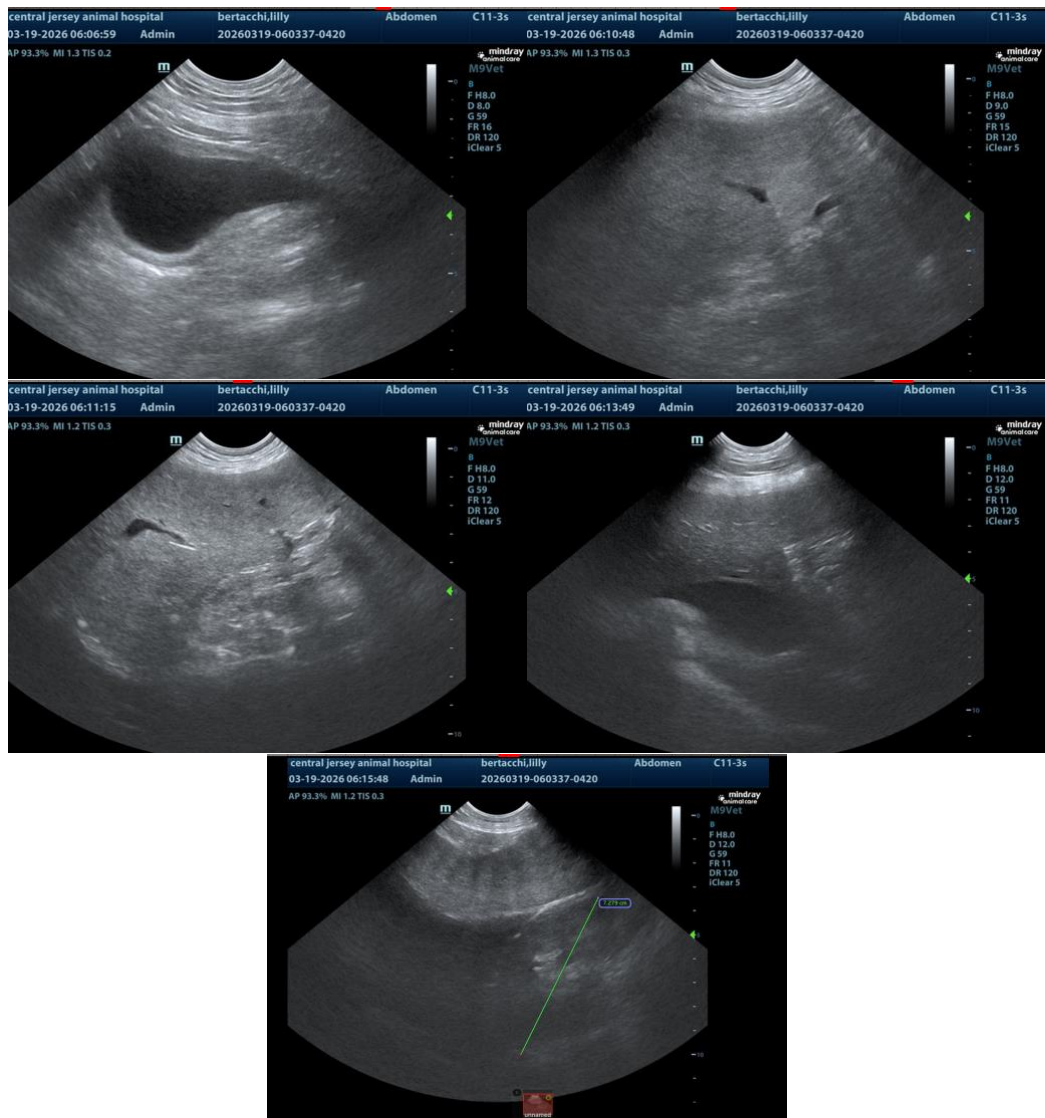
3/19/26

ULTRASONOGRAPHIC FINDINGS

- German Shepherd splenomegaly, typical for the breed.

INTERPRETATION OF THE FINDINGS & FURTHER RECOMMENDATIONS

Mid abdominal palpation is warranted. If the patient has discomfort on the spleen, then proactive splenectomy may be appropriate. Tick borne disease panel is indicated. FNA would be appropriate. No evidence of metastatic disease.



The information and recommendations provided are based on the images presented by the referring veterinarian/sonographer. No evaluation can be communicated regarding pathology that was not visible in the image/video clips provided.



PATIENT

Lilly Bertacchi

SPECIES

Canine

BREED

German Shepherd Dog

SEX

Spayed Female

AGE

7 Years

WEIGHT

88 Pounds

INTERPRETED BY

Eric Lindquist, DMV,
DABVP (CFM), Cert.
IVUSS

IMAGING PERFORMED BY

Dr. Jeremiah Gabriel

HOSPITAL NAME

Central Jersey AH

REFERRING VET

Dr. Jeremiah Gabriel

INVOICE

36307

DATE

3/19/26

Thank you for this referral. If the clinical or image interpretation does not parallel your findings or if I can be of any further assistance please contact me.

Eric Lindquist, DMV, DABVP(CFM), Cert. IVUSS,
CEO, Owner, Founder -- SonoPath.com
info@SonoPath.com