



**PATIENT**

Harley Antico

**SPECIES**

Canine

**BREED**

Mix Breed

**SEX**

Spayed Female

**AGE**

9 Years 11 Months

**WEIGHT**

59.4 pounds

**INTERPRETED BY**

Eric Lindquist, DMV,  
DABVP(CFM), Cert.  
IVUSS

**IMAGING PERFORMED BY**

Eric Lindquist, DMV,  
DABVP(CFM), Cert.  
IVUSS

**HOSPITAL NAME**

Wantage Veterinary  
Hospital

**REFERRING VET**

Dr. Karen Bullock

**INVOICE**

14447

**DATE**

03/19/26

**PRESENTING CLINICAL SIGNS**

ALT & ALK high. Bilirubin and AST also increased.

**ULTRASONOGRAPHIC EXAMINATION OF THE ABDOMEN**

*Urinary System*

The **urinary bladder**, trigone, and pelvic urethra to a depth of 2.0 cm presented normal thicknesses and normal tone. The ureters were not visible which is normal. No uroliths or sediment were visualized, and anechoic urine was present. No evidence of inflammatory or neoplastic changes were noted. Ureteral papillae were normal.

The **kidneys** revealed normal size and structure, corticomedullary definition and ratio for this age. The cortices presented largely uniform texture with normal echogenic relationship to liver and spleen. Medullary structure differed distinctly from the cortex and no evidence of pelvic dilation was present. The capsules were acceptably uniform without significant irregularities. The left kidney measured 5.62 cm in length. The right kidney measured 5.66 cm in length.

*Adrenal Glands*

Both **adrenal glands** were visualized and recognized as having normal shape, size, position and echogenicity for this breed. The phrenic vasculature, glandular echogenicity and detail were unremarkable. Capsule, cortex, and medullary definition were normal for this age patient. The left adrenal gland measured 2.78 cm x 0.72 cm width. The right adrenal gland measured 2.0 cm x 1.5 cm width at the cranial pole and 0.50 cm width at the caudal pole.

*Spleen*

The **spleen** presented a smooth homogeneous parenchyma hyperechoic to liver and renal cortical parenchyma. The capsule was smooth without noticeable expansion or deviation from within the spleen or adjacent pathology. The splenic vasculature demonstrated normal volume without signs of congestion or thrombosis. No sonographic evidence of acute or chronic inflammatory, neoplastic, or infarctual changes were noted. The spleen was folded upon itself cranially/caudally.

*Liver*

The **liver** presented with a significant amount of isoechoic nodular changes, irregular contour and increased portal markings. No overt masses were evident, however, coalescing nodules were present throughout the liver with areas of capsular retraction and expansion. The gallbladder and common bile duct were unremarkable.

*Gastrointestinal*

Examination of the **gastrointestinal tract** revealed a stomach and intestine free of stasis, of normal wall thickness, acceptable curvilinear mural detail, and peristaltic activity. Small and large intestine demonstrated normal luminal chyme and stool consistency respectively. No obstructive or overt infiltrative disease was noted. No associated abnormal lymphatic activity was noted.

*Pancreas*



**PATIENT**

Harley Antico

**SPECIES**

Canine

**BREED**

Mix Breed

**SEX**

Spayed Female

**AGE**

9 Years 11 Months

**WEIGHT**

59.4 pounds

**INTERPRETED BY**

Eric Lindquist, DMV,  
DABVP(CFM), Cert.  
IVUSS

**IMAGING PERFORMED BY**

Eric Lindquist, DMV,  
DABVP(CFM), Cert.  
IVUSS

**HOSPITAL NAME**

Wantage Veterinary  
Hospital

**REFERRING VET**

Dr. Karen Bullock

**INVOICE**

14447

**DATE**

03/19/26

The base and limbs of the **pancreas** were observed to be largely isoechoic to surrounding omental fat. Pancreatic duct and capsular contour were acceptably normal and parenchyma respected normal curvilinear patterns. No overt evidence of active inflammatory or neoplastic disease was noted.

**ULTRASONOGRAPHIC FINDINGS**

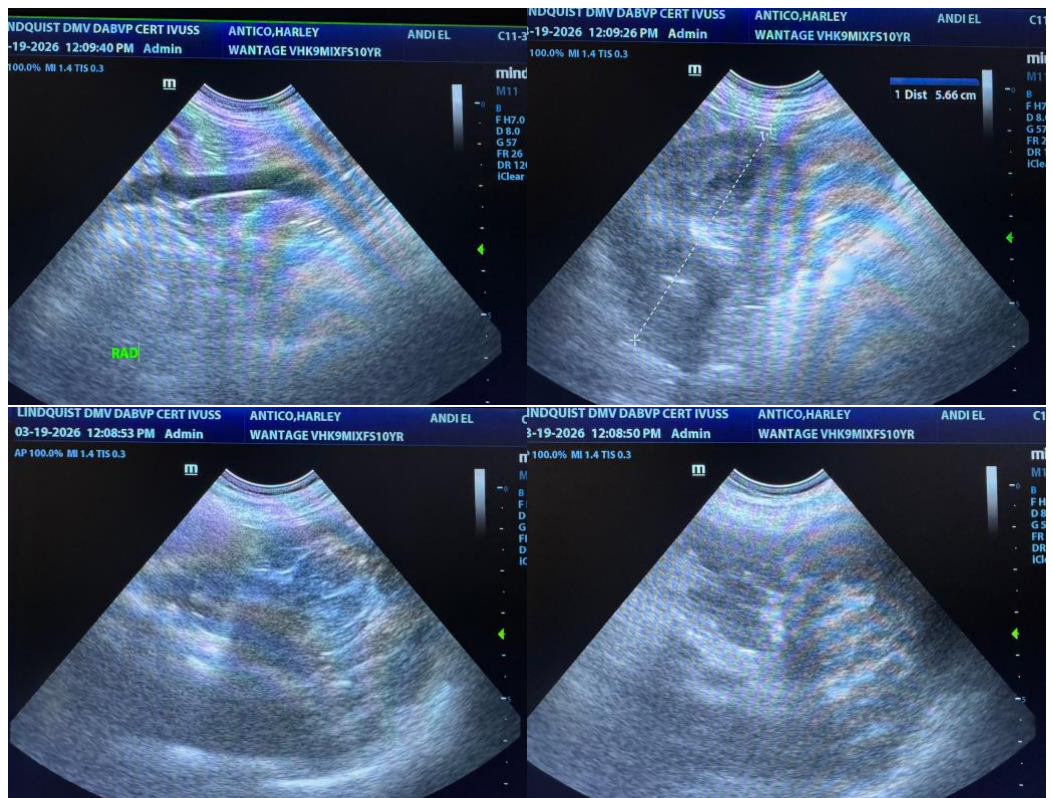
- Diffuse hepatic nodular changes consistent with hepatic cirrhosis with mild potential for underlying neoplasia.

**INTERPRETATION OF THE FINDINGS & FURTHER RECOMMENDATIONS**

The changes are diffuse and not surgical. Ultrasound-guided core liver biopsy is indicated after coagulation panel. FNA may allow for preliminary information. Underlying leptospirosis or other inciting causes should be considered. Prognosis is poor long-term depending on the ability to medically manage.

Internal medicine consult can be utilized through Sonopath.com. You can select the internal medicine drop down at <http://spa.sonopath.com/>.

One of the world's top internists & SonoPath associate Dr. Remo Lobetti BVSc, MMedVet, PhD, DECVIM can evaluate your case through SonoPath. <https://sonopath.com/resources/sonopath-services/internal-medicine-teleconsultation-services>





**PATIENT**

Harley Antico

**SPECIES**

Canine

**BREED**

Mix Breed

**SEX**

Spayed Female

**AGE**

9 Years 11 Months

**WEIGHT**

59.4 pounds

**INTERPRETED BY**

Eric Lindquist, DMV,  
 DABVP(CFM), Cert.  
 IVUSS

**IMAGING PERFORMED BY**

Eric Lindquist, DMV,  
 DABVP(CFM), Cert.  
 IVUSS

**HOSPITAL NAME**

Wantage Veterinary  
 Hospital

**REFERRING VET**

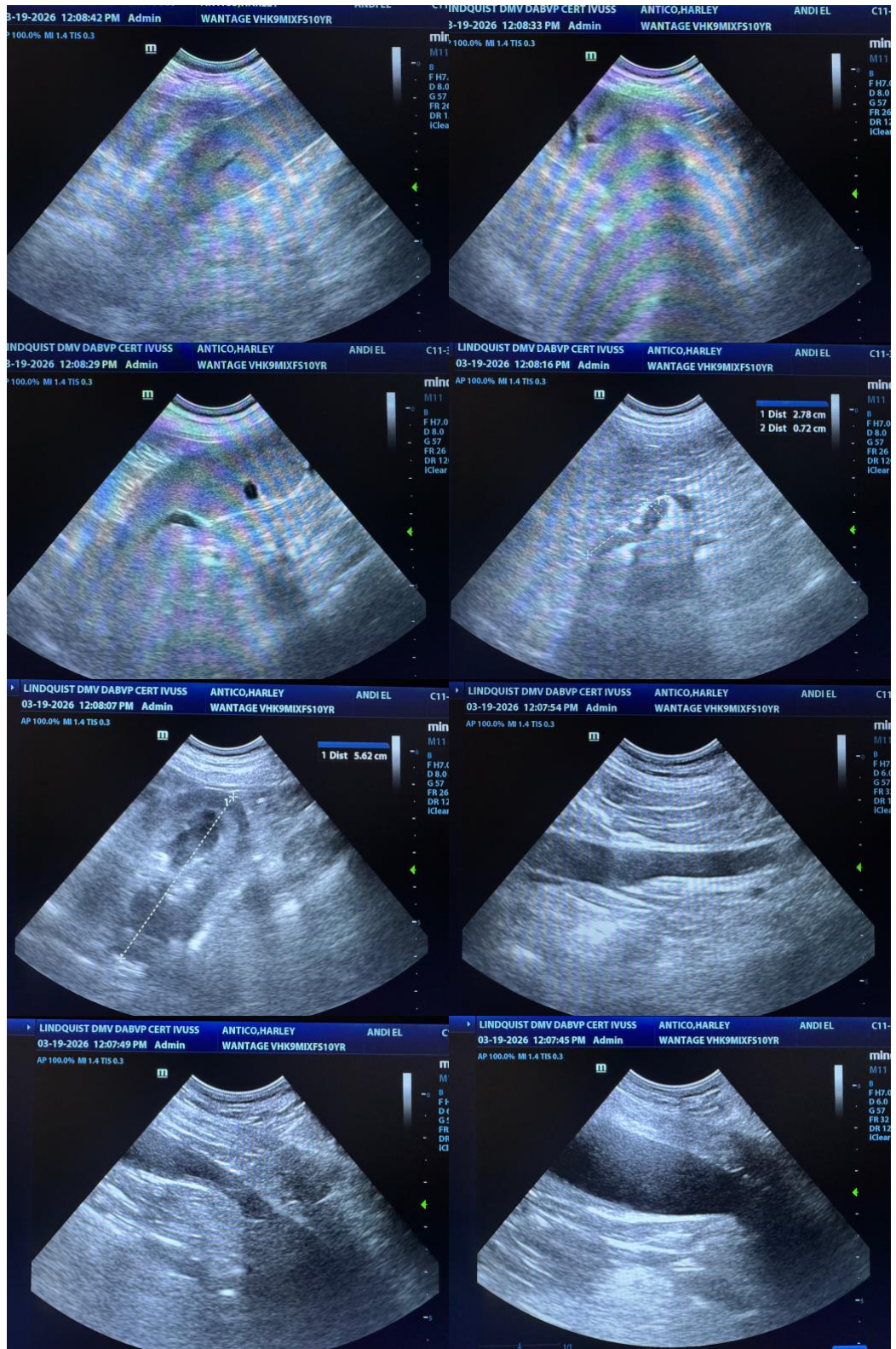
Dr. Karen Bullock

**INVOICE**

14447

**DATE**

03/19/26





**PATIENT**

Harley Antico

The information and recommendations provided are based on the images presented by the referring veterinarian/sonographer. No evaluation can be communicated regarding pathology that was not visible in the image/video clips provided.

**SPECIES**

Canine

Thank you for this referral. If the clinical or image interpretation does not parallel your findings or if I can be of any further assistance, please contact me.

**Eric Lindquist, DMV, DABVP(CFM), Cert. IVUSS,**

**BREED**

Mix Breed

CEO, Owner, Founder -- SonoPath.com

[info@SonoPath.com](mailto:info@SonoPath.com)

**SEX**

Spayed Female

**Canine Liver Disease & Treatment Recommendations**

<http://www.sonopath.com/K9LiverDisease>

**AGE**

9 Years 11 Months

**Description:** The etiologic causes of canine hepatic disease are vast and varied. Some cases may progress fairly rapidly, while others will remain static for a considerable length of time or even eventually reverse. Regardless of the cause, management is crucial to maintaining and optimizing quality of life. If possible, practitioners should obtain and be guided by a pathologic diagnosis so they can administer a treatment attuned to the underlying disease and arrive at a more exact prognosis.

**WEIGHT**

59.4 pounds

**Dietary Management:** A lower protein diet to support liver dysfunction should be initiated, especially in cases where hepatic encephalopathy is also present. Since dietary protein is low, the protein quality and bioavailability must conversely be high. It should be noted that a protein-restricted diet is not appropriate in all cases of hepatic disease, especially during the early phases, as protein restriction is unnecessary when there are no signs of significant hepatic dysfunction.

**INTERPRETED BY**

Eric Lindquist, DMV,  
DABVP(CFM), Cert.  
IVUSS

Therapeutic diets, such as Hill's® i/d® and Royal Canin® Hepatic™, are excellent choices and contain enhanced levels of nutrients such as, but not limited to:

- Branched chain amino acids, which bypass liver metabolism and are used directly for skeletal muscle accretion.
- Vitamin E, which helps minimize and reduce oxidative damage and stress from free radicals produced by stressed hepatocytes.
- Vitamin B complex, which helps drive intermediary metabolism.
- Reduced copper.
- Extremely digestible protein sources with high biologic values, which help minimize the total amount of dietary protein needed and thus reduce blood ammonia levels.
- Carnitine, which helps drive fatty acids into the mitochondria for beta-oxidation and positive cellular energy balance.

**IMAGING PERFORMED BY**

Eric Lindquist, DMV,  
DABVP(CFM), Cert.  
IVUSS

**HOSPITAL NAME**

Wantage Veterinary  
Hospital

**REFERRING VET**

Dr. Karen Bullock

**Medical Management:** The following list of medications is commonly used in the management of various hepatopathies or in the face of hepatic failure; however, each patient should be managed as an individual, and not all of the medications listed here are appropriate for each animal. One must always consider the definitive diagnosis of one's patient when developing a therapeutic plan. What follows is an outline of medical management recommendations for cholangiohepatitis and inflammatory hepatopathy/chronic hepatitis.

**INVOICE**

14447

**Cholangiohepatitis**

*1. Broad-spectrum antibiotics*

**DATE**

03/19/26

a) Amoxicillin: Give 20 mg/kg BID or amoxicillin/clavulanic acid (13.75 mg/kg PO BID) for potential suppurative hepatitis. Options: ampicillin: 20 mg/kg IV TID; cephalexin: 20 mg/kg IV or PO TID; enrofloxacin: 2.5-5 mg/kg PO BID if cholangiohepatitis is present or to decrease ammonia production; gentamycin: 2 mg/kg TID IM or SC for 5-7 days if sepsis or peritonitis is present. Monitor renal function if aminoglycosides are utilized.



**PATIENT**

Harley Antico

**SPECIES**

Canine

**BREED**

Mix Breed

**SEX**

Spayed Female

**AGE**

9 Years 11 Months

**WEIGHT**

59.4 pounds

**INTERPRETED BY**

Eric Lindquist, DMV,  
DABVP(CFM), Cert.  
IVUSS

**IMAGING PERFORMED BY**

Eric Lindquist, DMV,  
DABVP(CFM), Cert.  
IVUSS

**HOSPITAL NAME**

Wantage Veterinary  
Hospital

**REFERRING VET**

Dr. Karen Bullock

**INVOICE**

14447

**DATE**

03/19/26

b) Metronidazole: Give 10-20 mg/kg BID in combination with amoxicillin/clavulanic acid or enrofloxacin for cholangiohepatitis because of its efficacy against anaerobic bacteria and/or for its immunomodulating effects. The dose is decreased to 7.5 mg/kg PO TID in the face of hepatic failure and/or encephalopathy. Controls ammonia production in the colon, decreases bacteria absorbed through portal circulation, and reduces cell-mediated immune responses (anti-inflammatory properties).

*2. Hepatic support*

a) S-adenosylmethionine (SAME): Give 20 mg/kg/day PO on an empty stomach (1-2 hours before feeding). It is available in 90 mg tablets that are not to be broken. SAME replenishes glutathione and aids in cellular detoxification; it also has anti-arthritis effects. SAME is an anti-inflammatory and antioxidant. It also promotes hepatocellular regeneration and rectifies RBC membrane abnormalities in dogs with liver disease or oxidative damage.

b) Milk Thistle: Administer as silybin or silymarin extracts (a high-quality supplement is essential). Acts as an antioxidant and free radical scavenger; decreases hepatotoxin binding; improves glutathione concentrations; aids in iron chelating; and promotes cholestasis. Give 5-15 mg/kg/day PO.

c) Ursodiol (Actigall): Give 10-15 mg/kg PO once daily, with food, to stimulate bile flow and decrease cholestasis. Tablets (250 mg) or capsules (300 mg) are available; however, ursodiol can also be compounded into a liquid to dose small patients. It has immunomodulatory, anti-fibrotic, and choleric effects, anti-copper storage benefits, and stabilizes mitochondrial function.

d) Vitamin E: Must be coupled with good nutrition and other antioxidants to avoid accumulation of tocopheroxyl radicals. To that end, supplementation with SAME may help ensure that adequate GSH (mitochondrial glutathione) concentrations are achieved. Give 10-15 IU/kg/day PO (100-400 IU) in a water-soluble form twice daily, as well as with Vitamin C 25 mg/kg/day.

e) Cobalamin and Thiamine (B12 and B1): Give 250ug SC weekly.

**Inflammatory hepatopathy/chronic hepatitis**

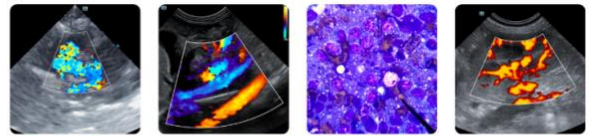
*1. Immunosuppressive agents*

a) Prednisone or prednisolone: Administer if inflammatory disease has been diagnosed by biopsy, beginning at 2 mg/kg/day for 2-4 weeks; subsequently reduce to 1 mg/kg/day. Once remission has been achieved, taper to 0.5 mg/kg/day (or to the lowest tolerable dose) over 2-4 weeks. Steroids may be discontinued if a different immunosuppressive medication is effective at controlling inflammation (i.e., azathioprine or cyclosporine) since they are contraindicated with hepatic encephalopathy. Possible negative sequelae of corticosteroids include increased water retention and potentiation of gastrointestinal ulceration. In the face of portal hypertension and ascites, dexamethasone is preferred—it does not exhibit mineralocorticoid activity and thus does not potentiate water retention as compared to prednisone—at 0.2-0.4 mg/kg orally once daily. Taper in a similar manner.

b) Azathioprine (Imuran): Give 50 mg/m<sup>2</sup>/day or 2 mg/kg/day as a long-term alternative to prednisone. The dose can be decreased to 1 mg/kg and eventually given every other day if there is a positive response. Check CBC and platelet count biweekly for the first 2 months and then monthly thereafter. Taper every 2-4 weeks to the lowest effective dose while monitoring transaminase levels. It can often be dosed on alternate days to prednisone. Possible negative side effects include bone marrow suppression and hepatic necrosis. Cyclosporine has been proposed as an alternative immunosuppressant in the management of chronic hepatitis and may allow one to cease concurrent steroid therapy; however, this has not been thoroughly investigated as of yet.

*2. Hepatic Support*

See medications listed in the previous section.



**PATIENT**

Harley Antico

**SPECIES**

Canine

**BREED**

Mix Breed

**SEX**

Spayed Female

**AGE**

9 Years 11 Months

**WEIGHT**

59.4 pounds

**INTERPRETED BY**

Eric Lindquist, DMV,  
DABVP(CFM), Cert.  
IVUSS

**IMAGING PERFORMED BY**

Eric Lindquist, DMV,  
DABVP(CFM), Cert.  
IVUSS

**HOSPITAL NAME**

Wantage Veterinary  
Hospital

**REFERRING VET**

Dr. Karen Bullock

**INVOICE**

14447

**DATE**

03/19/26

3. *Anti-fibrotics*

a) Colchicine: Give 0.03 mg/kg/day. Colchicine acts as an anti-inflammatory agent, stabilizes membranes, and stimulates collagenase production, thereby diminishing fibrosis. Colchicine should be used to treat hepatic fibrosis based on biopsy results; however, it can also be considered when ascites is present, and when hepatic fibrosis and cirrhosis are highly suspected based on sonographic appearance and clinical findings. It can result in adverse effects, including vomiting, diarrhea, and inappetance. Discontinue until clinical signs resolve, and reinstitute at a lower dose and up-titrate slowly.

4. *Hepatic Encephalopathy*

a) Lactulose: Give 0.5 ml/kg orally 2-3 times daily to soften the stool. It helps manage hepatic encephalopathy by combining with ammonium in the GI tract and thus decreasing circulating ammonia levels. Use in conjunction with low dose metronidazole. Lactulose can also be given as a retention enema in an encephalopathic crisis.

b) Metronidazole: Give at 7.5 mg/kg PO TID. Neomycin is an alternative and can be administered at 22 mg/kg PO BID-TID.

c) L-Carnitine: Give 200-400 mg/day. Normally synthesized by the liver, L-Carnitine enhances ammonia elimination and is indicated in cases of hepatic encephalopathy and lipidosis. Carnitine must be in the L-form.

5. *Copper Chelation*

Use chelation when copper toxicity has been documented on biopsy and quantification has been performed to confirm toxic levels.

a) D-penicillamine: Give 10-15 mg/kg PO BID on an empty stomach. This is a copper chelator and should only be used based on a quantitative analysis of copper. Possible side effects include vomiting and inappetance. Do not give in conjunction with zinc.

b) 2,3,2 Tetramine (Syprine, Cuprid): Give 5-7 mg/kg PO BID on an empty stomach (1-2 hours before eating). An alternative to D-penicillamine for those dogs that are intolerant.

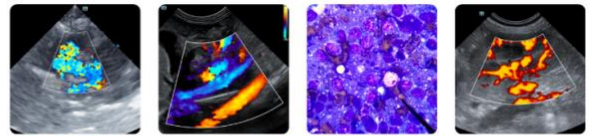
c) Zinc gluconate, acetate, or sulfate (acetate is best tolerated): Give 15-10 mg/kg elemental zinc divided BID for 2-6 months as a loading dose. Administer on an empty stomach (30-60 minutes before eating). Reduce to half the dose during the maintenance phase. A low copper diet is preferred (i.e., therapeutic diets, such as Hill's I/d® or Royal Canin® Hepatic™, are advisable). Zinc binds with intestinal copper to avoid absorption in the gastrointestinal tract and may be used alone in mild cases of copper toxicity. The goal is to reach zinc serum levels of 200-600 ug/dl; levels should initially be measured every 2-3 months. Give this medication on an empty stomach or with tuna fish to avoid vomiting. Zinc is not as effective as D-penicillamine and is only used in mild cases. It is not used in conjunction with D-penicillamine.

6. *Portal Hypertension and Ascites*

a) Spironolactone: If ascites is present secondary to portal hypertension, spironolactone can be dosed at 1-2 mg/kg PO BID; it is the diuretic of choice. Alternatively, spironolactone can be used in conjunction with furosemide (0.5-1 mg/kg PO BID) or hydrochlorothiazide; one should administer 1 mg/kg PO BID if given in conjunction with another diuretic. Monitor renal function and electrolytes diligently.

b) Famotidine: Give 0.5 mg/kg PO BID in cases of portal hypertension that result in gastrointestinal bleeding/melena.

**General Notes on Therapeutic Management:** Given that a primary function of the liver is to metabolize oral medications via the portal system (first past effect), numerous medications may result in higher systemic exposure to parent compounds in the face of hepatic insufficiency or failure. Drugs that are inactivated by the liver, produce hepatic damage, or require hepatic metabolism should be avoided. These include: lincomycin, clindamycin, streptomycin, chloramphenicol, sulfonamides, erythromycin, hetacillin, phenobarbital, diazepam, oxy- or chloro-tetracyclines, azole antifungals, nonsteroidal



**PATIENT**

Harley Antico

**SPECIES**

Canine

**BREED**

Mix Breed

**SEX**

Spayed Female

**AGE**

9 Years 11 Months

**WEIGHT**

59.4 pounds

**INTERPRETED BY**

Eric Lindquist, DMV,  
DABVP(CFM), Cert.  
IVUSS

**IMAGING  
PERFORMED BY**

Eric Lindquist, DMV,  
DABVP(CFM), Cert.  
IVUSS

**HOSPITAL NAME**

Wantage Veterinary  
Hospital

**REFERRING VET**

Dr. Karen Bullock

**INVOICE**

14447

**DATE**

03/19/26

anti-inflammatory drugs (NSAIDs), theophylline or chloramphenicol, combinations of cimetidine and metronidazole, and combinations of enrofloxacin and theophylline or cisapride. In cases of hepatic lipidosis, glucocorticoids, anabolic steroids, and lipotropic agents containing methionine should be avoided as they result in the production of encephalopathic toxins (metacarpans). Glucocorticoids are indicated for cholangitis, but only after lymphoma and hepatic lipidosis have been ruled out.

**References:**

Bauer E. Hepatic disease, nutritional therapy, and the metabolic environment. *J Am Vet Med Assoc* 1996;209(11):1850-54.

Bradley AM and Twedt DC. Cyclosporine therapy for canine chronic hepatitis: a retrospective study. Proceedings from the American College of Veterinary Internal Medicine, Anaheim, CA, June 15-18, 2011.

Center SA. Chronic hepatitis, cirrhosis, breed-specific hepatopathies, copper storage hepatopathy, suppurative hepatitis, granulomatous hepatitis, and idiopathic hepatic fibrosis. In: Guilford WG, Center SA, Strombeck DR, Williams DA, and Meyer DJ, eds: *Strombeck's Small Animal Gastroenterology 3rd ed*. Philadelphia, PA: WB Saunders; 1996:705-65.

Center S. Metabolic, antioxidant, nutraceutical, probiotic, and herbal therapies relating to the management of hepatobiliary disorders. *Vet Clin North Am Small Anim Pract* 2004;34(1):67-172.

Center SA. Diagnostic and managerial pearls for selected hepatobiliary disorders. Proceedings from the American College of Veterinary Internal Medicine. New Orleans, LA, May 30-June 2, 2012.

Davenport D. Antimicrobial therapy for gastrointestinal, pancreatic, and hepatic disorders. *Probl Vet Med* 1990;2(2):374-93.

Hackett T, Twedt D, Gustafson D. Milk thistle and its derivative compounds: a review of opportunities for treatment of liver disease. *J Vet Intern Med* 2013;27(1):10-16.

Thompson M, Meyer D, Senior D. Effects of treatment with ursodeoxycholic acid on bile acid profiles in a dog with chronic hepatic disease. *J Vet Intern Med* 1991;5(2):130.