



PATIENT

Gray Man Gold

SPECIES

Feline

BREED

DSH

SEX

Neutered Male

AGE

5 Years

WEIGHT

11.36

INTERPRETED BY

Eric Lindquist, DMV,
DABVP(CFM), Cert.
IVUSS

IMAGING PERFORMED BY

Dr. Brianna Gaines

HOSPITAL NAME

Healthy Pets
Veterinary Care- Boca
North

REFERRING VET

Dr. Brianna Gaines

INVOICE

14442

DATE

03/19/26

PRESENTING CLINICAL SIGNS

- Patient is receiving subcutaneous fluids daily (IV fluids declined) and patient has lost 0.5lbs and is still not eating well. Patient's antibiotics were switched today.

ULTRASONOGRAPHIC EXAMINATION OF THE ABDOMEN

Urinary System

The **urinary bladder**, trigone, and pelvic urethra to a depth of 1.0 cm presented normal thicknesses and normal tone. The ureters were not visible which is normal. No uroliths or sediment were visualized, and anechoic urine was present. No evidence of inflammatory or neoplastic changes were noted. Ureteral papillae were normal.

The **kidneys** revealed normal size and contour with minor increased renal echogenicity similar to the prior sonogram. The left kidney measured 4.5 cm in length. The right kidney measured 4.9 cm in length.

Adrenal Glands

Both **adrenal glands** were not visualized.

Spleen

The **spleen** in this patient was uniform, yet volume contracted. Hydration status should be assessed.

Liver

The **liver** images submitted revealed subjectively normal liver size, contour, and structure. Parenchymal echogenicity was naturally coarse and hypoechoic to the spleen. Vascular and biliary tracts were of normal volume with no evidence of congestion. The gallbladder presented acceptably thin walls with primarily anechoic content. The cystic and common bile ducts were normal. No pathological hepatic lymphadenopathy was evident. No overt structural evidence of inflammatory, infiltrative or regenerative pathology was evident.

Gastrointestinal

The **stomach** presented with a minor amount of fluid filled lumen. The transverse colon was excessively repleted. Minor excessive GI gas was noted.

Pancreas

The base and limbs of the **pancreas** were observed to be largely isoechoic to surrounding omental fat. Pancreatic duct and capsular contour were acceptably normal and parenchyma respected normal curvilinear patterns. No overt evidence of active inflammatory or neoplastic disease was noted.

ULTRASONOGRAPHIC FINDINGS

- Minor gastric fluid accumulation.
- Minor excessive GI gas.
- Volume contracted spleen.

INTERPRETATION OF THE FINDINGS & FURTHER RECOMMENDATIONS



PATIENT

Gray Man Gold

SPECIES

Feline

BREED

DSH

SEX

Neutered Male

AGE

5 Years

WEIGHT

11.36

INTERPRETED BY

Eric Lindquist, DMV,
DABVP(CFM), Cert.
IVUSS

IMAGING PERFORMED BY

Dr. Brianna Gaines

HOSPITAL NAME

Healthy Pets
Veterinary Care- Boca
North

REFERRING VET

Dr. Brianna Gaines

INVOICE

14442

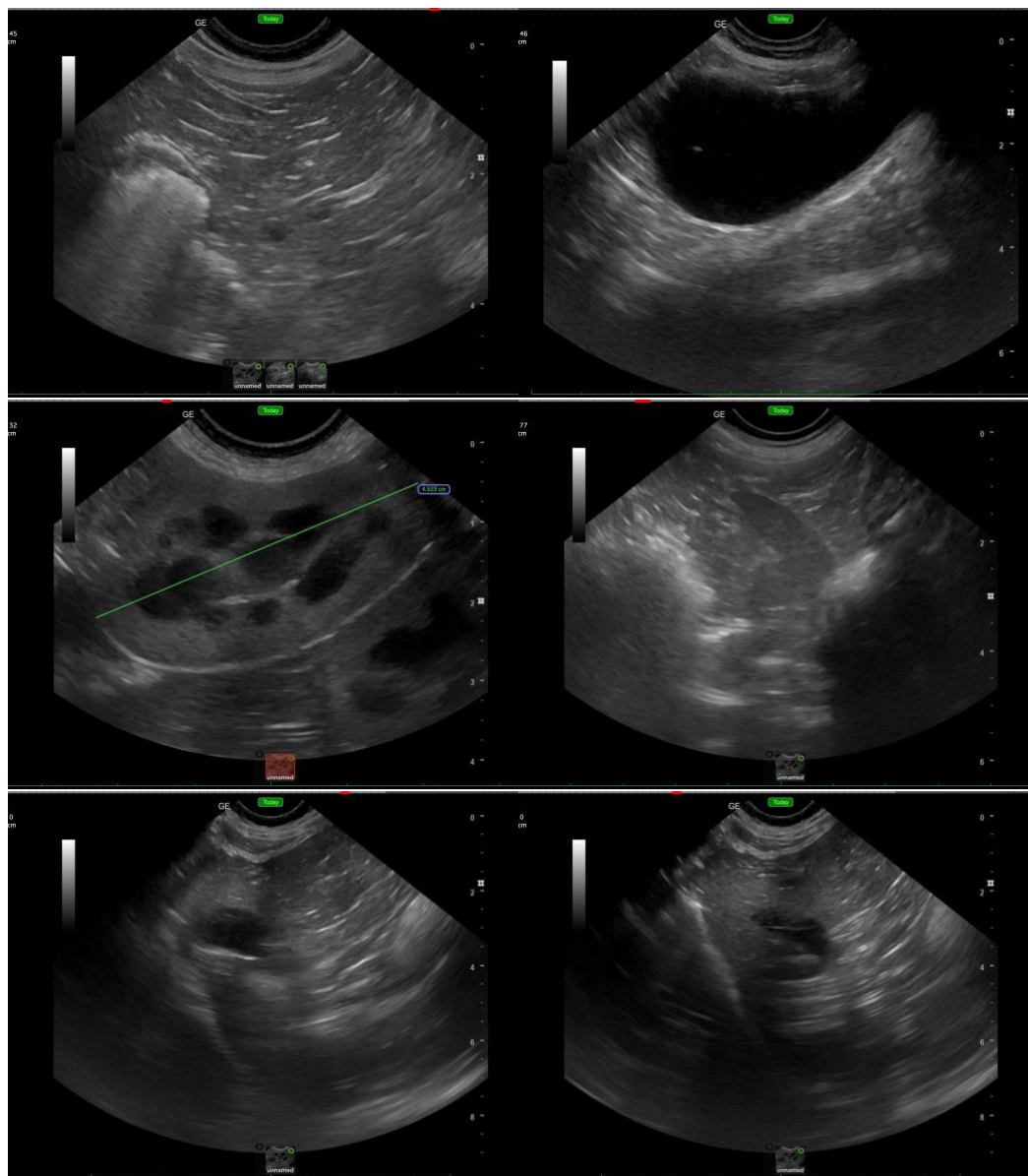
DATE

03/19/26

No evidence of significant visceral pathology. Maldigestion panel, three view chest radiographs and full CNS examination is recommended to examine for occult disease that could be responsible for the weight loss. Evaluation for competitive eating environments should also be considered.

The gastric ileus noted on the prior sonogram on 3/13 is largely resolved, however, some minor residual fluid filled lumen noted. I recommend hairball management in this patient in case delayed outflow may be partially owing to hairball transit.

No evidence of foreign matter, however hairball accumulation/trichobezoar may be an issue in this patient.





PATIENT

Gray Man Gold

SPECIES

Feline

BREED

DSH

SEX

Neutered Male

AGE

5 Years

WEIGHT

11.36

INTERPRETED BY

Eric Lindquist, DMV,
DABVP(CFM), Cert.
IVUSS

IMAGING PERFORMED BY

Dr. Brianna Gaines

HOSPITAL NAME

Healthy Pets
Veterinary Care- Boca
North

REFERRING VET

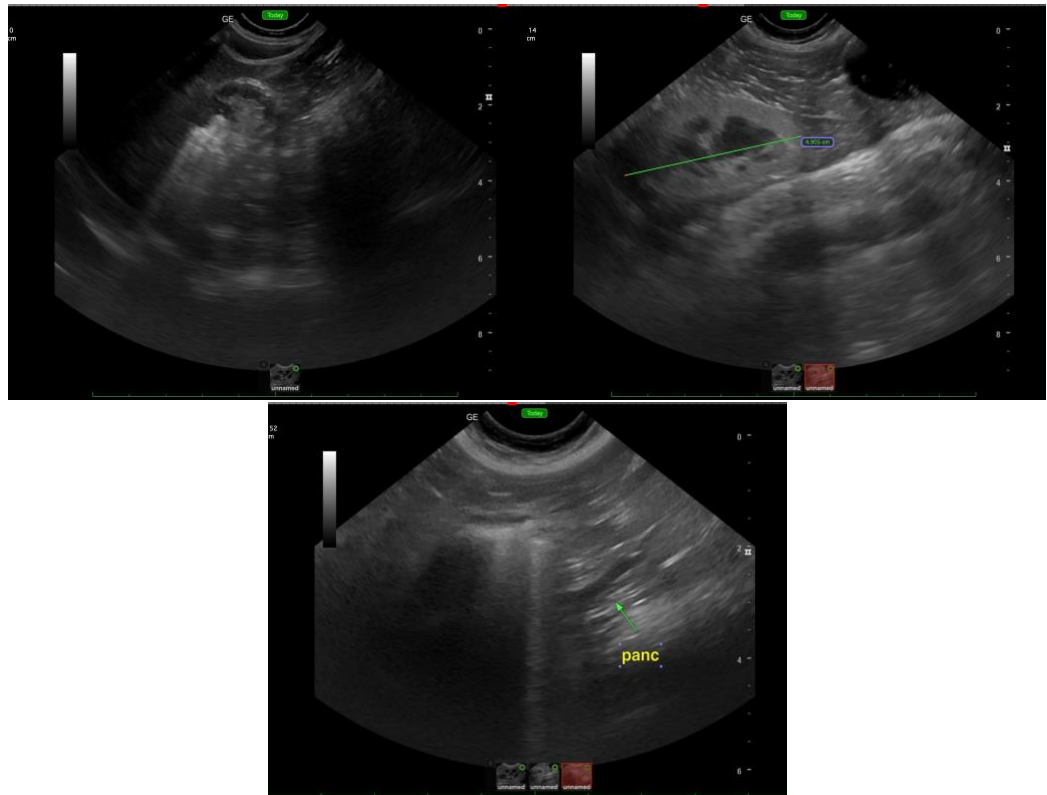
Dr. Brianna Gaines

INVOICE

14442

DATE

03/19/26



The information and recommendations provided are based on the images presented by the referring veterinarian/sonographer. No evaluation can be communicated regarding pathology that was not visible in the image/video clips provided.

Thank you for this referral. If the clinical or image interpretation does not parallel your findings or if I can be of any further assistance, please contact me.

Eric Lindquist, DMV, DABVP(CFM), Cert. IVUSS,

CEO, Owner, Founder -- SonoPath.com

info@SonoPath.com