SonoPath
Clinical Sonography & Telecytology

EDUCATIONAL TELECONSULTATION SERVICES™

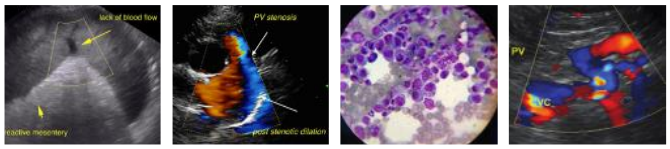

SonoPath.com
1-800-838-4268 info@sonopath.com

PATIENT

Ruby Detrick

SPECIES

Canine

BREED

West Highland Terrier

SEX

Spayed Female

AGE

8 Years

WEIGHT

16 Pounds

INTERPRETED BY

Eric Lindquist, DMV
DABVP, Cert. IVUSS

IMAGING PERFORMED BY

Griffin

HOSPITAL NAME

Northside VC

REFERRING VET

Dr. Griffin

INVOICE

14381

DATE

3/19/22

PRESENTING CLINICAL SIGNS

History: Intermittent vomiting and lethargy

Abnormal PE/Chem/CBC/UA Results: CBC: WNL except Neu 14.42, Lymh 0.89 Chem: Amy low 329 CPL: WNL Rads: Thickened stomach with increase soft tissue opacity in the pylorus

ULTRASONOGRAPHIC EXAMINATION OF THE ABDOMEN

Urinary System

The **urinary bladder**, trigone, and pelvic urethra presented normal thicknesses and normal tone. The ureters were not visible which is normal. No uroliths or sediment were visualized, and anechoic urine was present. No evidence of inflammatory or neoplastic changes were noted. Ureteral papillae were normal. The pelvic urethra was imaged 1.0 cm beyond the cystourethral junction.

The **kidneys** revealed normal size and structure, corticomedullary definition and ratio for this age. The cortices presented largely uniform texture with normal echogenic relationship to liver and spleen. Medullary structure differed distinctly from the cortex and no evidence of pelvic dilation was present. The capsules were acceptably uniform without significant irregularities. The right kidney measured 4.0 cm. The left kidney measured 4.4 cm.

Adrenal Glands

Both **adrenal glands** were visualized and recognized as having normal shape, size, position and echogenicity for this breed. The phrenic vasculature, glandular echogenicity and detail were unremarkable. Capsule, cortex, and medullary definition were normal for this age patient. The right adrenal gland measured 1.0 cm at the cranial pole and 0.8 cm at the caudal pole. The left adrenal gland measured 0.7 cm at maximum width.

Spleen

The **spleen** revealed a focal hypoechoic nodule at the mid caudal body, measuring 9.0 mm. Loss of structural detail was noted with capsular expansion.

Liver

The **liver** images submitted revealed subjectively normal liver size, contour, and structure. Parenchymal echogenicity was naturally coarse and hypoechoic to the spleen. Vascular and biliary tracts were of normal volume with no evidence of congestion. The gallbladder presented acceptably thin walls with primarily anechoic content. The cystic and common bile ducts were normal. No pathological hepatic lymphadenopathy was evident. No overt structural evidence of inflammatory, infiltrative or regenerative pathology was evident.

Gastrointestinal

The **gastric** wall was mildly thickened with shadowing foreign bodies. Two separate foreign bodies appear to be present. One structure measured 1.2 cm. The second structure measures 2.6 cm. Gastritis pattern noted with edematous gastric wall. The small intestine and colon were unremarkable.

Pancreas

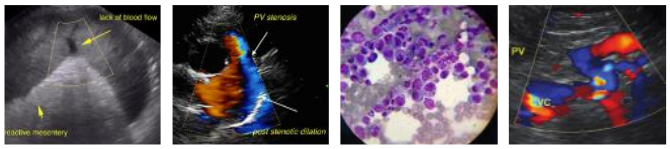

SonoPath.com
1-800-838-4268 info@sonopath.com

PATIENT

Ruby Detrick

SPECIES

Canine

BREED

West Highland Terrier

SEX

Spayed Female

AGE

8 Years

WEIGHT

16 Pounds

INTERPRETED BY

Eric Lindquist, DMV
DABVP, Cert. IVUSS

IMAGING PERFORMED BY

Griffin

HOSPITAL NAME

Northside VC

REFERRING VET

Dr. Griffin

INVOICE

14381

DATE

3/19/22

The base and limbs of the **pancreas** were observed to be largely isoechoic to surrounding omental fat. Pancreatic duct and capsular contour were acceptably normal and parenchyma respected normal curvilinear patterns. No overt evidence of active inflammatory or neoplastic disease was noted.

ULTRASONOGRAPHIC FINDINGS

- Gastritis with shadowing foreign matter, nonobstructive
- Concurrent splenic nodule, concerning for round cell neoplasia, emerging hemangiosarcoma or hyperplasia

INTERPRETATION OF THE FINDINGS & FURTHER RECOMMENDATIONS

The foreign matter may be able to be evacuated with induction of vomiting. FNA of the splenic nodule warranted. If surgery is to be performed for gastrotomy, then gastric biopsies, evacuation of the stomach and splenectomy all indicated.

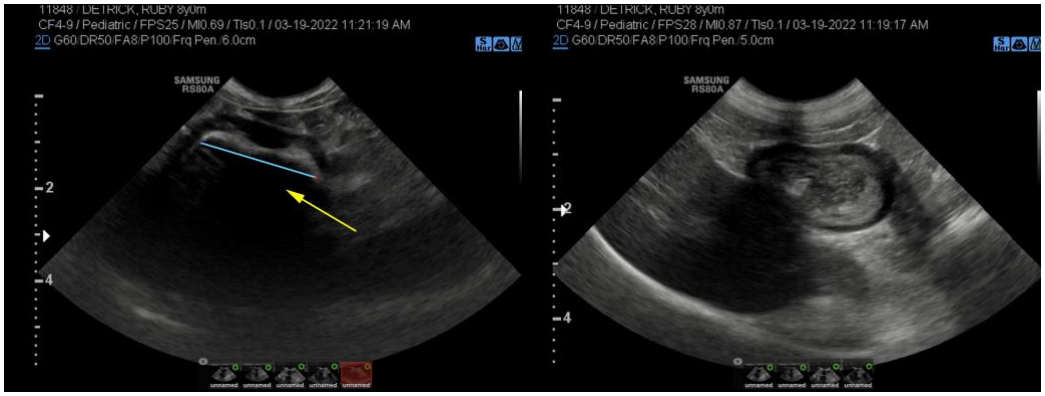

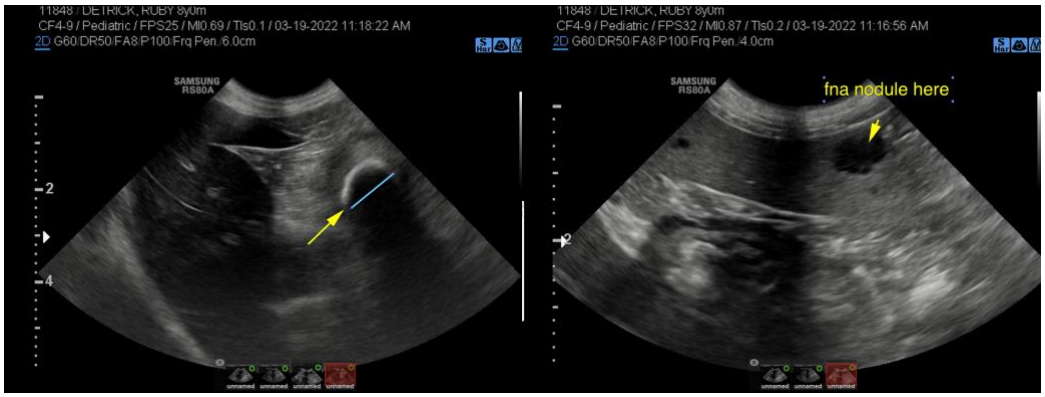

SonoPath

Clinical Sonography & Telecytology

EDUCATIONAL TELECONSULTATION SERVICES™

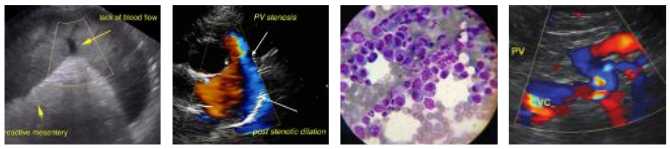

SonoPath.com™
1-800-838-4268 info@sonopath.com

PATIENT

Ruby Detrick

SPECIES

Canine

BREED

West Highland Terrier

SEX

Spayed Female

AGE

8 Years

WEIGHT

16 Pounds

INTERPRETED BY

Eric Lindquist, DMV
DABVP, Cert. IVUSS

IMAGING PERFORMED BY

Griffin

HOSPITAL NAME

Northside VC

REFERRING VET

Dr. Griffin

INVOICE

14381

DATE

3/19/22

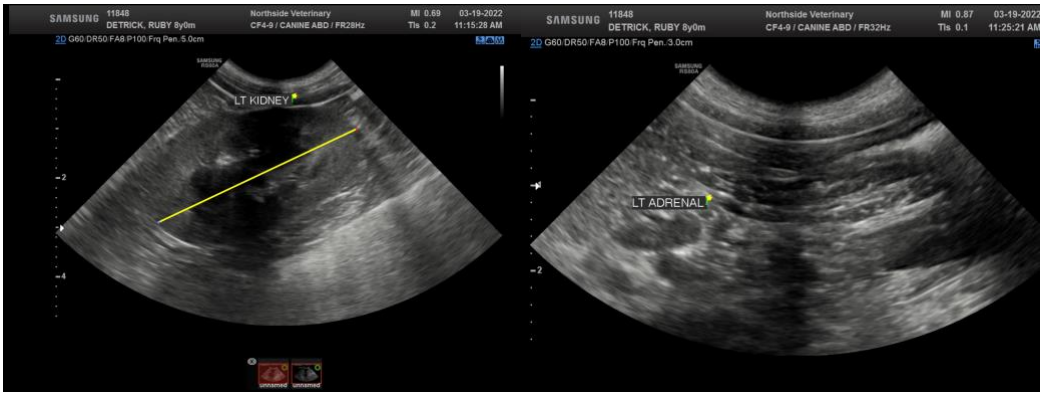

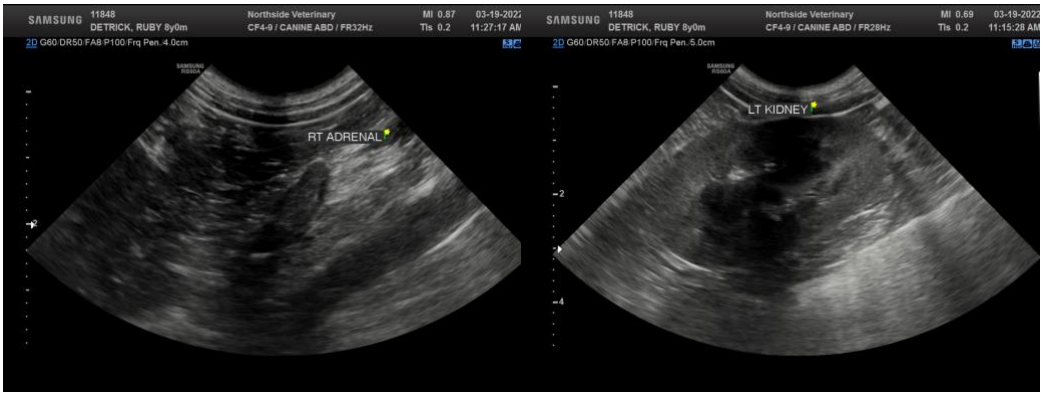

The information and recommendations provided are based on the images presented by the referring veterinarian. No evaluation can be communicated regarding pathology that was not visible in the image/video clips provided.

Thank you for this referral. If the clinical or image interpretation does not parallel your findings or if I can be of any further assistance please contact me.

Eric Lindquist, DMV, DABVP, Cert. IVUSS, CEO of SonoPath.com
info@SonoPath.com