



## PATIENT

Tux Bruni

## SPECIES

Canine

## BREED

Chihuahua

## SEX

Neutered Male

## AGE

5 Years

## WEIGHT

9.6 pounds

## INTERPRETED BY

Eric Lindquist, DMV,  
DABVP(CFM), Cert.  
IVUSS

## IMAGING PERFORMED BY

Dr. Kyoung Han

## HOSPITAL NAME

Tenafly Vet Center

## REFERRING VET

Dr. Kyoung Han

## INVOICE

14435

## DATE

03/18/26

## PRESENTING CLINICAL SIGNS

- 5 yr old Chihuahua. Had liver enzyme elevation (alp). he had on and off soft stool issue and very anxious before. since the owner put him on turkey meat and sweet potato, his clinical symptoms got improved. the reason for abdominal ultrasound is to check his liver and gastrointestinal issue

## ULTRASONOGRAPHIC EXAMINATION OF THE ABDOMEN

### *Urinary System*

The **urinary bladder**, trigone, and pelvic urethra to a depth of 2.0 cm presented normal thicknesses and normal tone. The ureters were not visible which is normal. No uroliths or sediment were visualized, and anechoic urine was present. No evidence of inflammatory or neoplastic changes were noted. Ureteral papillae were normal.

The **kidneys** revealed normal size and structure, corticomedullary definition and ratio for this age. The cortices presented largely uniform texture with normal echogenic relationship to liver and spleen. Medullary structure differed distinctly from the cortex. Slight pinpoint mineralizations were noted. The capsules were acceptably uniform without significant irregularities. The left kidney measured 3.6 cm in length. The right kidney measured 3.2 cm in length.

### *Adrenal Glands*

Both **adrenal glands** were visualized and recognized as having normal shape, size, position and echogenicity for this breed. The phrenic vasculature, glandular echogenicity and detail were unremarkable. Capsule, cortex, and medullary definition were normal for this age patient. The left adrenal gland measured 0.50 cm width. The right adrenal gland measured 0.50 cm width.

### *Spleen*

The **spleen** presented a smooth homogeneous parenchyma hyperechoic to liver and renal cortical parenchyma. The capsule was smooth without noticeable expansion or deviation from within the spleen or adjacent pathology. The splenic vasculature demonstrated normal volume without signs of congestion or thrombosis. No sonographic evidence of acute or chronic inflammatory, neoplastic, or infarctual changes were noted.

### *Liver*

The **liver** images submitted revealed subjectively normal liver size, contour, and structure. Parenchymal echogenicity was naturally coarse and hypoechoic to the spleen. Vascular and biliary tracts were of normal volume with no evidence of congestion. The gallbladder presented acceptably thin walls with primarily anechoic content. The cystic and common bile ducts were normal. No pathological hepatic lymphadenopathy was evident. No overt structural evidence of inflammatory, infiltrative or regenerative pathology was evident.

### *Gastrointestinal*

Examination of the **gastrointestinal tract** revealed a stomach and intestine free of stasis, of normal wall thickness, acceptable curvilinear mural detail, and peristaltic activity. Small and large intestine demonstrated normal luminal chyme and stool consistency respectively. No obstructive or overt infiltrative disease was noted. No associated abnormal lymphatic activity was noted.



**PATIENT**

*Pancreas*

Tux Bruni

The base and limbs of the **pancreas** were observed to be largely isoechoic to surrounding omental fat. Pancreatic duct and capsular contour were acceptably normal and parenchyma respected normal curvilinear patterns. No overt evidence of active inflammatory or neoplastic disease was noted.

**SPECIES**

Canine

**ULTRASONOGRAPHIC FINDINGS**

**BREED**

Chihuahua

- Unremarkable abdomen.
- Slight pinpoint renal mineralizations.
- Normal liver.

**SEX**

**INTERPRETATION OF THE FINDINGS & FURTHER RECOMMENDATIONS**

Neutered Male

FNA could be considered for further definition yet there is no evidence of significant disease.

**AGE**

5 Years

**WEIGHT**

9.6 pounds

**INTERPRETED BY**

Eric Lindquist, DMV,  
DABVP(CFM), Cert.  
IVUSS

**IMAGING PERFORMED BY**

Dr. Kyoung Han

**HOSPITAL NAME**

Tenafly Vet Center

**REFERRING VET**

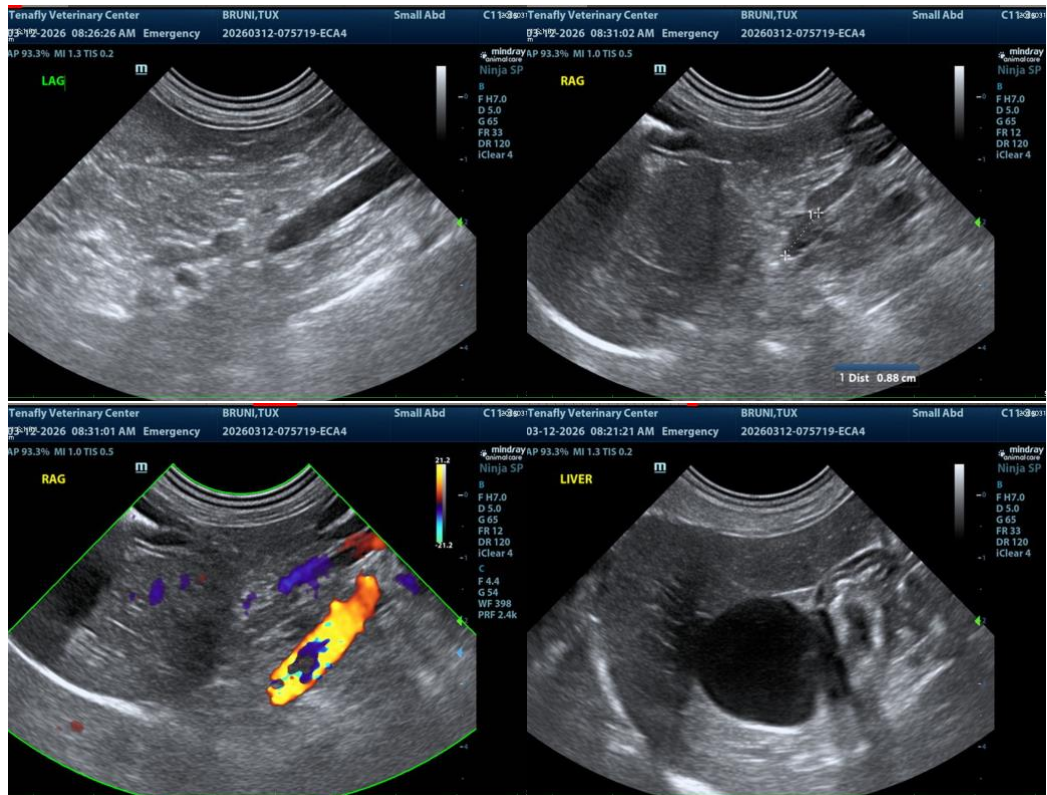
Dr. Kyoung Han

**INVOICE**

14435

**DATE**

03/18/26





## PATIENT

Tux Bruni

## SPECIES

Canine

## BREED

Chihuahua

## SEX

Neutered Male

## AGE

5 Years

## WEIGHT

9.6 pounds

## INTERPRETED BY

Eric Lindquist, DMV,  
DABVP(CFM), Cert.  
IVUSS

## IMAGING PERFORMED BY

Dr. Kyoung Han

## HOSPITAL NAME

Tenafly Vet Center

## REFERRING VET

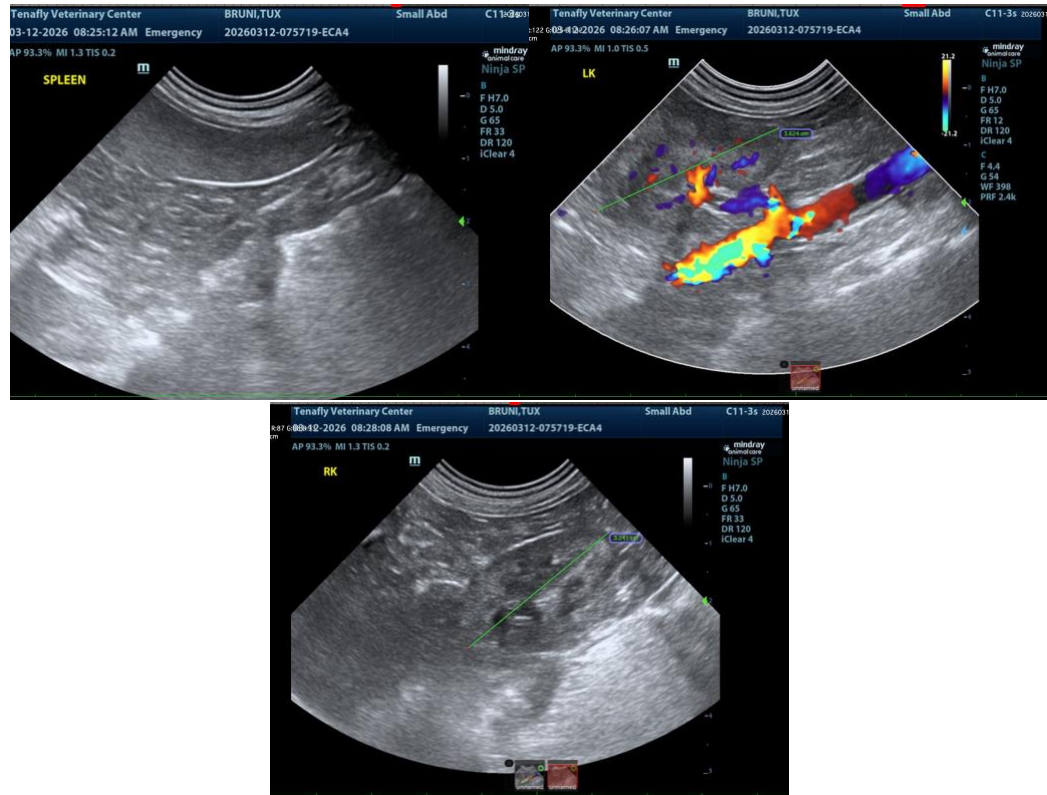
Dr. Kyoung Han

## INVOICE

14435

## DATE

03/18/26



The information and recommendations provided are based on the images presented by the referring veterinarian/sonographer. No evaluation can be communicated regarding pathology that was not visible in the image/video clips provided.

Thank you for this referral. If the clinical or image interpretation does not parallel your findings or if I can be of any further assistance, please contact me.

**Eric Lindquist, DMV, DABVP(CFM), Cert. IVUSS,**

CEO, Owner, Founder -- SonoPath.com

[info@SonoPath.com](mailto:info@SonoPath.com)