



PATIENT

Kitana East

SPECIES

Canine

BREED

Labrador

SEX

Spayed Female

AGE

5 Years 11 Months

WEIGHT

110 pounds

INTERPRETED BY

Eric Lindquist, DMV,
DABVP(CFM), Cert.
IVUSS

IMAGING PERFORMED BY

Ashley Whitesell

HOSPITAL NAME

Dickson Animal Clinic

REFERRING VET

Dr. Kristen Levine

INVOICE

14425

DATE

03/18/26

PRESENTING CLINICAL SIGNS

- Medications: Gabapentin and Trazodone this AM, Dasuquin SID
- Bloodwork WNL
- Radiographs suspect mass - attached for reference

ULTRASONOGRAPHIC EXAMINATION OF THE ABDOMEN

Urinary System

The **urinary bladder**, trigone, and pelvic urethra to a depth of 2.0 cm presented normal thicknesses and normal tone. The ureters were not visible which is normal. No uroliths or sediment were visualized, and anechoic urine was present. No evidence of inflammatory or neoplastic changes were noted. Ureteral papillae were normal.

The **kidneys** revealed normal size and structure, corticomedullary definition and ratio for this age. The cortices presented largely uniform texture with normal echogenic relationship to liver and spleen. Medullary structure differed distinctly from the cortex and no evidence of pelvic dilation was present. The capsules were acceptably uniform without significant irregularities. The left kidney measured 7.0 cm in length. The right kidney measured 7.5 cm in length.

Adrenal Glands

Both **adrenal glands** were visualized obliquely and recognized as having normal shape, size, position and echogenicity for this breed. The phrenic vasculature, glandular echogenicity and detail were unremarkable. Capsule, cortex, and medullary definition were normal for this age patient. The left adrenal gland measured 0.50 cm width. The right adrenal gland measured 0.50 cm width.

Spleen

The **spleen** was folded upon itself.

Liver

The **liver** images submitted revealed subjectively normal liver size, contour, and structure. Parenchymal echogenicity was naturally coarse and hypoechoic to the spleen. Vascular and biliary tracts were of normal volume with no evidence of congestion. The gallbladder presented acceptably thin walls with primarily anechoic content. The cystic and common bile ducts were normal. No pathological hepatic lymphadenopathy was evident. No overt structural evidence of inflammatory, infiltrative or regenerative pathology was evident.

Gastrointestinal

Examination of the **gastrointestinal tract** revealed a stomach and intestine free of stasis, of normal wall thickness, acceptable curvilinear mural detail, and peristaltic activity. Small and large intestine demonstrated normal luminal chyme and stool consistency respectively. No obstructive or overt infiltrative disease was noted. No associated abnormal lymphatic activity was noted.

Pancreas



PATIENT

Kitana East

SPECIES

Canine

BREED

Labrador

SEX

Spayed Female

AGE

5 Years 11 Months

WEIGHT

110 pounds

INTERPRETED BY

Eric Lindquist, DMV,
DABVP(CFM), Cert.
IVUSS

IMAGING PERFORMED BY

Ashley Whitesell

HOSPITAL NAME

Dickson Animal Clinic

REFERRING VET

Dr. Kristen Levine

INVOICE

14425

DATE

03/18/26

The base and limbs of the **pancreas** were observed to be largely isoechoic to surrounding omental fat. Pancreatic duct and capsular contour were acceptably normal and parenchyma respected normal curvilinear patterns. No overt evidence of active inflammatory or neoplastic disease was noted.

Free Abdomen

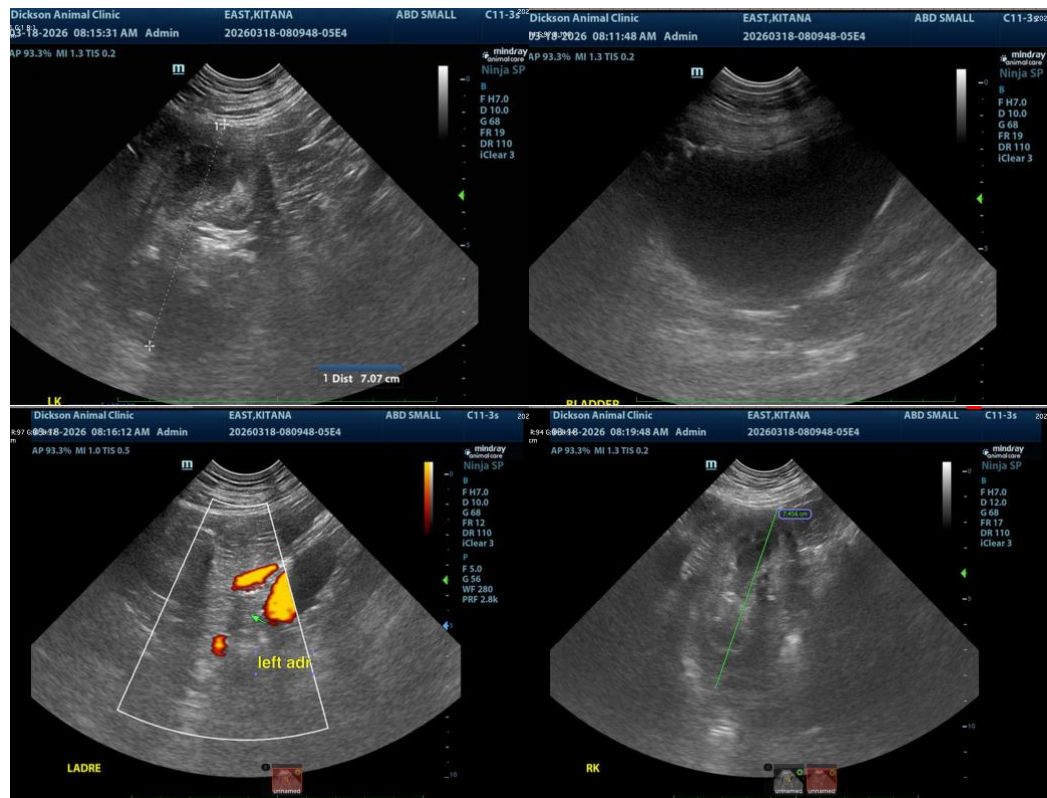
Radiographs revealed pyloric gas and a normal thorax.

ULTRASONOGRAPHIC FINDINGS

- Structurally unremarkable abdomen.

INTERPRETATION OF THE FINDINGS & FURTHER RECOMMENDATIONS

No evidence of masses or pathology.





PATIENT

Kitana East

SPECIES

Canine

BREED

Labrador

SEX

Spayed Female

AGE

5 Years 11 Months

WEIGHT

110 pounds

INTERPRETED BY

Eric Lindquist, DMV,
DABVP(CFM), Cert.
IVUSS

IMAGING PERFORMED BY

Ashley Whitesell

HOSPITAL NAME

Dickson Animal Clinic

REFERRING VET

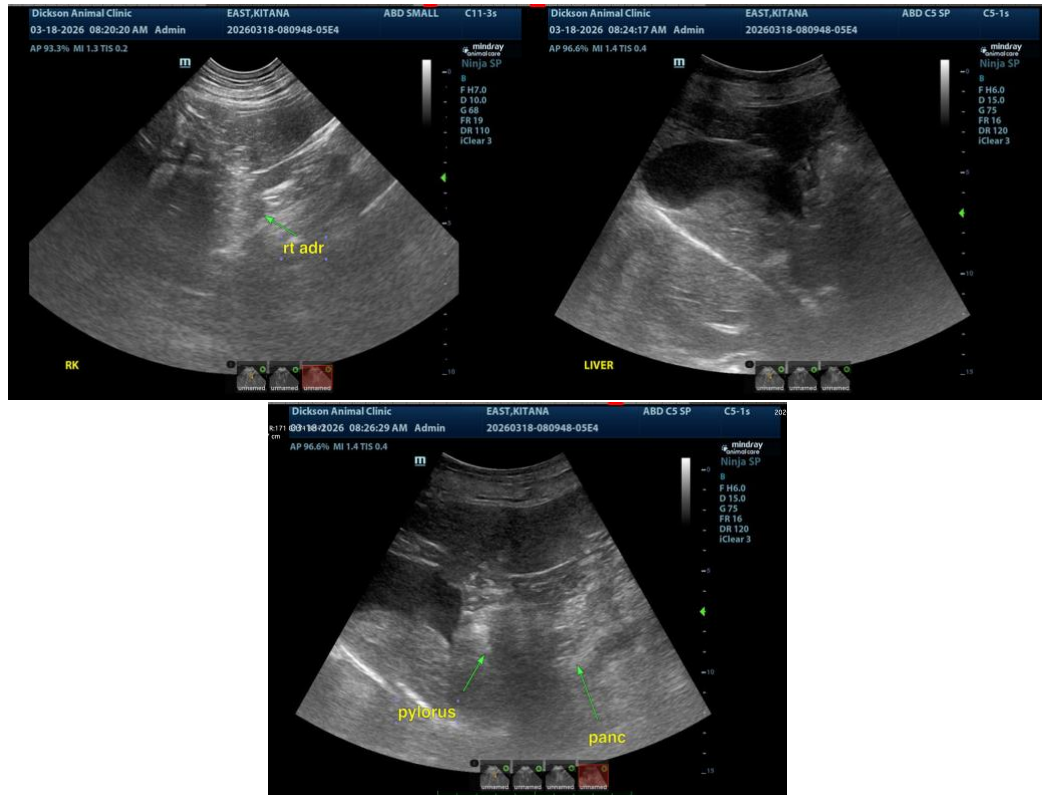
Dr. Kristen Levine

INVOICE

14425

DATE

03/18/26



The information and recommendations provided are based on the images presented by the referring veterinarian/sonographer. No evaluation can be communicated regarding pathology that was not visible in the image/video clips provided.

Thank you for this referral. If the clinical or image interpretation does not parallel your findings or if I can be of any further assistance, please contact me.

Eric Lindquist, DMV, DABVP(CFM), Cert. IVUSS,

CEO, Owner, Founder -- SonoPath.com

info@SonoPath.com