



PATIENT

Jake Bowman

SPECIES

Canine

BREED

Labrador Retriever

SEX

Neutered Male

AGE

9 Years 2 Months

WEIGHT

100 lbs

INTERPRETED BY

Eric Lindquist, DMV,
DABVP (CFM), Cert.
IVUSS

IMAGING PERFORMED BY

Dr. Ken Leal

HOSPITAL NAME

Sova Animal Hospital

REFERRING VET

Dr. Ammeraal

INVOICE

73777

DATE

3/18/26

PRESENTING CLINICAL SIGNS

VPC's on ECG. History of epistaxis. Thoracic radiographs - normal

Medications: Gabapentin/Trazodone for echo

Abnormal PE/Chem/CBC/UA Results: Bloodwork ANL

ULTRASONOGRAPHIC EXAMINATION OF THE HEART & ABDOMEN

CANINE CARDIAC PARAMETERS	MR VMAX (m/s)	TR VMAX (m/s)	LA/AO (M-Mode)	LA/AO (Heart Base; Swe)	FS (%)	EF (%)	EPSS (cm)
NORMAL PARAMETER	4.5-5.5	<2.7	1.3	Up to 1.6	28-40	40-100	<0.6
PATIENT	--	--	1.3	1.3	24	48	NM
CANINE CARDIAC PARAMETERS	HR (BPM)	AV VMAX (m/s)	PV MAX (m/s)	BODY WEIGHT (lbs)	LAD LA MAX 4 Chamber	LVIDd Avg; 2D and m-mode short axis (cm)	LVIDs Avg; 2D and m-mode short axis (cm)
NORMAL PARAMETER	50-100	0.7-1.7	0.7-1.6				
PATIENT	134	1.6	1.3	100	4.0	3.24	--

Cardiac Presentation

The echocardiogram in this patient demonstrated normal **left atrial** size based on 3 different LA measurement methods. Chamber volumes and echogenicity were normal. The cranial and caudal **mitral** valve leaflets presented vegetative thickening consistent with endocardiosis. Doppler indicated mild, centralized mitral insufficiency. The **left ventricle** presented thicknesses with linear contour and was not dilated nor restricted. The **myocardium** presented normal echogenicity without subjective evidence of significant fibrotic or ischemic disease. **Contractility** of the ventricular walls was adequate and in normal range for this patient evidenced by the fractional shortening measurement and subjective evaluation of the different regions of the myocardium. The **left ventricular outflow** tract demonstrated normal laminar flow and subjective structural integrity. The **right atrium** and auricle revealed normal size, structure and content. No evidence of masses was noted or chamber overload. **Tricuspid** valvular assessment demonstrated adequate linear morphology. The **right ventricle** was of normal size (1/3 diameter of LV), chordae structure, myocardial echogenicity and thickness. **Pulmonic** tract assessment revealed normal valve structure, laminar flow, and diameter (approx. 1:1 pa/ao ratio). No visible **pericardial** or free pleura fluid was noted. No echographically detectable evidence of infiltrative disease was visible. The cranial **mediastinum** and **pericardial** regions were free of masses in the visible window.



PATIENT

Jake Bowman

SPECIES

Canine

BREED

Labrador Retriever

SEX

Neutered Male

AGE

9 Years 2 Months

WEIGHT

100 lbs

INTERPRETED BY

Eric Lindquist, DMV,
DABVP (CFM), Cert.
IVUSS

IMAGING PERFORMED BY

Dr. Ken Leal

HOSPITAL NAME

Sova Animal Hospital

REFERRING VET

Dr. Ammeraal

INVOICE

73777

DATE

3/18/26

Urinary System

The **urinary bladder**, trigone, and pelvic urethra presented normal thicknesses and normal tone. The ureters were not visible which is normal. No uroliths or sediment were visualized and anechoic urine was present. No evidence of inflammatory or neoplastic changes were noted. Ureteral papillae were normal.

The residual prostate measured 1.45 cm.

The **right kidney** was mildly irregular with some loss of corticomedullary definition. Right kidney measured 7.3 cm.

The **left kidney** was mildly enlarged, with pyelectasia and irregular contour. Left kidney measured 8.65 cm. This may represent a mild form of primary renal dysplasia.

Adrenal Glands

The **adrenal glands** appeared slightly enlarged and swollen. No evidence of focal capsular expansion or invasion into the phrenic veins were noted. No overt suspicion of neoplasia was noted. This is considered likely a hyperplastic change associated with stress or adrenal endocrinopathy (PDH). If isosthenuria is persistently present and the patient morphologically suggests Cushing's disease then ACTH testing would be indicated. Right measured 2.84 cm x 1.77 cm at the cranial pole and 1.04 cm at the caudal pole. Left measured 3.36 cm x 1.0 cm at the cranial pole and 1.03 cm at the caudal pole.

Spleen

The **spleen** presented a smooth homogeneous parenchyma hyperechoic to liver and renal cortical parenchyma. The capsule was smooth without noticeable expansion or deviation from within the spleen or adjacent pathology. The splenic vasculature demonstrated normal volume without signs of congestion or thrombosis. No sonographic evidence of acute or chronic inflammatory, neoplastic, or infarctual changes were noted.

Liver

The **liver** images submitted revealed subjectively normal liver size, contour, and structure. Parenchymal echogenicity was naturally coarse and hypoechoic to the spleen. Vascular and biliary tracts were of normal volume with no evidence of congestion. The gallbladder presented acceptably thin walls with primarily anechoic content. The cystic and common bile ducts were normal. No pathological hepatic lymphadenopathy was evident. No overt structural evidence of inflammatory, infiltrative or regenerative pathology was evident.

Gastrointestinal

Examination of the **gastrointestinal tract** revealed a stomach and intestine free of stasis, of normal wall thickness, acceptable curvilinear mural detail, and peristaltic activity. Small and large intestine demonstrated normal luminal chyme and stool consistency respectively. No obstructive or overt infiltrative disease was noted. No associated abnormal lymphatic activity was noted.

Pancreas

The base and limbs of the **pancreas** were observed to be largely isoechoic to surrounding omental fat. Pancreatic duct and capsular contour were acceptably normal and parenchyma respected normal curvilinear patterns. No overt evidence of active inflammatory or neoplastic disease was noted.



PATIENT

Jake Bowman

SPECIES

Canine

BREED

Labrador Retriever

SEX

Neutered Male

AGE

9 Years 2 Months

WEIGHT

100 lbs

INTERPRETED BY

Eric Lindquist, DMV,
DABVP (CFM), Cert.
IVUSS

IMAGING PERFORMED BY

Dr. Ken Leal

HOSPITAL NAME

Sova Animal Hospital

REFERRING VET

Dr. Ammeraal

INVOICE

73777

DATE

3/18/26

ULTRASONOGRAPHIC FINDINGS

- Stage B1 valvular disease.
- Slightly enlarged, irregular left kidney.
- Moderate chronic right kidney changes.
- Bilateral adrenal hypertrophy.

INTERPRETATION OF THE FINDINGS & FURTHER RECOMMENDATIONS

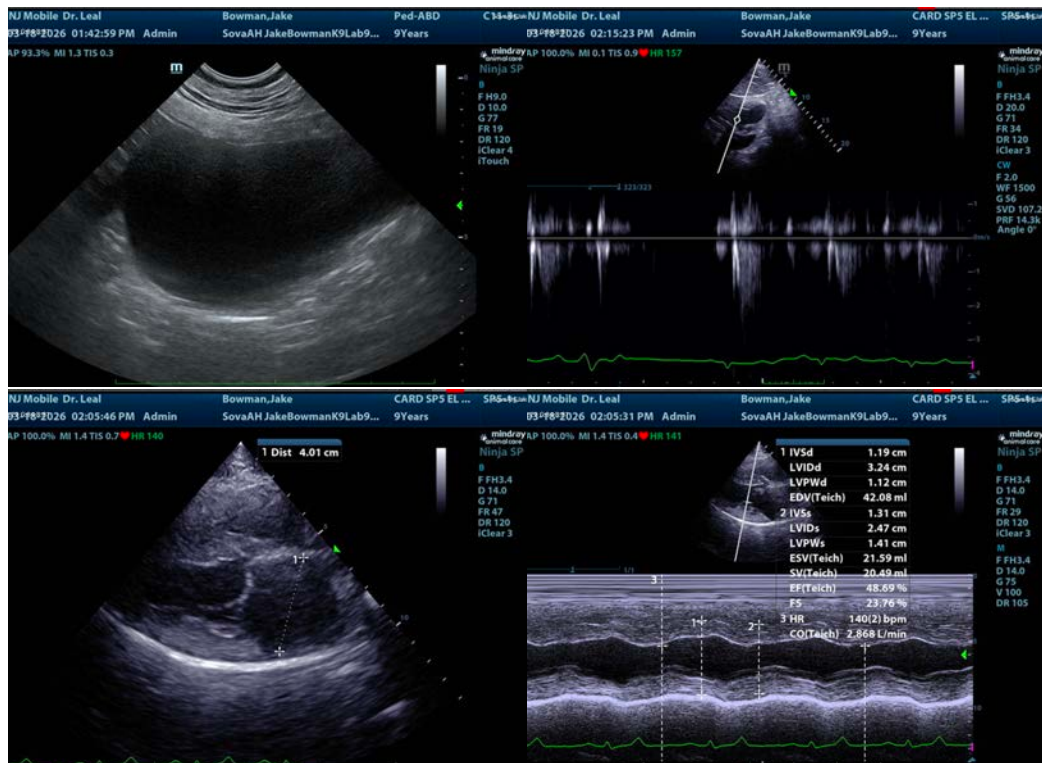
The heart is stable without clinical disease. No overt contraindication for anesthesia of brief to moderate duration. I suggest Torbutrol premed, Propofol induction, Isoflo maintenance or similar protocol if anesthesia is desired. Blood pressure, EKG and chest radiographs are recommended if not already performed. Target white coat negative systolic pressure of < 160 mmHg. If higher than this ACE-inhibitor is suggested to reach this level. Recheck echocardiogram is recommended in 6 months, earlier if murmur grade increases or clinical signs initiate.

No evidence of abdominal or cardiac disease directly related to the epistaxis. Skull CT may be appropriate for further definition. Blood pressure measurements indicated.

Ful urinary workup warranted to assess any functional deficit or UTI associated with the renal presentation, given the pyelectasia primarily in the left kidney. Possible mild form of renal dysplasia.

SonoPath CT Services are offered at the SonoPath Imaging and Veterinary Education Center, 141 Main St (rt 206), Andover, New Jersey, a 20-minute drive west on route 80/206 North from the route 80/287 interchange/Parsippany, New Jersey. More information can be found at

<https://sonopath.com/services/vetimaging/>





PATIENT

Jake Bowman

SPECIES

Canine

BREED

Labrador Retriever

SEX

Neutered Male

AGE

9 Years 2 Months

WEIGHT

100 lbs

INTERPRETED BY

Eric Lindquist, DMV,
DABVP (CFM), Cert.
IVUSS

IMAGING PERFORMED BY

Dr. Ken Leal

HOSPITAL NAME

Sova Animal Hospital

REFERRING VET

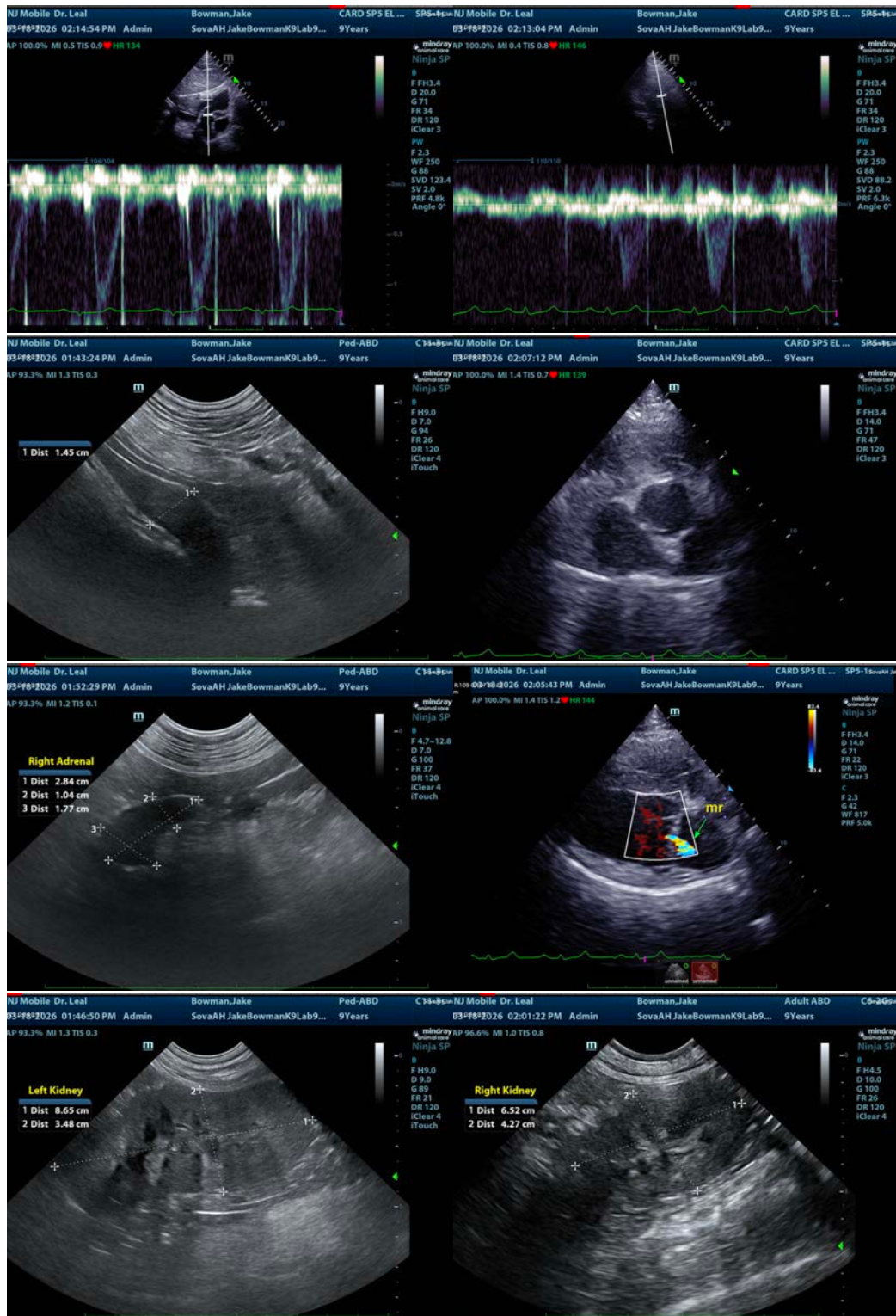
Dr. Ammeraal

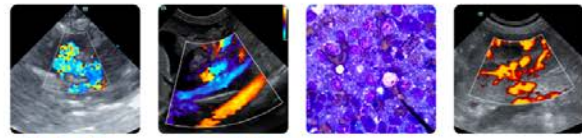
INVOICE

73777

DATE

3/18/26





PATIENT

Jake Bowman

SPECIES

Canine

BREED

Labrador Retriever

SEX

Neutered Male

AGE

9 Years 2 Months

WEIGHT

100 lbs

INTERPRETED BY

Eric Lindquist, DMV,
DABVP (CFM), Cert. IVUSS

IMAGING PERFORMED BY

Dr. Ken Leal

HOSPITAL NAME

Sova Animal Hospital

REFERRING VET

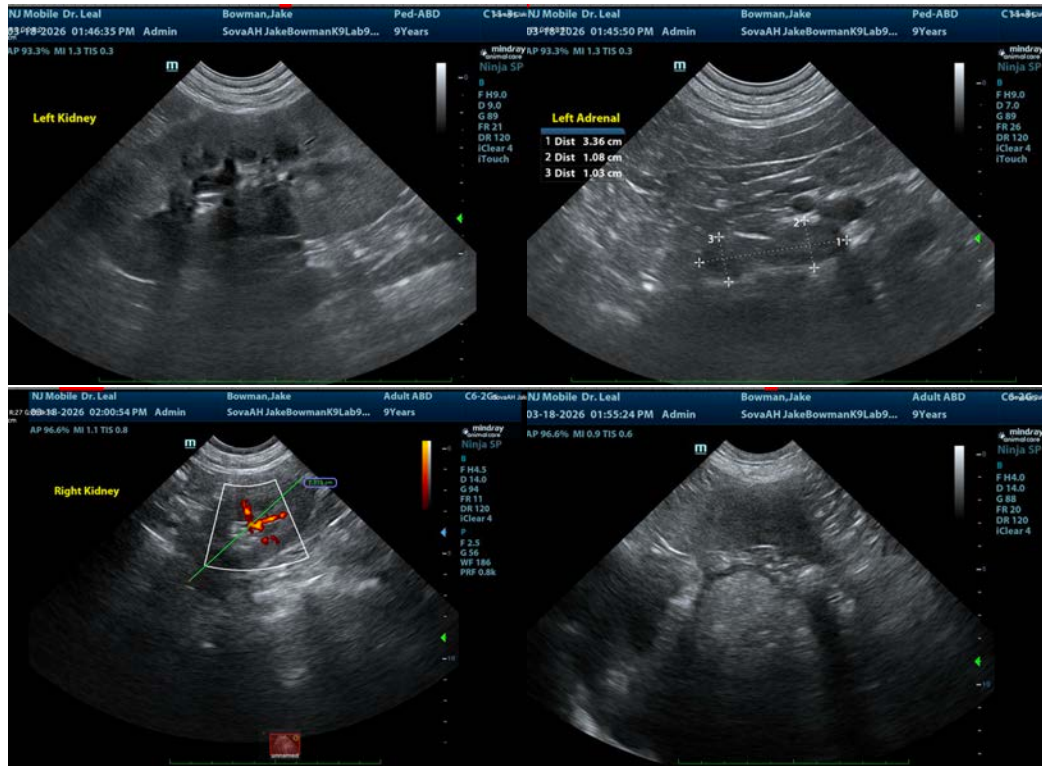
Dr. Ammeraal

INVOICE

73777

DATE

3/18/26



The information and recommendations provided are based on the images presented by the referring veterinarian/sonographer. No evaluation can be communicated regarding pathology that was not visible in the image/video clips provided.

Thank you for this referral. If the clinical or image interpretation does not parallel your findings or if I can be of any further assistance please contact me.

Eric Lindquist, DMV, DABVP(CFM), Cert. IVUSS,
CEO, Owner, Founder -- SonoPath.com
info@SonoPath.com