



PATIENT

Gabriel Cunningham

SPECIES

Feline

BREED

DSH

SEX

Neutered Male

AGE

12 Years

WEIGHT

13.8 lbs

INTERPRETED BY

Eric Lindquist, DMV,
DABVP (CFM), Cert.
IVUSS

IMAGING PERFORMED BY

Chloe Lowe, CVT

HOSPITAL NAME

Harmony Animal
Hospital

REFERRING VET

Dr. Eppler

INVOICE

73775

DATE

3/18/26

PRESENTING CLINICAL SIGNS

Episodes of labored breath. History of diabetes. One hypoglycemic crisis. No murmurs, normal rhythm. Lungs unremarkable. Lantis insulin, famotidine, mirtazapine, enrofloxacin

Abnormal PE/Chem/CBC/UA Results: Urine normal sediment USG 1.041 pro BNP abnormal, WBC 20 K, neutrophils 17, hypoglycemia on presentation.

ULTRASONOGRAPHIC EXAMINATION OF THE HEART

FELINE CARDIAC PARAMETERS	BODY WEIGHT (lbs)	HR (BPM)	IVSd (cm)	LVIDd (cm)	LVWd (cm)	FS (%)	EF (%)
NORMAL PARAMETER	-----	150-240	0.3-0.6	1.0-2.1	0.25-0.6	35-67	80-100
PATIENT	13.8	NM	0.6	1.5	0.7	45	85
FELINE CARDIAC PARAMETERS	LA/AO (M-mode)	LA/AO HEART BASE (Sisson)	LAD LA MAX 4 Chamber		LVOT VEL. (m/s)	RVOT VEL. (m/s)	IVRT (m/)
NORMAL PARAMETER	<1.5	1.6	0.7-1.7		<1.6	<1.3	40-60
PATIENT	2.0	2.0	2.1		1.4	0.9	NM
Adapted from June Boon, Veterinary Echocardiography, 1998 Sisson D et al. JVIM 1991; 5: 232, Jacobs et al. Am J Vet Res 1985; 46:1705							

EPSS = 0.1

Cardiac Presentation

The cardiac presentation presented volume overload both in the left and right heart with concentric hypertrophy of the left ventricle and hypercontractility. Mitral and tricuspid insufficiency noted. Slight pericardial effusion noted. Slight pleural effusion noted. Comet tail lung pattern noted. Hepatic veins were not dilated.

ULTRASONOGRAPHIC FINDINGS

- Left-sided heart failure owing to hypertrophic cardiomyopathy phenotype.

INTERPRETATION OF THE FINDINGS & FURTHER RECOMMENDATIONS

Lasix therapy indicated at 12.5 mg BID, and Plavix therapy. ACE inhibitor could be considered at 0.5 mg/kg SID. Recheck echocardiogram in 2 weeks. Blood pressure measurements and thyroid assessment warranted if not already performed. Abdominal sonogram recommended to assess for comorbidities that may be influencing the heart given the diabetic state.



PATIENT

Gabriel Cunningham

SPECIES

Feline

BREED

DSH

SEX

Neutered Male

AGE

12 Years

WEIGHT

13.8 lbs

INTERPRETED BY

Eric Lindquist, DMV,
 DABVP (CFM), Cert.
 IVUSS

IMAGING PERFORMED BY

Chloe Lowe, CVT

HOSPITAL NAME

Harmony Animal
 Hospital

REFERRING VET

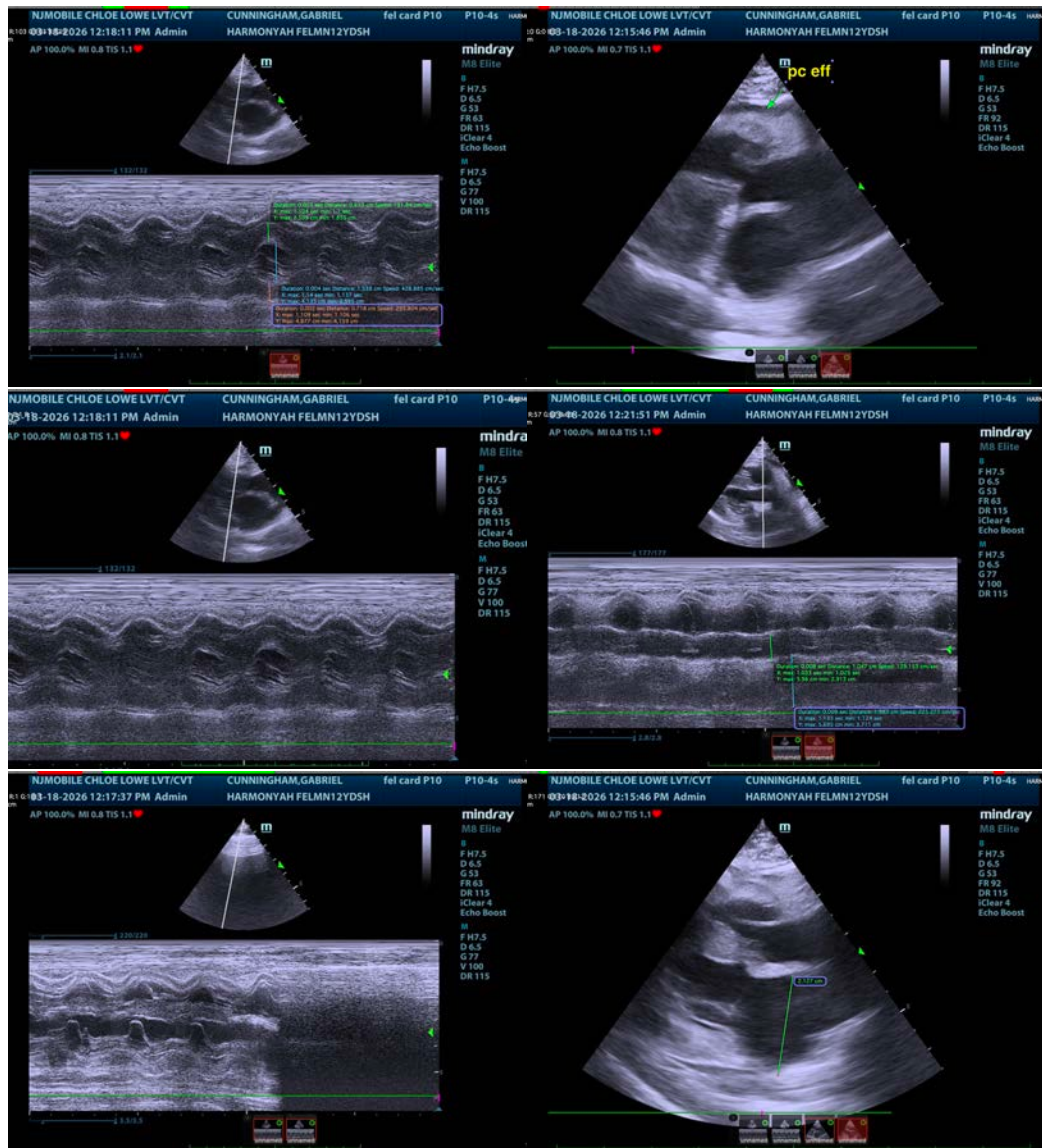
Dr. Epplé

INVOICE

73775

DATE

3/18/26



The information and recommendations provided are based on the images presented by the referring veterinarian/sonographer. No evaluation can be communicated regarding pathology that was not visible in the image/video clips provided.

Thank you for this referral. If the clinical or image interpretation does not parallel your findings or if I can be of any further assistance please contact me.

Eric Lindquist, DMV, DABVP(CFM), Cert. IVUSS,
 CEO, Owner, Founder -- SonoPath.com
info@SonoPath.com