



**PATIENT**

Rosie Farber

**SPECIES**

Feline

**BREED**

DSH

**SEX**

Spayed Female

**AGE**

13 Years 2 Months

**WEIGHT**

6.0 Pounds

**INTERPRETED BY**

Eric Lindquist, DMV  
DABVP, Cert. IVUSS

**IMAGING PERFORMED BY**

Sarah Green

**HOSPITAL NAME**

Healing Spirit AH

**REFERRING VET**

Sarah Green

**INVOICE**

14350

**DATE**

3/18/22

**PRESENTING CLINICAL SIGNS**

History: Presented due to recent lethargy and increased inspiratory effort, altered vocalization and cough. History of subdued behavior for the past month.

Abnormal PE/Chem/CBC/UA Results: Weight loss, increased inspiratory effort. no significant abnormalities on CBC, chemistry, T4. Thoracic radiographs revealed left sided pleural effusion. On aspiration fluid was hazy, serosanguinous, TS=3.9 g/dL Cytology: A 200-cell differential yielded 77% degenerate and non-degenerate neutrophils, 12% small lymphocytes, 1% eosinophils and 10% vacuolated macrophages. No organisms or overtly neoplastic cells seen

**LIMITED ULTRASONOGRAPHIC EXAMINATION**

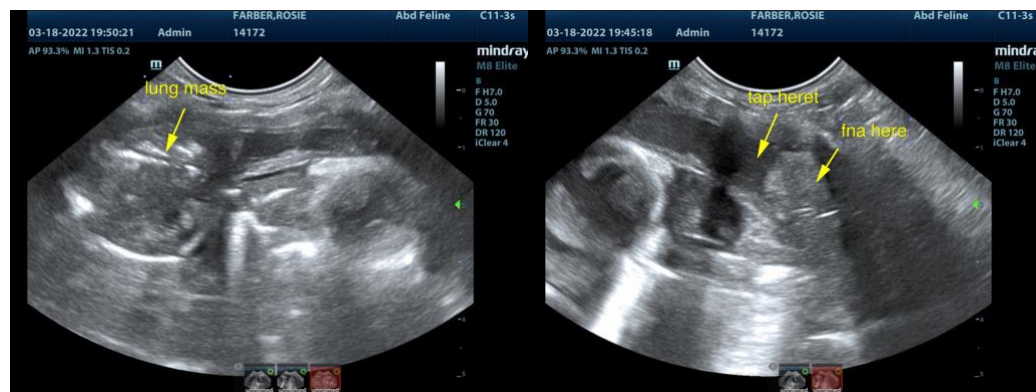
The cardiac presentation revealed volume contraction. Multifocal masses were noted in the extracardiac space, involving lung, regional lymph nodes and pleura. The pleural effusion was echogenic. No evidence of cardiac volume overload noted. LA max was approximately 9.0 mm. Contractility was approximately 35%.

**ULTRASONOGRAPHIC FINDINGS**

- Noncardiogenic pleural effusion
- Lung and undifferentiated tissue masses

**INTERPRETATION OF THE FINDINGS & FURTHER RECOMMENDATIONS**

Carcinomatosis or similar either deriving from lung tissue or metastatic disease from the abdomen suspected. FNA of the variable masses and pleurocentesis with cytospin indicated. Minor potential for lung necrosis and pleuritis.





**PATIENT**

Rosie Farber

**SPECIES**

Feline

**BREED**

DSH

**SEX**

Spayed Female

**AGE**

13 Years 2 Months

**WEIGHT**

6.0 Pounds

**INTERPRETED BY**

Eric Lindquist, DMV  
DABVP, Cert. IVUSS

**IMAGING PERFORMED BY**

Sarah Green

**HOSPITAL NAME**

Healing Spirit AH

**REFERRING VET**

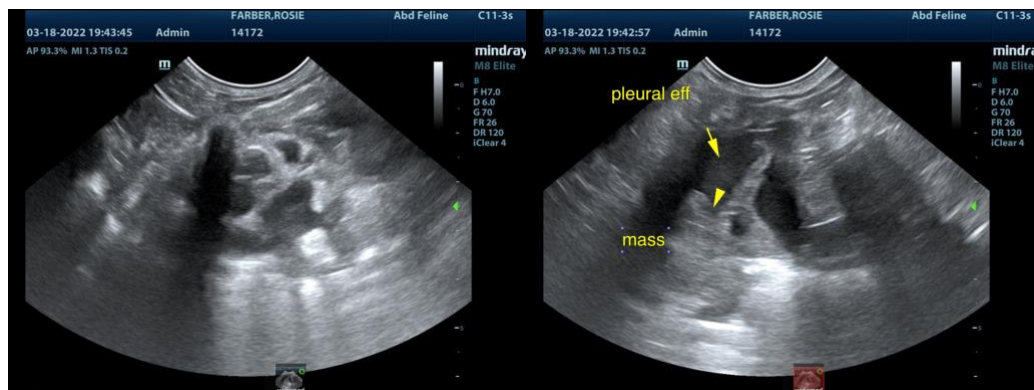
Sarah Green

**INVOICE**

14350

**DATE**

3/18/22



The information and recommendations provided are based on the images presented by the referring veterinarian. No evaluation can be communicated regarding pathology that was not visible in the image/video clips provided.

Thank you for this referral. If the clinical or image interpretation does not parallel your findings or if I can be of any further assistance please contact me.

**Eric Lindquist**, DMV, DABVP, Cert. IVUSS, CEO of SonoPath.com  
info@SonoPath.com