



PATIENT

Remy Smith

SPECIES

Feline

BREED

DSH

SEX

Spayed Female

AGE

6.5 Years

WEIGHT

7 Pounds

INTERPRETED BY

Eric Lindquist, DMV

DABVP, Cert. IVUSS

IMAGING PERFORMED BY

Dr. Meghan Myers

HOSPITAL NAME

Hershire AH

REFERRING VET

Dr. Meghan Myers

INVOICE

36321

DATE

3/18/22

PRESENTING CLINICAL SIGNS

Chronic history of vomiting. Appetite is good, possibly increased. Originally responded to hypoallergenic diet, then vomiting re-started. pet has pruritus on face and abdomen also dewormed and prednisolone trial - vomiting still occurring on low dose prednisolone (q3 days) pet has been off pred for 2 weeks prior to ultrasound

Abnormal PE/Chem/CBC/UA Results: cbc/chem/lytes: normal

ULTRASONOGRAPHIC EXAMINATION OF THE ABDOMEN

Urinary System

The **urinary bladder**, trigone, and pelvic urethra presented normal thicknesses and normal tone. The ureters were not visible which is normal. No uroliths or sediment were visualized and anechoic urine was present. No evidence of inflammatory or neoplastic changes were noted. Ureteral papillae were normal. The pelvic urethra was imaged 1.0 cm beyond the cystourethral junction.

The **kidneys** revealed normal size and structure, corticomedullary definition and ratio for this age. The cortices presented largely uniform texture with normal echogenic relationship to liver and spleen. Medullary structure differed distinctly from the cortex and no evidence of pelvic dilation was present. The capsules were acceptably uniform without significant irregularities. The kidneys measured 3.3 cm each.

Adrenal Glands

Both **adrenal glands** were visualized and recognized as having normal shape, size, position and echogenicity for this breed. The phrenic vasculature, glandular echogenicity and detail were unremarkable. Capsule, cortex, and medullary definition were normal for this age patient. The right adrenal gland measured 0.3 cm. The left adrenal gland measured 0.3 cm.

Spleen

The **spleen** presented a smooth homogeneous parenchyma hyperechoic to liver and renal cortical parenchyma. The capsule was smooth without noticeable expansion or deviation from within the spleen or adjacent pathology. The splenic vasculature demonstrated normal volume without signs of congestion or thrombosis. No sonographic evidence of acute or chronic inflammatory, neoplastic, or infarctual changes were noted.

Liver

The **liver** images submitted revealed subjectively normal liver size, contour, and structure. Parenchymal echogenicity was naturally coarse and hypoechoic to the spleen. Vascular and biliary tracts were of normal volume with no evidence of congestion. The gallbladder presented acceptably thin walls with primarily anechoic content. The cystic and common bile ducts were normal. No pathological hepatic lymphadenopathy was evident. No overt structural evidence of inflammatory, infiltrative or regenerative pathology was evident.

Gastrointestinal

Examination of the **gastrointestinal tract** revealed a stomach and intestine free of stasis, of normal wall thickness, acceptable curvilinear mural detail, and peristaltic activity. Small and large intestine demonstrated normal luminal chyme and stool consistency respectively. No obstructive or overt infiltrative disease was noted. No associated abnormal lymphatic activity was noted.



PATIENT

Remy Smith

SPECIES

Feline

BREED

DSH

SEX

Spayed Female

AGE

6.5 Years

WEIGHT

7 Pounds

INTERPRETED BY

Eric Lindquist, DMV

DABVP, Cert. IVUSS

IMAGING PERFORMED BY

Dr. Meghan Myers

HOSPITAL NAME

Hershire AH

REFERRING VET

Dr. Meghan Myers

INVOICE

36321

DATE

3/18/22

Pancreas

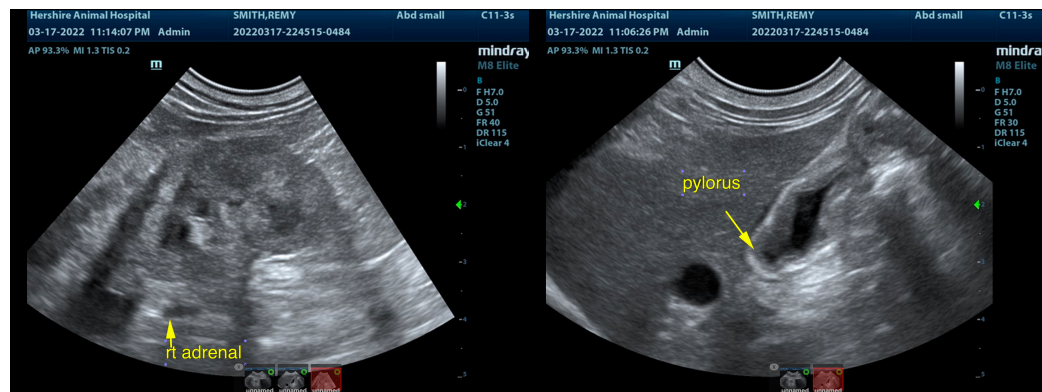
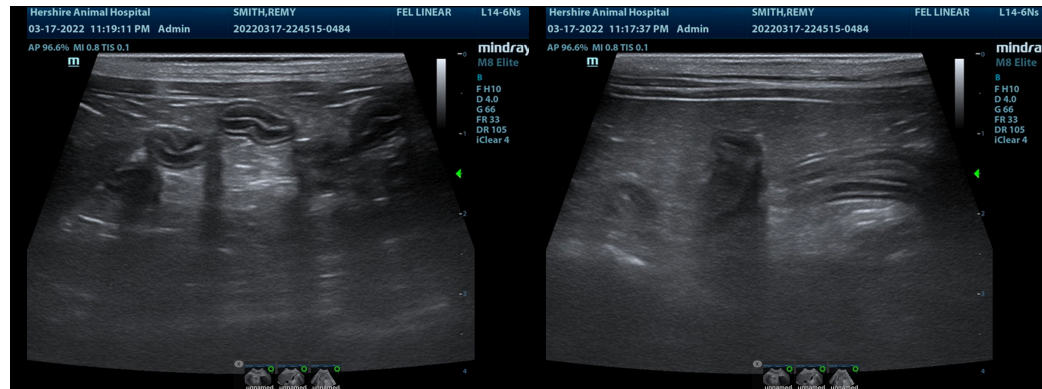
The base and limbs of the **pancreas** were observed to be largely isoechoic to surrounding omental fat. Some parenchymal remodeling, however, with mild deviation from curvilinear normalcy was observed. Pancreatic duct and capsular irregularities were present consistent with age related changes. If pain upon imaging (+ Murphy sign) was present or if the patient is focally painful in subxyphoid palpation then low-grade smoldering chronic pancreatitis should be suspected.

ULTRASONOGRAPHIC FINDINGS

- Normal abdomen with minor age related renal changes

INTERPRETATION OF THE FINDINGS & FURTHER RECOMMENDATIONS

No evidence of structural disease. Supportive care for GI upset/structurally insignificant inflammatory bowel should prove effective.





PATIENT

Remy Smith

SPECIES

Feline

BREED

DSH

SEX

Spayed Female

AGE

6.5 Years

WEIGHT

7 Pounds

INTERPRETED BY

Eric Lindquist, DMV

DABVP, Cert. IVUSS

IMAGING PERFORMED BY

Dr. Meghan Myers

HOSPITAL NAME

Hershire AH

REFERRING VET

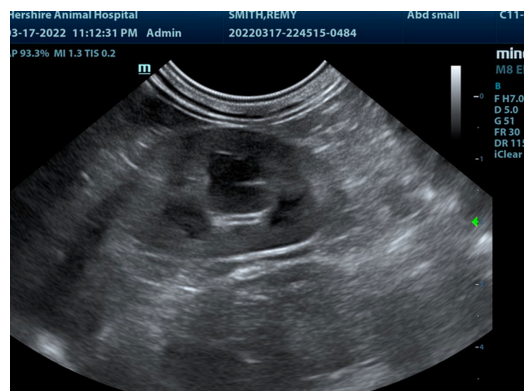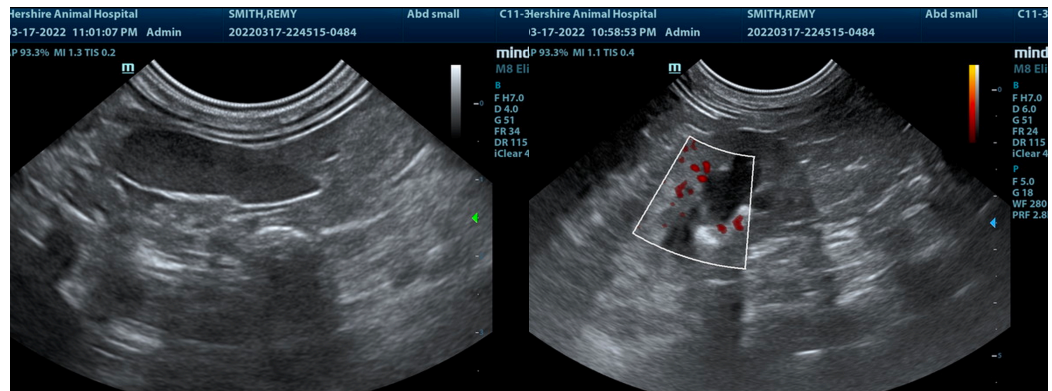
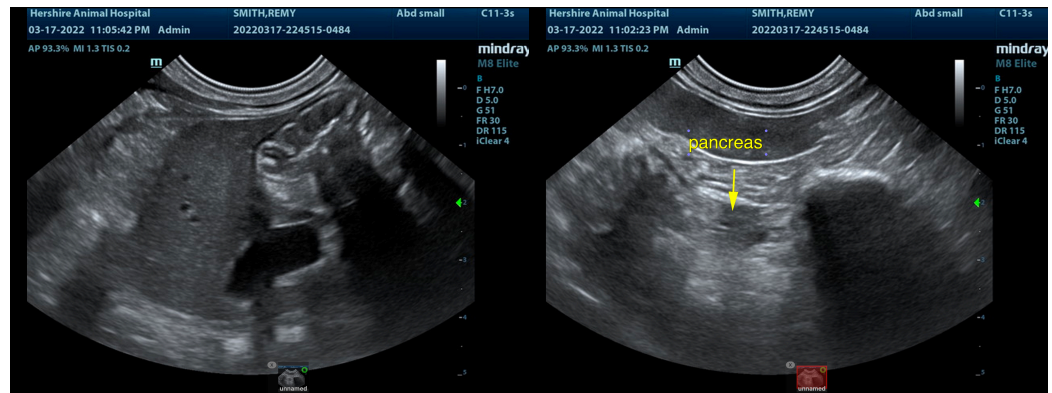
Dr. Meghan Myers

INVOICE

36321

DATE

3/18/22



The information and recommendations provided are based on the images presented by the referring veterinarian/sonographer. No evaluation can be communicated regarding pathology that was not visible in the image/video clips provided.

Thank you for this referral. If the clinical or image interpretation does not parallel your findings or if I can be of any further assistance please contact me.

Eric Lindquist, DMV, DABVP, Cert. IVUSS, CEO of SonoPath.com

info@SonoPath.com