



PATIENT

Jazzy Lopper-Ramos

SPECIES

Canine

BREED

Maltipoo

SEX

Spayed Female

AGE

15 Years

WEIGHT

24 Pounds

INTERPRETED BY

Eric Lindquist, DMV
DABVP, Cert. IVUSS

IMAGING PERFORMED BY

Kelly Vazquez

HOSPITAL NAME

Bergen Passiac AH

REFERRING VET

Dr. Ben Spitz

INVOICE

14354

DATE

3/18/22

PRESENTING CLINICAL SIGNS

History: History of coughing - collapsing trachea confirmed on radiographs. Suspect Cushingoid, elevated liver values. No current meds.

ULTRASONOGRAPHIC EXAMINATION OF THE ABDOMEN

Urinary System

The **bladder** in this patient was mildly thickened with slight echogenic mural changes. No calculi or masses were noted. Slight micropolypoid changes were noted. This is a frequent finding in older animals and may be linked to a history of chronic urinary tract infection or active urinary tract infection. Urinalysis would be recommended with culture if any evidence of inflammatory sediment is present. The region of the trigone and visible pelvic urethra were normal. This is a minor change.

The **kidneys** revealed largely normal size and structure, corticomedullary definition and ratio (cortex 1/3 of medulla) were essentially maintained with some moderate age-related loss of curvilinear patterns regarding the capsule and C/M junction. The cortices presented largely uniform texture with some increased echogenicity expected for his age patient. Medullary structure differed distinctly from that of the cortex and no evidence of pelvic dilation was present. Mineralization was present, nonobstructive. The right kidney measured 4.85 cm. The left kidney measured 4.43 cm.

Adrenal Glands

The **right adrenal gland** was enlarged, measuring 2.0 cm x 1.24 cm. Capsular expansion was noted without capsular escape.

The **left adrenal gland** was slightly swollen at the caudal pole, measuring 0.86 cm at the cranial pole and 0.41 cm at the cranial pole x 2.03 cm in length.

Spleen

The **spleen** was normal size and relatively normal contour with multifocal hyperechoic areas of mild mineralization. This is a benign change; however, can be related to Cushing's disease or other endocrinopathies.

Liver

The **liver** was subjectively normal in size, structure, and contour. The liver parenchyma was mildly nonuniform and hypoechoic to the spleen with a moderate coarse echotexture and subjective mild to benign parenchymal remodeling. The hepatic and portal vasculature were normal in appearance without signs of congestion. A minor gallbladder polyp was noted, measuring 1.1 cm x 0.77 cm. Minor gallbladder debris was present.

Gastrointestinal

Examination of the **gastrointestinal tract** revealed a stomach and intestine free of stasis, of normal wall thickness, acceptable curvilinear mural detail, and peristaltic activity. Small and large intestine demonstrated normal luminal chyme and stool consistency respectively. No obstructive or overt infiltrative disease was noted. No associated abnormal lymphatic activity was noted.

Pancreas



PATIENT	The base and limbs of the pancreas were observed to be largely isoechoic to surrounding omental fat. Pancreatic duct and capsular contour were acceptably normal and parenchyma respected normal curvilinear patterns. No overt evidence of active inflammatory or neoplastic disease was noted.
Jazzy Lopper-Ramos	
SPECIES	ULTRASONOGRAPHIC FINDINGS
Canine	<ul style="list-style-type: none"> • Bilateral adrenal nodules, more prominent on the right. No evidence of vascular invasion or capsular escape. • Splenic mineralization • Age-related renal changes with mineralization • Age-related urinary bladder changes
BREED	
Maltipoo	
SEX	INTERPRETATION OF THE FINDINGS & FURTHER RECOMMENDATIONS
Spayed Female	Right adrenal differentials include carcinoma, adenoma, hyperplasia and minor potential for pheochromocytoma. Adenoma or hyperplasia probable on the left adrenal gland. Discussion could be made for either pituitary dependent hyperadrenocorticism or adrenal dependent hyperadrenocorticism. If cushingoid parameters are present, then the following algorithm is recommended. LDDST should be utilized as a differential as to adrenal dependent versus pituitary dependent. The right adrenal gland is resectable.
AGE	For an additional charge, internal medicine consult can be utilized through SonoPath.com. You can select the internal medicine drop down at http://spa.sonopath.com/ .
15 Years	One of the world's top internists & SonoPath associate Dr. Remo Lobetti BVSc, MMedVet, PhD, DECVIM can evaluate your case through SonoPath. https://sonopath.com/resources/sonopath-services/internal-medicine-teleconsultation-services
WEIGHT	
24 Pounds	Cushing Work UP
INTERPRETED BY	Efficient & Accurate Cushing's Work up-Lindquist
Eric Lindquist, DMV DABVP, Cert. IVUSS	Notes regarding Cushing's Clinical Presentations:
IMAGING PERFORMED BY	<i>Nearly all Cushing's dogs have SAP elevations and true PU/PD (USG < 1.025) and most are polyphagic. Cushing's dogs are > 6 years and usually > 9 years old, usually have poor skin coats, body scores > 3/5, and are usually sedentary animals.</i>
Kelly Vazquez	<i>Its important to remember that Cushing's dogs usually look and play the part and other diseases cause false + stress related cortisol spikes. On rare occasion a Cushing's dog will not follow the rules but this is truly an exception.</i>
HOSPITAL NAME	<i>Potential Cushing's patient workups can be costly and frustrating if not definitive and, in my experience, the non-definitive patient usually has something else going on that may be contributing to some of the clinical signs a Cushing's dog will have, especially SAP elevations or PU/PD. Based on this prelude of information I came up with the following algorithm in the spirit of diagnostic efficiency.</i>
Bergen Passiac AH	<i>The following suggested protocol is based on current available literature on Cushing's disease and extensive clinical-sonographic experience evaluation + Cushing's and False + LDDST & ACTH stim. cases in order to maximize the efficiency of a Cushing's workup in practice.</i>
REFERRING VET	
Dr. Ben Spitz	
INVOICE	
14354	Screen first, workup second
DATE	
3/18/22	



PATIENT

Jazzy Lopper-Ramos

SPECIES

Canine

BREED

Maltipoo

SEX

Spayed Female

AGE

15 Years

WEIGHT

24 Pounds

INTERPRETED BY

Eric Lindquist, DMV
DABVP, Cert. IVUSS

IMAGING PERFORMED BY

Kelly Vazquez

HOSPITAL NAME

Bergen Passiac AH

REFERRING VET

Dr. Ben Spitz

INVOICE

14354

DATE

3/18/22

1) **UA:** Repeatable (2-3 urine samples) Urine specific gravity & urine cortisol/creatinine ratio (UCCR): If **repeatable USG < 10.20 and + UCCR** move to next step 2.

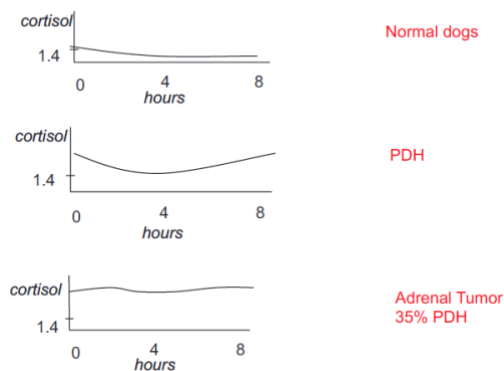
Note: UA is inexpensive and easy to obtain and if UA criteria is not met for Cushing's then resources can be spent into other more pertinent diagnostics or left on hold until the UA criteria is met in emerging Cushing's cases.

2) **Sonogram:** Does the patient **have concurrent disease** clinically or sonographically as non-Cushing's illness will influence the potential false + LDDST or even ACTH stim. The sonogram gives a global perspective of the internal health of the patient to be considered in the Cushing's workup as an assessment of concurrent disease. Is there a concurrent neoplastic process, UTI pancreatitis, mucocele...? Are the adrenals enlarged (Cushing's-PDH, stress, age related or breed variant), or atrophied (Iatrogenic Cushing's or adrenal burnout), have asymmetric enlargement (Adrenal tumor, hyperplasia, adenoma, age related variant), or is there vascular invasion (Invasive pheo with false + UA criteria or adenocarcinoma or phrenic thrombosis)? The sonogram answers these questions proactively.

Address & treat concurrent disease first before performing Cushing's testing or testing will be artificially altered increasing false negatives and positives.

3) **LDDST** (0.01 D-Sodium phosphate mg/kg IV **with precise dosing******) (Better screening test but plagued with false + but considered more specific than ACTH stim) Use if there is potential early Cushing's or if adrenal asymmetry present on sonogram suspecting tumor. Use LDDST in cats at a higher dose (0.1 mg/kg IV). **Interpretation LDDST:** Look at 8-hour post first: If > 1.4 = Cushing's. Then look at 4-hour: if > 1.4 or > 50% baseline = Cushing's. 4-hour do then 8-hour spike most consistent with PDH. Flat line high constant curve without dip more consistent with tumor but can be PDH. See attached graph.

LDDS



Courtesy: Rebecca Berg DACVIM, DECVIM

4) **ACTH stim.** (Better confirming test but can have false +) Use if the patient "looks" Cushingoid or if bilateral adrenal enlargement is present, or high normal width on sonogram, or if iatrogenic Cushing's suspected (Cortisone Tx in past). ACTH stim is better for diagnosis of Addison's, Iatrogenic Cushing's,



PATIENT

Jazzy Lopper-Ramos

and Cushing's therapy monitoring but problematic with initial Cushing's diagnosis. First dx LDDST is suggested.

SPECIES

Canine

5) If **diabetic** then run both LDDST & ACTH stim but stabilize as much as possible first.

BREED

Maltipoo

5) Run a **serial blood pressure** in a BP friendly non "white coat effect" atmosphere. Run at least 3 at different times over a few hours or when eating as the patient tends to be calm when eating or give Torbutrol when entering the facility. Cushing's hypertension is usually 150-180 systolic range while pheochromocytoma range is more often > 180 systolic.

SEX

Spayed Female

6) **Perform CT** of the pituitary to identify macro adenoma expansion if any lethargy or dullness or other central clinical CNS signs are minimally present. CT for adrenal may be more through for adrenalectomy surgical planning if ultrasound views of the CVC were problematic.

AGE

15 Years

7) **Adrenectomy** for adrenal mass is prescribed then it is essential to stabilize the patient first regarding secondary disease such as organ dysfunction, hypertension, diabetes mellitus, hypernatremia, thromboembolic risk urinary and other infection in order to minimize potential for operative and postoperative complications as they are common in adrenalectomy. Trilostane stabilization therapy for Cushing's would be the first approach then address surgery and hypertension should be managed ideally < 160 systolic with ace inhibitors, phenoxybenzamine, or amlodipine.

WEIGHT

24 Pounds

Suggested reading:

Behrend EN, Kooistra HS, Nelson R, et al. Diagnosis of Spontaneous Canine Hyperadrenocorticism: 2012 ACVIM Consensus Statement (Small Animal). J Vet Intern Med 2013;27:1292–1304 .

INTERPRETED BY

Eric Lindquist, DMV
DABVP, Cert. IVUSS

IMAGING PERFORMED BY

Kelly Vazquez

HOSPITAL NAME

Bergen Passiac AH

REFERRING VET

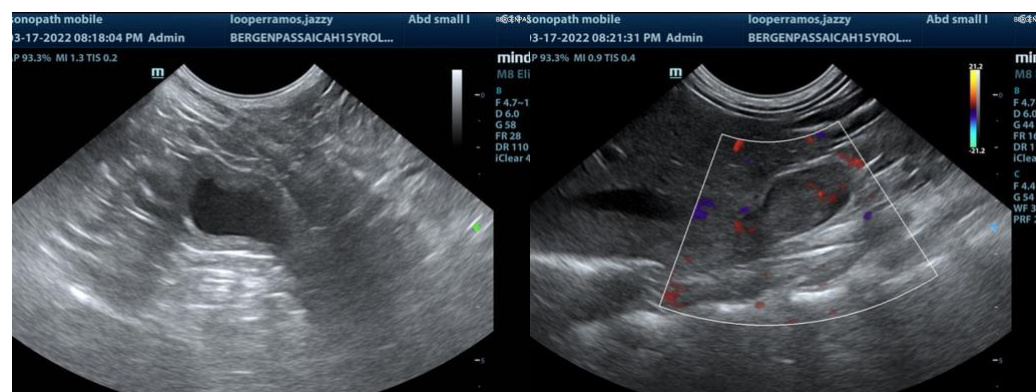
Dr. Ben Spitz

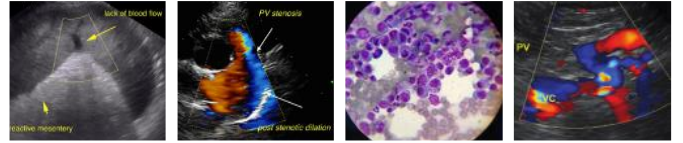
INVOICE

14354

DATE

3/18/22





PATIENT

Jazzy Lopper-Ramos

SPECIES

Canine

BREED

Maltipoo

SEX

Spayed Female

AGE

15 Years

WEIGHT

24 Pounds

INTERPRETED BY

Eric Lindquist, DMV
DABVP, Cert. IVUSS

IMAGING PERFORMED BY

Kelly Vazquez

HOSPITAL NAME

Bergen Passiac AH

REFERRING VET

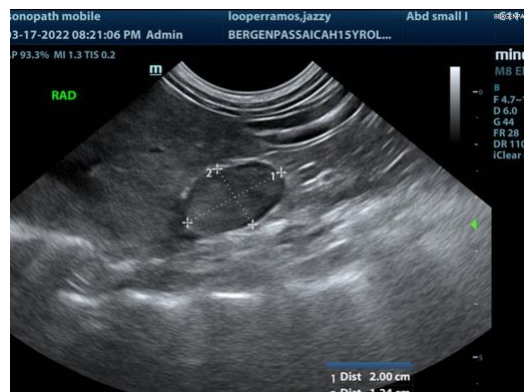
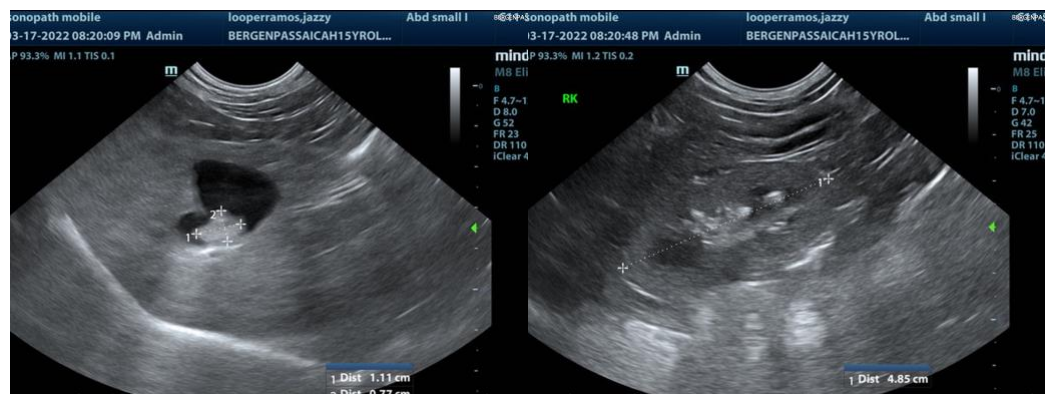
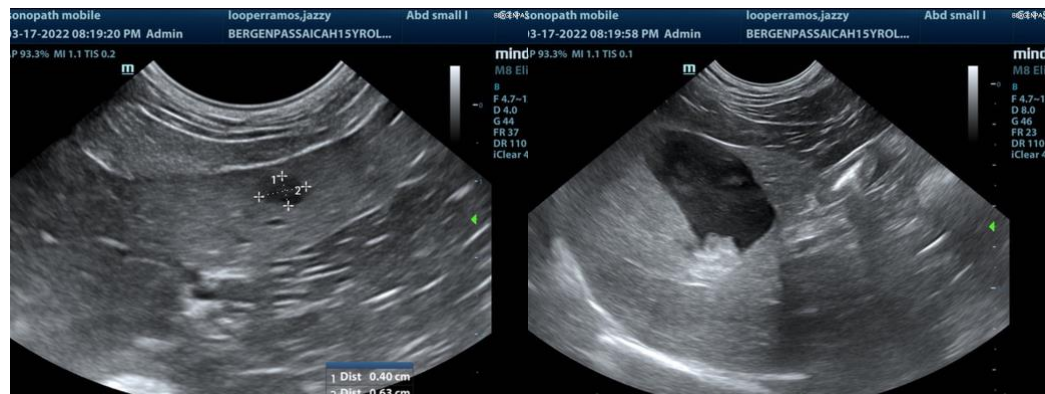
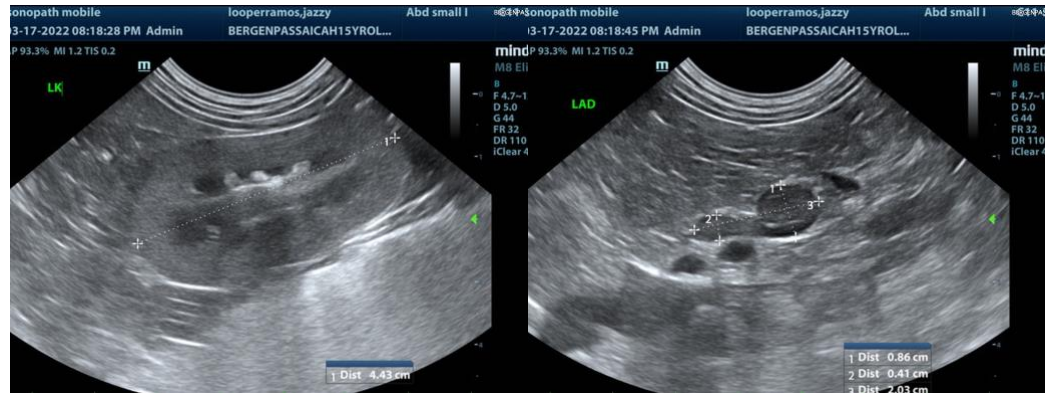
Dr. Ben Spitz

INVOICE

14354

DATE

3/18/22





PATIENT

Jazzy Lopper-Ramos

The information and recommendations provided are based on the images presented by the referring veterinarian. No evaluation can be communicated regarding pathology that was not visible in the image/video clips provided.

SPECIES

Canine

Thank you for this referral. If the clinical or image interpretation does not parallel your findings or if I can be of any further assistance please contact me.

BREED

Maltipoo

Eric Lindquist, DMV, DABVP, Cert. IVUSS, CEO of SonoPath.com
info@SonoPath.com

SEX

Spayed Female

AGE

15 Years

WEIGHT

24 Pounds

INTERPRETED BY

Eric Lindquist, DMV
DABVP, Cert. IVUSS

**IMAGING
PERFORMED BY**

Kelly Vazquez

HOSPITAL NAME

Bergen Passiac AH

REFERRING VET

Dr. Ben Spitz

INVOICE

14354

DATE

3/18/22