



PATIENT

Chloe Wilgus

SPECIES

Canine

BREED

Yorkshire Terrier

SEX

Spayed Female

AGE

12.5 Years

WEIGHT

9.6 Pounds

INTERPRETED BY

Eric Lindquist, DMV
DABVP, Cert. IVUSS

IMAGING PERFORMED BY

Judy Schroeder

HOSPITAL NAME

Animal Health
Associates

REFERRING VET

Judy Schroeder

INVOICE

14371

DATE

3/18/22

PRESENTING CLINICAL SIGNS

History: History of decreased appetite, weight loss, and urinary incontinence over several months. Blood testing run 2 months ago was normal. Patient appetite improved slightly with amoxicillin treatment, but urine culture was negative.

Abnormal PE/Chem/CBC/UA Results: Weight loss, thin skin, slightly tense abdomen. Chem, CBC, Spec cPL were normal. Urine culture negative, USG 1.017

ULTRASONOGRAPHIC EXAMINATION OF THE ABDOMEN

Urinary System

The **urinary bladder**, trigone, and pelvic urethra presented normal thicknesses and normal tone. The ureters were not visible which is normal. No uroliths or sediment were visualized and anechoic urine was present. No evidence of inflammatory or neoplastic changes were noted. Ureteral papillae were normal. The pelvic urethra was imaged 1.0 cm beyond the cystourethral junction.

The **kidneys** revealed normal size and structure, corticomedullary definition and ratio for this age. The cortices presented largely uniform texture with normal echogenic relationship to liver and spleen. Medullary structure differed distinctly from the cortex and no evidence of pelvic dilation was present. The capsules were acceptably uniform without significant irregularities. The left kidney measured 4.0 cm. The right kidney measured 3.5 cm.

Adrenal Glands

The regions of the **adrenal glands** revealed no evident pathology.

Spleen

The **spleen** presented a smooth homogeneous parenchyma hyperechoic to liver and renal cortical parenchyma. The capsule was smooth without noticeable expansion or deviation from within the spleen or adjacent pathology. The splenic vasculature demonstrated normal volume without signs of congestion or thrombosis. No sonographic evidence of acute or chronic inflammatory, neoplastic, or infarctual changes were noted.

Liver

The **liver** images from right and left intercostal as well as subcostal views revealed subjectively normal liver size, contour, and structure. Some mild age-related parenchymal remodeling was noted but likely not clinically significant at this time. Vascular and biliary tracts were of normal volume and no evidence of congestion was noted. The gallbladder presented some dependent debris with essentially normal contour. The cystic and common bile ducts were normal. No overt evidence of active inflammatory, infiltrative or regenerative pathology was noted but should be paired with current or past LE elevations regarding any clinical significance to this presentation. The hepatic lymph nodes were unremarkable.

Gastrointestinal

Examination of the **gastrointestinal tract** revealed a stomach and intestine free of stasis, of normal wall thickness, acceptable curvilinear mural detail, and peristaltic activity. Small and large intestine demonstrated normal luminal chyme and stool consistency respectively. No obstructive or overt infiltrative disease was noted. No associated abnormal lymphatic activity was noted.



PATIENT

Chloe Wilgus

SPECIES

Canine

BREED

Yorkshire Terrier

SEX

Spayed Female

AGE

12.5 Years

WEIGHT

9.6 Pounds

INTERPRETED BY

Eric Lindquist, DMV
DABVP, Cert. IVUSS

IMAGING PERFORMED BY

Judy Schroeder

HOSPITAL NAME

Animal Health
Associates

REFERRING VET

Judy Schroeder

INVOICE

14371

DATE

3/18/22

Pancreas

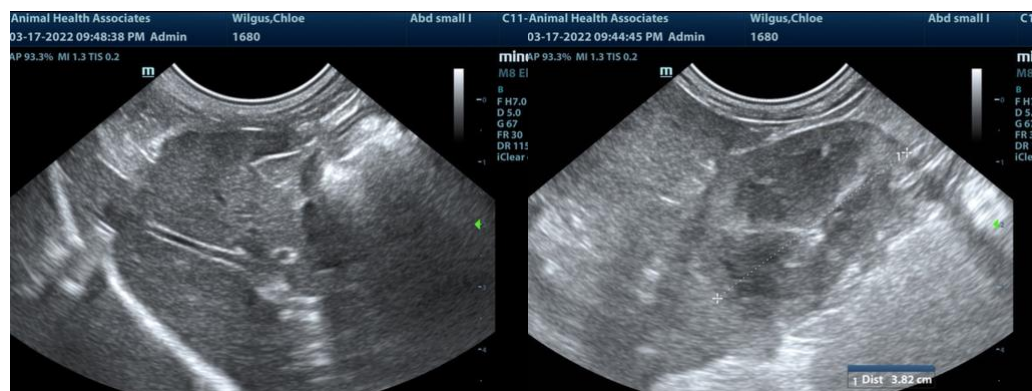
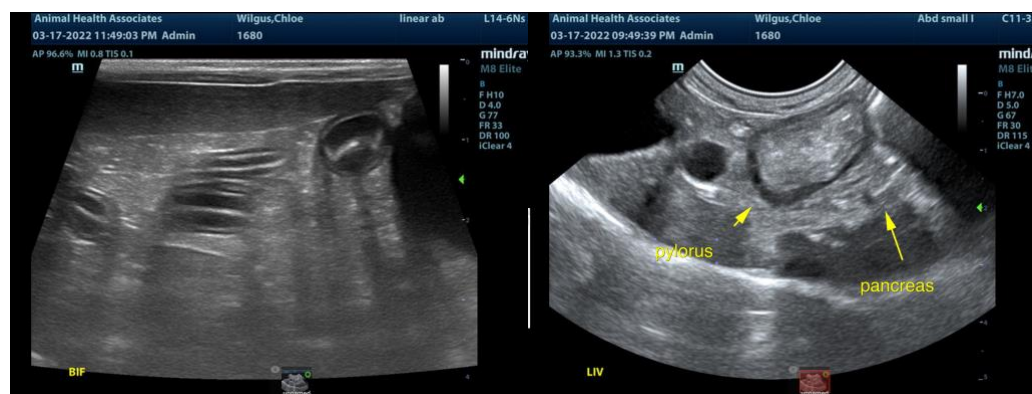
The base and limbs of the **pancreas** were observed to be largely isoechoic to surrounding omental fat. Some minor parenchymal remodeling, however, with mild deviation from curvilinear normalcy was observed. Pancreatic duct and capsular irregularities were present consistent with age related changes. If pain upon imaging (+ Murphy sign) was present or if the patient is focally painful in subxyphoid palpation then low-grade smoldering chronic pancreatitis should be suspected.

ULTRASONOGRAPHIC FINDINGS

- Structurally normal abdomen

INTERPRETATION OF THE FINDINGS & FURTHER RECOMMENDATIONS

No evidence of pathology related to the clinical history. Maldigestion panel, three view chest radiographs and full CNS examination is recommended to examine for occult disease that could be responsible for the weight loss. Evaluation for competitive eating environments should also be considered.





PATIENT

Chloe Wilgus

SPECIES

Canine

BREED

Yorkshire Terrier

SEX

Spayed Female

AGE

12.5 Years

WEIGHT

9.6 Pounds

INTERPRETED BY

Eric Lindquist, DMV
DABVP, Cert. IVUSS

IMAGING PERFORMED BY

Judy Schroeder

HOSPITAL NAME

Animal Health
Associates

REFERRING VET

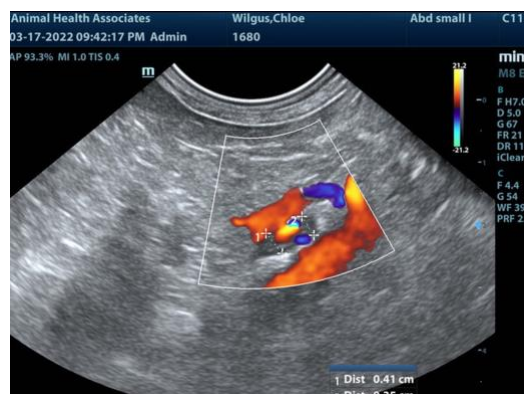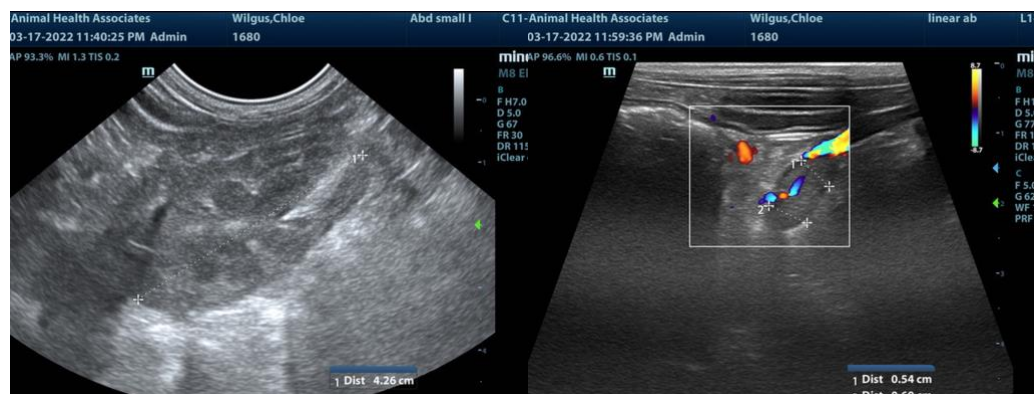
Judy Schroeder

INVOICE

14371

DATE

3/18/22



The information and recommendations provided are based on the images presented by the referring veterinarian. No evaluation can be communicated regarding pathology that was not visible in the image/video clips provided.

Thank you for this referral. If the clinical or image interpretation does not parallel your findings or if I can be of any further assistance please contact me.

Eric Lindquist, DMV, DABVP, Cert. IVUSS, CEO of SonoPath.com
info@SonoPath.com