



PATIENT PRESENTING CLINICAL SIGNS

Charlie Aikin
History: weight loss, anorexia
Abnormal PE/Chem/CBC/UA Results: low alb, creat elevated AST, ALP, bilirubin, chol, amyl, creat kinase anemic(regenerative)

SPECIES

Canine

ULTRASONOGRAPHIC EXAMINATION OF THE ABDOMEN

Urinary System

BREED

Pom X

The **urinary bladder**, trigone, and pelvic urethra presented normal thicknesses and normal tone. The ureters were not visible which is normal. No uroliths or sediment were visualized, and anechoic urine was present. No evidence of inflammatory or neoplastic changes were noted. Ureteral papillae were normal.

SEX

Neutered Male

The **kidneys** were mildly swollen and slightly irregular with some loss of corticomedullary definition. The left kidney measured 5.17 cm. The right kidney measured 5.57 cm.

AGE

10 Years

Adrenal Glands

Both **adrenal glands** were visualized and recognized as having normal shape, size, position and echogenicity for this breed. The phrenic vasculature, glandular echogenicity and detail were unremarkable. Capsule, cortex, and medullary definition were normal for this age patient. The right adrenal gland measured 1.9 cm x 0.46 cm at the cranial pole and 0.54 cm at the caudal pole. The left adrenal gland measured 1.72 cm x 0.44 cm at the caudal pole and 0.45 cm at the cranial pole.

WEIGHT

6.4 kg

Spleen

INTERPRETED BY

Eric Lindquist, DMV
DABVP, Cert. IVUSS

The **spleen** revealed a moderately complex, 4.0 cm, mixed echogenic and cystic mass, deriving from the cranial body of the spleen. No evidence of rupture noted. However, enhanced mesentery was present.

IMAGING

PERFORMED BY

Kelly Reschny

Liver

The **liver** was riddled with multiple expansive mixed echogenic masses of similar echotexture as that of the spleen, deviating the gallbladder. Coalescing target lesions noted throughout the liver with swollen irregular contour. Slight areas of free fluid were noted around the right liver, which presented coalescing disruptive target lesions.

HOSPITAL NAME

Nelson AH

Gastrointestinal

Examination of the **gastrointestinal tract** revealed a stomach and intestine free of stasis, of normal wall thickness, acceptable curvilinear mural detail, and peristaltic activity. Small and large intestine demonstrated normal luminal chyme and stool consistency respectively. No obstructive or overt infiltrative disease was noted. No associated abnormal lymphatic activity was noted.

REFERRING VET

Dr. Drewry

Pancreas

INVOICE

14365

The base and limbs of the **pancreas** were observed to be largely isoechoic to surrounding omental fat. Pancreatic duct and capsular contour were acceptably normal and parenchyma respected normal curvilinear patterns. No overt evidence of active inflammatory or neoplastic disease was noted.

DATE

3/18/22

ULTRASONOGRAPHIC FINDINGS

- Splenohepatic neoplasia, sarcoma pattern



PATIENT

- Swollen kidneys

Charlie Aikin

INTERPRETATION OF THE FINDINGS & FURTHER RECOMMENDATIONS

25-gauge FNA of the spleen and liver recommended. Prognosis is poor long term; however, it may be responsive to chemotherapy depending upon cytology results, Three-view chest radiographs and echocardiogram recommended to assess for concurrent disease.

SPECIES

Canine

BREED

Pom X

SEX

Neutered Male

AGE

10 Years

WEIGHT

6.4 kg

INTERPRETED BY

Eric Lindquist, DMV
DABVP, Cert. IVUSS

IMAGING PERFORMED BY

Kelly Reschny

HOSPITAL NAME

Nelson AH

REFERRING VET

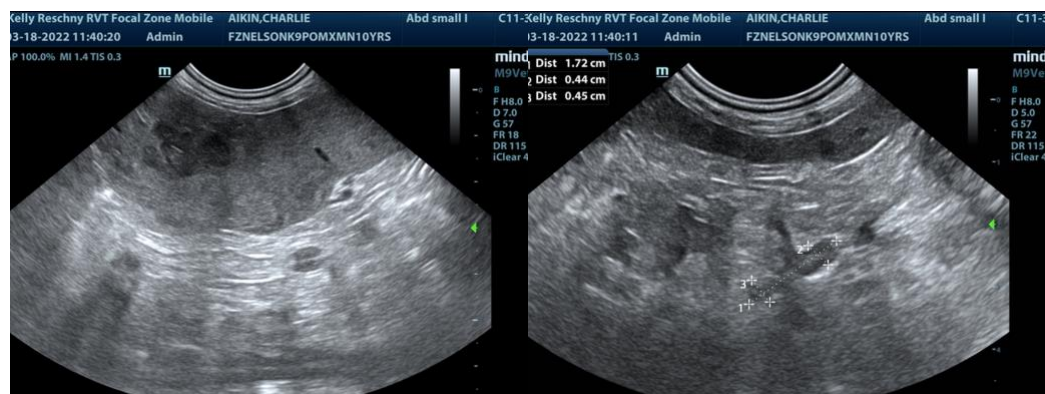
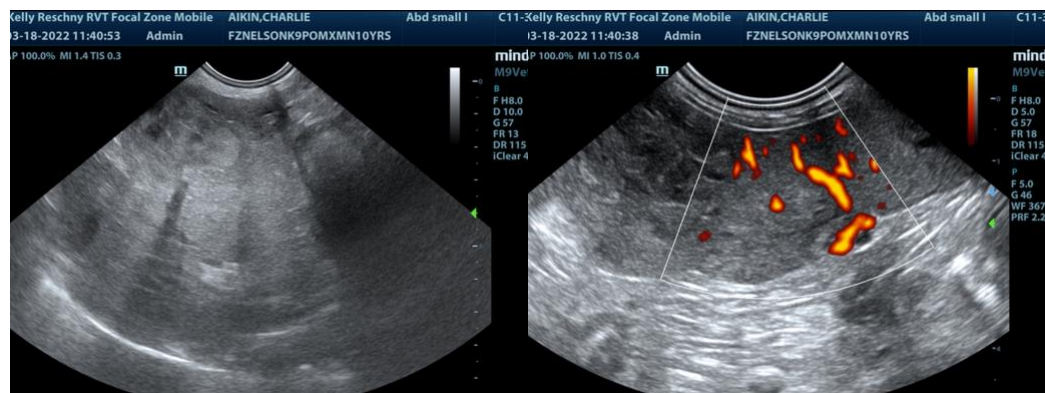
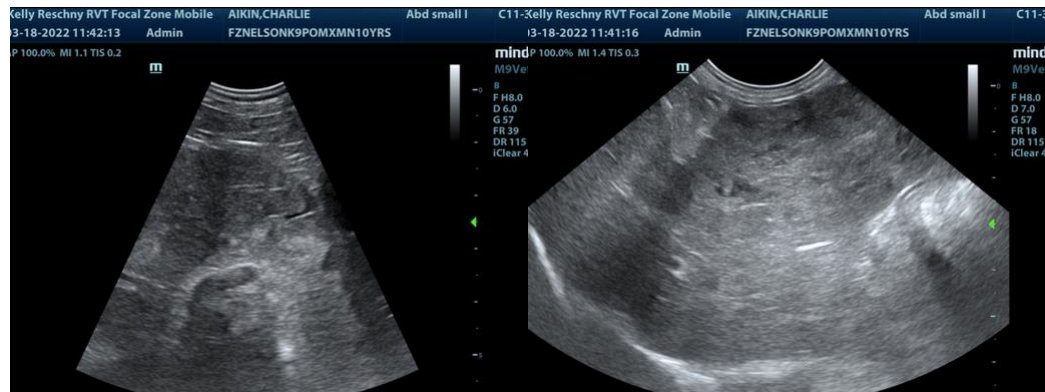
Dr. Drewry

INVOICE

14365

DATE

3/18/22





PATIENT

Charlie Aikin

SPECIES

Canine

BREED

Pom X

SEX

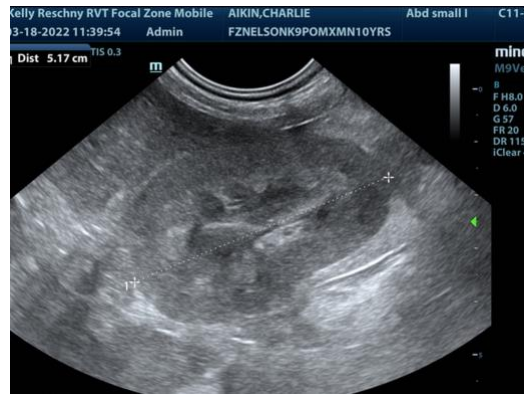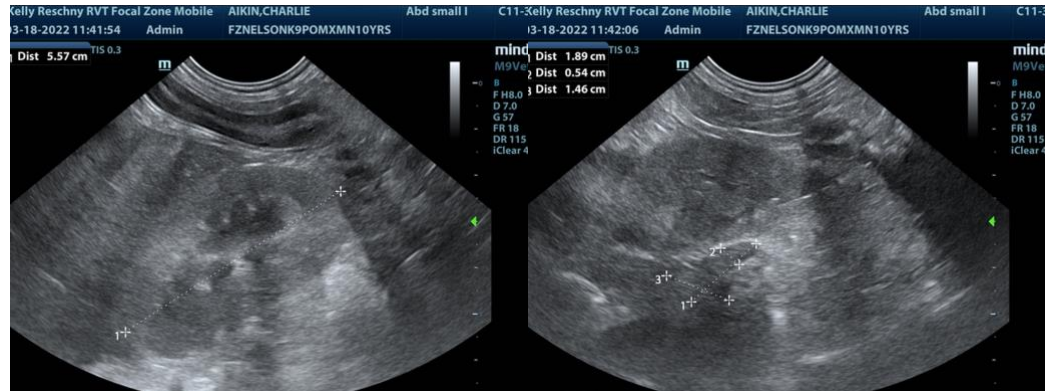Neutered Male

AGE

10 Years

WEIGHT

6.4 kg



INTERPRETED BY

Eric Lindquist, DMV
DABVP, Cert. IVUSS

IMAGING PERFORMED BY

Kelly Reschny

HOSPITAL NAME

Nelson AH

REFERRING VET

Dr. Drewry

INVOICE

14365

DATE

3/18/22

The information and recommendations provided are based on the images presented by the referring veterinarian. No evaluation can be communicated regarding pathology that was not visible in the image/video clips provided.

Thank you for this referral. If the clinical or image interpretation does not parallel your findings or if I can be of any further assistance please contact me.

Eric Lindquist, DMV, DABVP, Cert. IVUSS, CEO of SonoPath.com
Eric.Lindquist@SonoPath.com