



PATIENT

Bea Romlein

SPECIES

Canine

BREED

Boston Terrier

SEX

Spayed Female

AGE

9 Years

WEIGHT

17.3 Pounds

PRESENTING CLINICAL SIGNS

History: heart murmur, decreased appetite for the past 10 months. Not on any meds.

Abnormal PE/Chem/CBC/UA Results: platelets 427 incr; chem nsf

ULTRASONOGRAPHIC EXAMINATION OF THE HEART & ABDOMEN

CANINE CARDIAC PARAMETERS	MR VMAX (m/s)	TR VMAX (m/s)	LA/AO (Boon method)	LA/AO (Heart Base; Swe)	FS (%)	EF (%)	EPSS (cm)
NORMAL PARAMETER	4.5-5.5	<2.7	1.3	<1.6	28-40	40-100	<0.6
PATIENT	6.21	2.88	NM	--	48	81	0.1
CANINE CARDIAC PARAMETERS	HR (BPM)	AV VMAX (m/s)	PV MAX (m/s)	BODY WEIGHT (kg)	LA 2D short axis Base view (cm)	LVIDd Avg; 2D and m-mode short axis (cm)	LVIDs Avg; 2D and m-mode short axis (cm)
NORMAL PARAMETER	50-100	0.7-1.7	0.7-1.6	BELOW	BELOW	BELOW	BELOW
PATIENT	158	1.27	.70	--	3.5	3.52	--

INTERPRETED BY

Eric Lindquist, DMV
DABVP, Cert. IVUSS

IMAGING PERFORMED BY

Diane McFadden

HOSPITAL NAME

Newton VH

REFERRING VET

Dr. Kim

INVOICE

14356

DATE

3/18/22

Cardiac Presentation

The echocardiogram for this patient presented excessive **left atrial size** expressed both in the LA/AO and LA max measurements Chamber volumes and echogenicity were normal. The cranial and caudal **mitral** valve leaflets presented vegetative thickening consistent with endocardiosis. Doppler indicated measurable insufficiency. The **left ventricle** presented thicknesses with linear contour and was not dilated nor restricted. The **myocardium** presented normal echogenicity without subjective evidence of significant fibrotic or ischemic disease. **Contractility** of the ventricular walls was adequate and in normal range for this patient evidenced by the fractional shortening measurement and subjective evaluation of the different regions of the myocardium. Aortic insufficiency noted. The **right atrium** and auricle revealed normal size, structure and content. No evidence of masses was noted or chamber overload. **Tricuspid** insufficiency noted. The **right ventricle** was of normal size (1/3 diameter of LV), chordae structure, myocardial echogenicity and thickness. **Pulmonic** tract assessment revealed normal valve structure, laminar flow, and diameter (approx.1:1 pa/ao ratio). Aortic body mass was noted in this patient, measuring 1.3 cm x 2.6 cm, this is not causing an overt clinical issue at this time. Occasional arrhythmia noted.

Urinary System

The **urinary bladder** and visible pelvic urethra were unremarkable for the level of repletion presented. The urine, however, did present some mildly echogenic debris consistent with mucous, exfoliated cells from renal or bladder origin, and/or blood clots as these echogenic changes can all present similarly. This is often related to urinary tract infection but may represent simple evidence of exfoliated debris



PATIENT

Bea Romlein

or sterile inflammation. Cystocentesis, urinalysis, +/- culture would be recommended to rule out and define any UTI. The pelvic urethra was imaged 3.0 cm beyond the cystourethral junction.

SPECIES

Canine

The **kidneys** revealed largely normal size and structure, corticomedullary definition and ratio (cortex 1/3 of medulla) were essentially maintained with some minor age-related loss of curvilinear patterns regarding the capsule and C/M junction. The cortices presented largely uniform texture with some increased echogenicity expected for his age patient. Medullary structure differed distinctly from that of the cortex and no evidence of pelvic dilation was present. Slight mineralization was noted in both kidneys. The right kidney measured 4.9 cm. The left kidney measured 4.61 cm.

BREED

Boston Terrier

SEX

Spayed Female

Both **adrenal glands** were visualized and recognized as having largely normal shape, size, position and acceptable echogenicity for this age group and breed. Some mild heterogeneity was noted within the adrenal parenchyma without concerning capsular distortion. These changes are likely age related but should be monitored by sonogram should the patient be suspected of having adrenal disease.

AGE

9 Years

The right adrenal gland measured 1.9 cm x 1.37 cm at the cranial pole and 0.54 cm at the caudal pole. The left adrenal gland measured 1.92 cm x 0.59 cm at the caudal pole and 0.49 cm at the cranial pole.

WEIGHT

17.3 Pounds

Spleen

The **spleen** presented a smooth homogeneous parenchyma hyperechoic to liver and renal cortical parenchyma. The capsule was smooth without noticeable expansion or deviation from within the spleen or adjacent pathology. The splenic vasculature demonstrated normal volume without signs of congestion or thrombosis. No sonographic evidence of acute or chronic inflammatory, neoplastic, or infarctual changes were noted.

INTERPRETED BY

Eric Lindquist, DMV
DABVP, Cert. IVUSS

Liver

The **liver** images submitted revealed subjectively normal liver size, contour, and structure. Parenchymal echogenicity was naturally coarse and hypoechoic to the spleen. Vascular and biliary tracts were of normal volume with no evidence of congestion. The gallbladder presented acceptably thin walls with primarily anechoic content. The cystic and common bile ducts were normal. No pathological hepatic lymphadenopathy was evident. No overt structural evidence of inflammatory, infiltrative or regenerative pathology was evident.

IMAGING PERFORMED BY

Diane McFadden

HOSPITAL NAME

Newton VH

Gastrointestinal

Examination of the **gastrointestinal tract** revealed a stomach and intestine free of stasis, of normal wall thickness, acceptable curvilinear mural detail, and peristaltic activity. Small and large intestine demonstrated normal luminal chyme and stool consistency respectively. No obstructive or overt infiltrative disease was noted. No associated abnormal lymphatic activity was noted.

REFERRING VET

Dr. Kim

Pancreas

INVOICE

14356

The base and limbs of the **pancreas** were observed to be largely isoechoic to surrounding omental fat. Pancreatic duct and capsular contour were acceptably normal and parenchyma respected normal curvilinear patterns. No overt evidence of active inflammatory or neoplastic disease was noted.

DATE

3/18/22

ULTRASONOGRAPHIC FINDINGS



PATIENT

Bea Romlein

- Mitral insufficiency
- Mild left atrial enlargement
- Occasional arrhythmia
- Stage B-2 valvular disease

SPECIES

Canine

- Small aortic body mass. Likely chemodectoma. Not likely causing clinical issues at this time.
- Age-related renal and adrenal changes
- Urinary bladder debris

BREED

Boston Terrier

INTERPRETATION OF THE FINDINGS & FURTHER RECOMMENDATIONS

SEX

Spayed Female

The heart is in a somewhat precarious state with volume overload and a heart that is working to compensate for the valvular insufficiency. Target respiratory rate is < 20 resp/minute after therapy. After initiating therapy, I recommend recheck on the clinical exam, BUN, Creatinine, USG, Chest radiographs & Blood pressure in 5-7 days. Recheck echo in 1 month. Earlier if clinical decompensation is occurring. I do not recommend anesthesia at this time until stabilization has occurred on the recommended medications. Repeat preanesthetic echo is ideal if anesthesia is eventually necessary. Pimobendan indicated at 0.3 mg/kg BID. EKG and blood pressures indicated.

AGE

9 Years

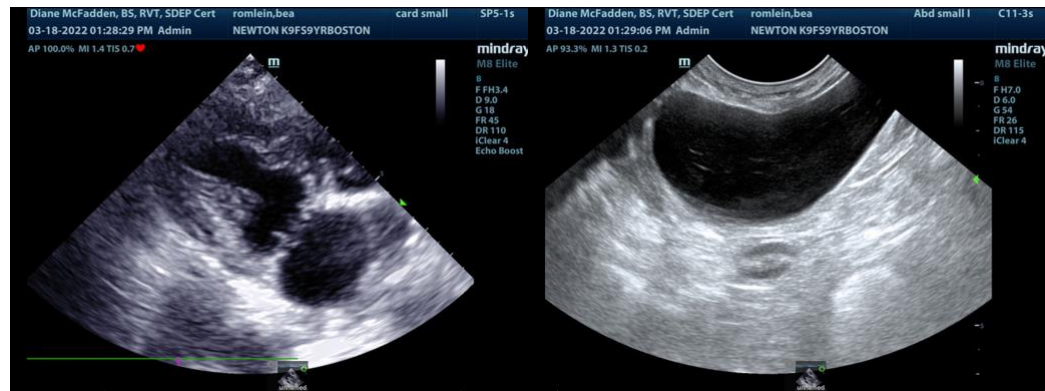
The cause of the poor appetite is unclear in this patient. Structurally insignificant gastritis, orthopedic pain, hypertension, CNS disease, extracardiac thoracic disease all potentials and should all be investigated. However, the abdomen appears unremarkable. Assessment for underlying UTI indicated.

WEIGHT

17.3 Pounds

INTERPRETED BY

Eric Lindquist, DMV
DABVP, Cert. IVUSS

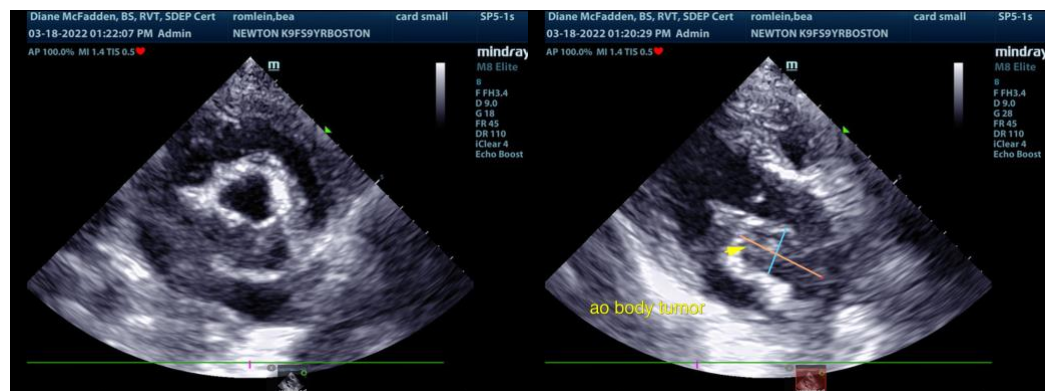


IMAGING PERFORMED BY

Diane McFadden

HOSPITAL NAME

Newton VH



REFERRING VET

Dr. Kim

INVOICE

14356

DATE

3/18/22



PATIENT

Bea Romlein

SPECIES

Canine

BREED

Boston Terrier

SEX

Spayed Female

AGE

9 Years

WEIGHT

17.3 Pounds

INTERPRETED BY

Eric Lindquist, DMV
DABVP, Cert. IVUSS

IMAGING PERFORMED BY

Diane McFadden

HOSPITAL NAME

Newton VH

REFERRING VET

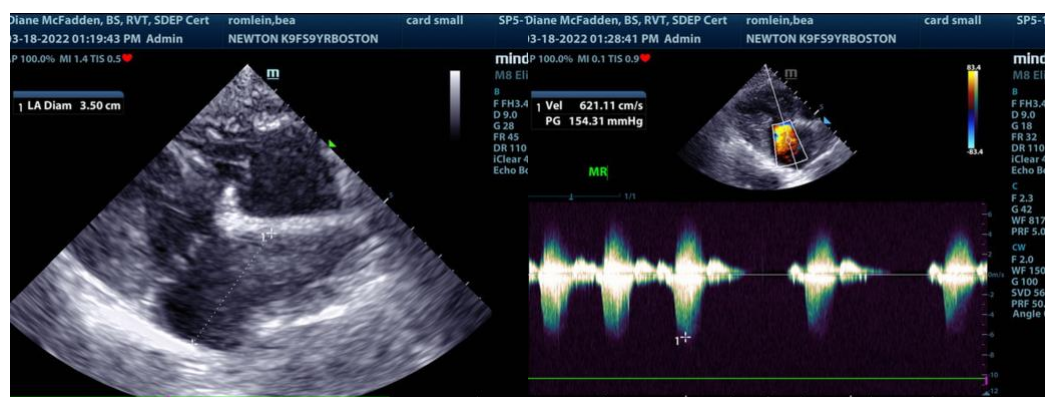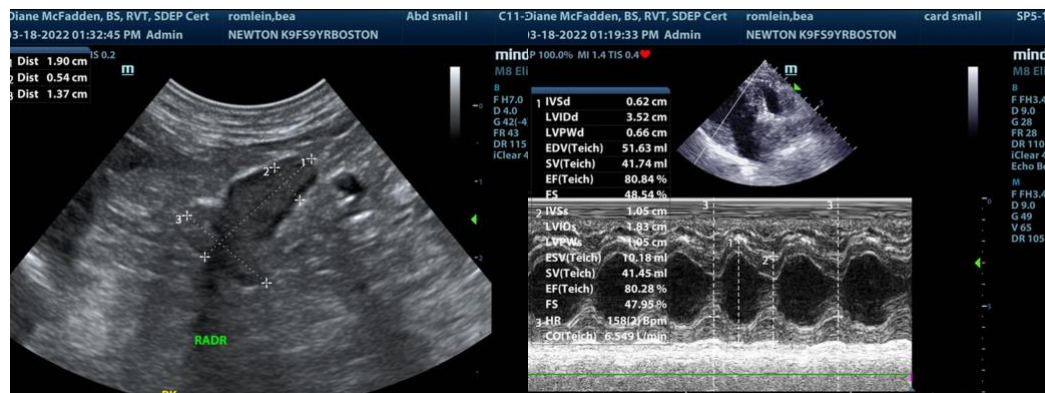
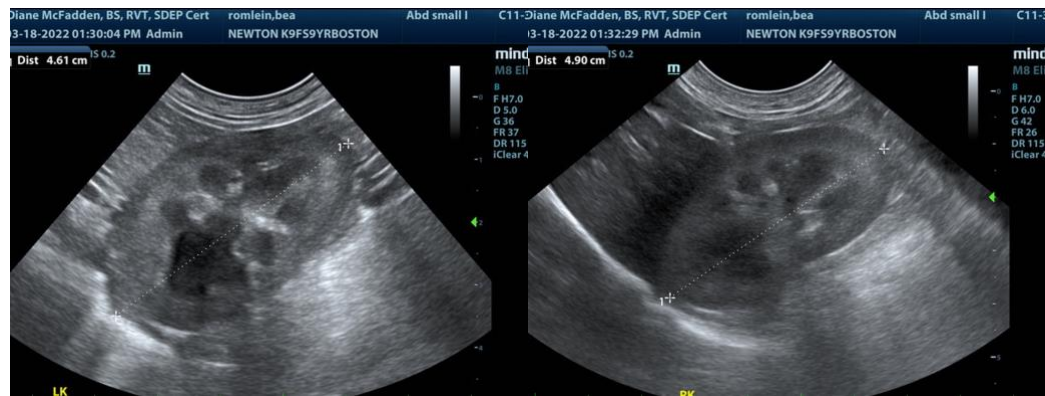
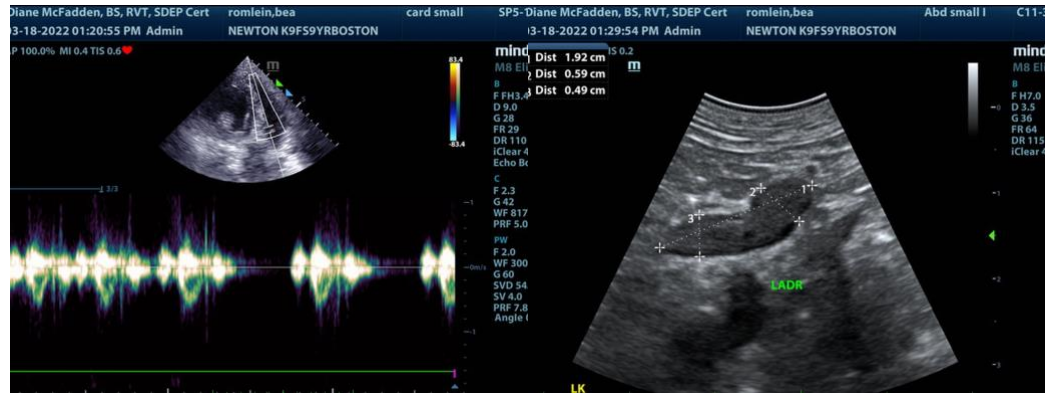
Dr. Kim

INVOICE

14356

DATE

3/18/22





PATIENT

Bea Romlein

SPECIES

Canine

BREED

Boston Terrier

SEX

Spayed Female

AGE

9 Years

WEIGHT

17.3 Pounds

INTERPRETED BY

Eric Lindquist, DMV
DABVP, Cert. IVUSS

IMAGING PERFORMED BY

Diane McFadden

HOSPITAL NAME

Newton VH

REFERRING VET

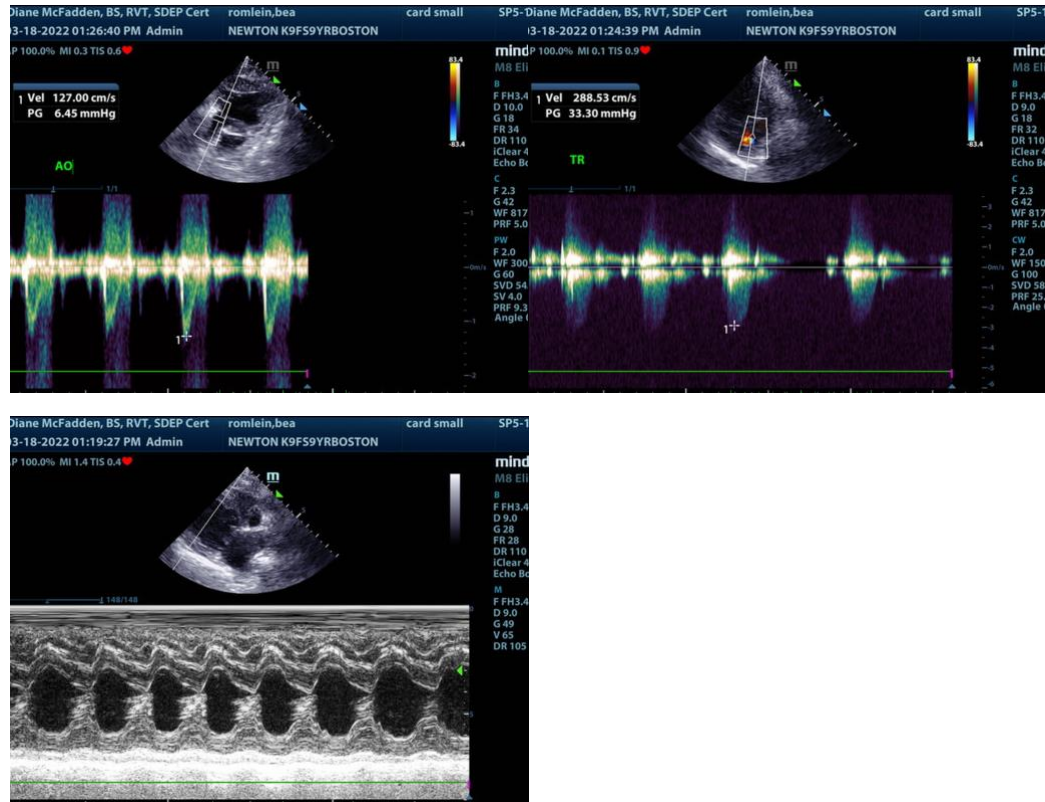
Dr. Kim

INVOICE

14356

DATE

3/18/22



The information and recommendations provided are based on the images presented by the referring veterinarian. No evaluation can be communicated regarding pathology that was not visible in the image/video clips provided.

Thank you for this referral. If the clinical or image interpretation does not parallel your findings or if I can be of any further assistance please contact me.

Eric Lindquist, DMV, DABVP, Cert. IVUSS, CEO of SonoPath.com
info@SonoPath.com