



PATIENT

Sammie Fitzgerald

SPECIES

Canine

BREED

Jack Russell Terrier

SEX

Spayed female

AGE

12 years

WEIGHT

15.2 lbs

INTERPRETED BY

Eric Lindquist, DMV
DABVP, Cert. IVUSS

IMAGING PERFORMED BY

Jenny Wenrich DVM

HOSPITAL NAME

Straley VA

REFERRING VET

Dr. Wenrich

INVOICE

73514

DATE

3/17/26

PRESENTING CLINICAL SIGNS

- Chronic pericardial effusion scheduled for pericardiectomy in April at Cornell, cardiologist recommended abdominal U/S to assess for abdominal lesion/metastasis of possible cardiac mass, on 3/14 pericardiocentesis and thoracocentesis performed at Cornell
- Cardiac tamponade, CBC/Chemistry are unremarkable

ULTRASONOGRAPHIC EXAMINATION OF THE ABDOMEN

Urinary System

The **urinary bladder**, trigone, and pelvic urethra presented normal thicknesses and normal tone. The ureters were not visible which is normal. No uroliths or sediment were visualized and anechoic urine was present. No evidence of inflammatory or neoplastic changes was noted. Ureteral papillae were normal.

The **kidneys** revealed normal size and structure, corticomedullary definition and ratio for this age. The cortices presented largely uniform texture with normal echogenic relationship to liver and spleen. Medullary structure differed distinctly from the cortex and no evidence of pelvic dilation was present. The capsules were acceptably uniform without significant irregularities. The left kidney measured 4.1 cm. The right kidney measured 3.9 cm.

Adrenal Glands

The **left adrenal gland** was visualized and recognized as having normal shape, size, position and echogenicity for this breed. The phrenic vasculature, glandular echogenicity and detail were unremarkable. Capsule, cortex, and medullary definition were normal for this age patient. The left adrenal gland measured 0.5 cm. The region of the **right adrenal gland** was imaged with no evidence of pathology.

Spleen

The **spleen** presented a smooth homogeneous parenchyma hyperechoic to liver and renal cortical parenchyma. The capsule was smooth without noticeable expansion or deviation from within the spleen or adjacent pathology. The splenic vasculature demonstrated normal volume without signs of congestion or thrombosis. No sonographic evidence of acute or chronic inflammatory, neoplastic, or infarctual changes was noted.

Liver

The **liver** images from right and left intercostal as well as subcostal views revealed subjectively normal liver size, contour, and structure. Some age-related parenchymal remodeling was noted but likely not clinically significant at this time. Vascular and biliary tracts were of normal volume and no evidence of congestion was noted. The gallbladder presented some dependent debris with essentially normal contour. The cystic and common bile ducts were normal. No overt evidence of active inflammatory,



PATIENT

Sammie Fitzgerald

SPECIES

Canine

BREED

Jack Russell Terrier

SEX

Spayed female

AGE

12 years

WEIGHT

15.2 lbs

INTERPRETED BY

Eric Lindquist, DMV
DABVP, Cert. IVUSS

IMAGING PERFORMED BY

Jenny Wenrich DVM

HOSPITAL NAME

Straley VA

REFERRING VET

Dr. Wenrich

INVOICE

73514

DATE

3/17/26

infiltrative or regenerative pathology was noted but should be paired with current or past LE elevations regarding any clinical significance to this presentation. The hepatic lymph nodes were unremarkable. Pleural effusion was noted through the diaphragm.

Gastrointestinal

There was some residual chyme and gas was noted in the **stomach**, yet not pathological. This is consistent with post prandial presentation. Transit of chyme into the small intestine was normal. Curvilinear patterns were maintained throughout the GI tract. No evidence of pathology. Small and large intestine demonstrated normal luminal chyme and stool consistency respectively. No obstructive or overt infiltrative disease was noted. No associated abnormal lymphatic activity was noted.

Pancreas

The base and limbs of the **pancreas** were observed to be largely isoechoic to surrounding omental fat. Pancreatic duct and capsular contour were acceptably normal and parenchyma respected normal curvilinear patterns. No overt evidence of active inflammatory or neoplastic disease was noted.

Thorax

Slight pericardial effusion was noted as well. Lung consolidation was noted. Strong concern for neoplastic process in the chest.

ULTRASONOGRAPHIC FINDINGS

Unremarkable abdomen.

INTERPRETATION OF THE FINDINGS & FURTHER RECOMMENDATIONS

Chest radiographs and echocardiogram and intercostal approach to the thorax is warranted.



PATIENT

Sammie Fitzgerald

SPECIES

Canine

BREED

Jack Russell Terrier

SEX

Spayed female

AGE

12 years

WEIGHT

15.2 lbs

INTERPRETED BY

Eric Lindquist, DMV
DABVP, Cert. IVUSS

IMAGING PERFORMED BY

Jenny Wenrich DVM

HOSPITAL NAME

Straley VA

REFERRING VET

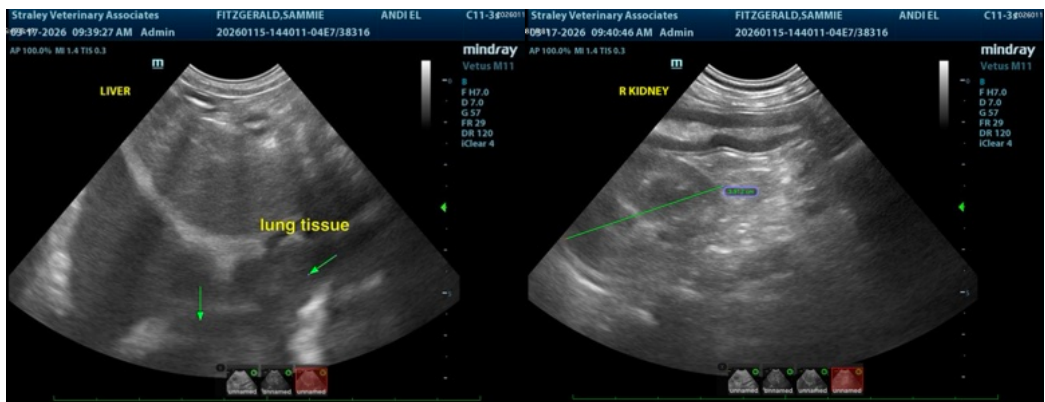
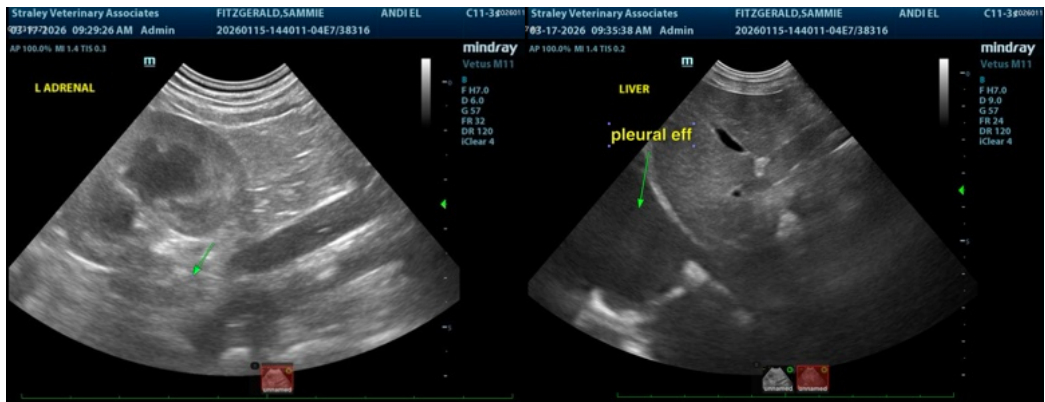
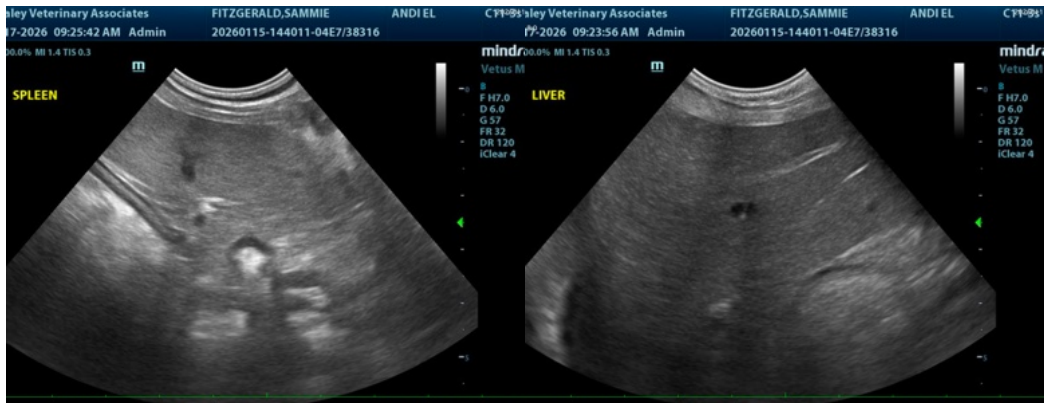
Dr. Wenrich

INVOICE

73514

DATE

3/17/26



The information and recommendations provided are based on the images presented by the referring veterinarian/sonographer. No evaluation can be communicated regarding pathology that was not visible in the image/video clips provided.

Thank you for this referral. If the clinical or image interpretation does not parallel your findings or if I can be of any further assistance please contact me.

Eric Lindquist, DMV, DABVP (CFM), Cert. IVUSS, CEO of SonoPath.com

info@SonoPath.com