



## PATIENT

Riley Schraufnagel

## SPECIES

Canine

## BREED

English Setter

## SEX

Neutered male

## AGE

13 years

## WEIGHT

56 lbs

## INTERPRETED BY

Eric Lindquist, DMV  
DABVP, Cert. IVUSS

## IMAGING PERFORMED BY

Jill Rumachik

## HOSPITAL NAME

Clarity Imaging LLC

## REFERRING VET

Dr. Mabie

## INVOICE

73517

## DATE

3/17/26

## PRESENTING CLINICAL SIGNS

- Grade 4/6 murmur -- occasional coughing/hacking

## ULTRASONOGRAPHIC EXAMINATION OF THE HEART

The echocardiogram in this patient demonstrated normal **left atrial** size based on 3 different LA measurement methods. Chamber volumes and echogenicity were normal. The cranial and caudal **mitral** valve leaflets presented vegetative thickening consistent with endocardiosis. Doppler indicated measurable insufficiency. The **left ventricle** presented thicknesses with linear contour and was not dilated nor restricted. The **myocardium** presented normal echogenicity without subjective evidence of significant fibrotic or ischemic disease. **Contractility** of the ventricular walls was adequate and in normal range for this patient evidenced by the fractional shortening measurement and subjective evaluation of the different regions of the myocardium. Minor **aortic** insufficiency was noted. The **right atrium** and auricle revealed normal size, structure and content. No evidence of masses was noted or chamber overload. **Tricuspid** valvular assessment demonstrated adequate linear morphology. The **right ventricle** was of normal size (1/3 diameter of LV), chordae structure, myocardial echogenicity and thickness. **Pulmonic** tract assessment revealed normal valve structure, laminar flow, and diameter (approx. 1:1 pa/ao ratio). No visible **pericardial** or free pleura fluid was noted. No echographically detectable evidence of infiltrative disease was visible. The cranial **mediastinum and pericardial regions** were free of masses in the visible window.

CANINE CARDIAC PARAMETERS	MR VMAX (m/s)	TR VMAX (m/s)	LA/AO	LA/AO (Heart Base)	FS (%)	EF (%)	EPSS (cm)
NORMAL PARAMETER	4.5-5.5	<2.7	1.3	<1.6	28-40	40-100	<0.6
PATIENT	-	-	1.1	1.3	35	80	0.1
CANINE CARDIAC PARAMETERS	HR (BPM)	AV VMAX (m/s)	PV MAX (m/s)	BODY WEIGHT	LA 2D short axis Base view (cm)	LVIDd Avg; 2D and m-mode short axis (cm)	LVIDs Avg; 2D and m-mode short axis (cm)
NORMAL PARAMETER	50-100	0.7-1.7	0.7-1.6	BELOW	BELOW	BELOW	BELOW
PATIENT	-	1.2	2.0	56 lbs	2.5	2.4	

## ULTRASONOGRAPHIC FINDINGS

Mitral, aortic and pulmonic insufficiency with normal volumes.



## PATIENT

Riley Schraufnagel

## SPECIES

Canine

## BREED

English Setter

## SEX

Neutered male

## AGE

13 years

## WEIGHT

56 lbs

## INTERPRETED BY

Eric Lindquist, DMV  
DABVP, Cert. IVUSS

## IMAGING PERFORMED BY

Jill Rumachik

## HOSPITAL NAME

Clarity Imaging LLC

## REFERRING VET

Dr. Mabie

## INVOICE

73517

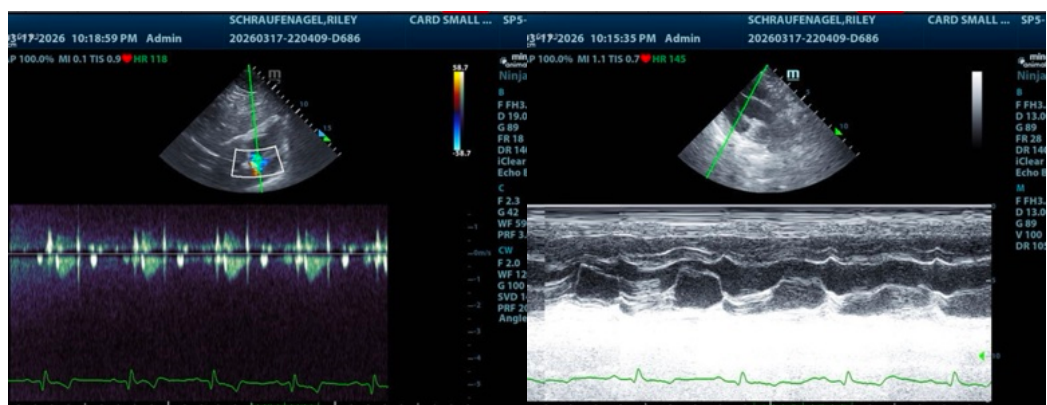
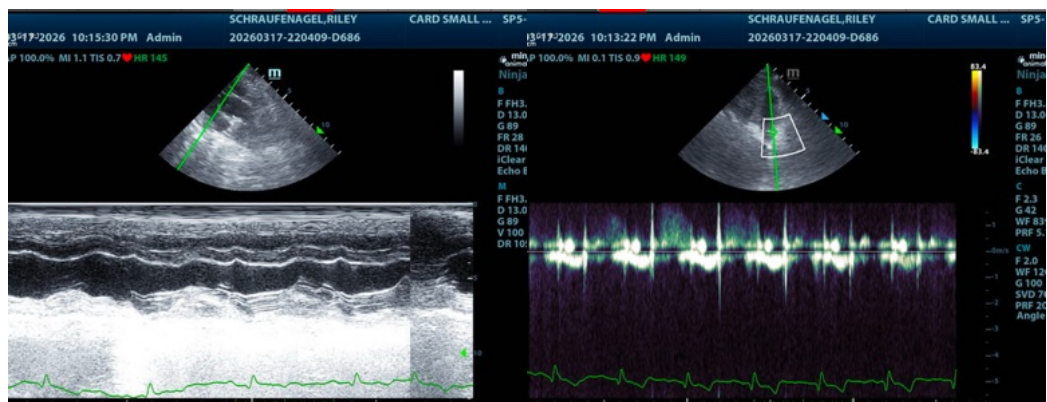
## DATE

3/17/26

## INTERPRETATION OF THE FINDINGS & FURTHER RECOMMENDATIONS

The cough is not cardiogenic despite the presence of valvular disease. Inspiratory and expiratory radiographs are warranted upon the trachea to ensure that tracheal collapse is not an issue. Management is recommended based on clinical signs and radiographs. Bronchoscopy may be appropriate, yet the heart is not a clinical player at this time.

The heart is stable without clinical disease. No overt contraindication for anesthesia of brief to moderate duration. I suggest Torbutrol premed, Propofol induction, Isoflor maintenance or similar protocol if anesthesia is desired. Blood pressure recommended if not already performed and target white coat negative systolic pressure of < 160 mmHg. If higher than this ACE-inhibitor is suggested to reach this level. Recheck echocardiogram is recommended in 6 months, earlier if murmur grade increases or clinical signs initiate.





## PATIENT

Riley Schraufnagel

## SPECIES

Canine

## BREED

English Setter

## SEX

Neutered male

## AGE

13 years

## WEIGHT

56 lbs

## INTERPRETED BY

Eric Lindquist, DMV  
DABVP, Cert. IVUSS

## IMAGING PERFORMED BY

Jill Rumachik

## HOSPITAL NAME

Clarity Imaging LLC

## REFERRING VET

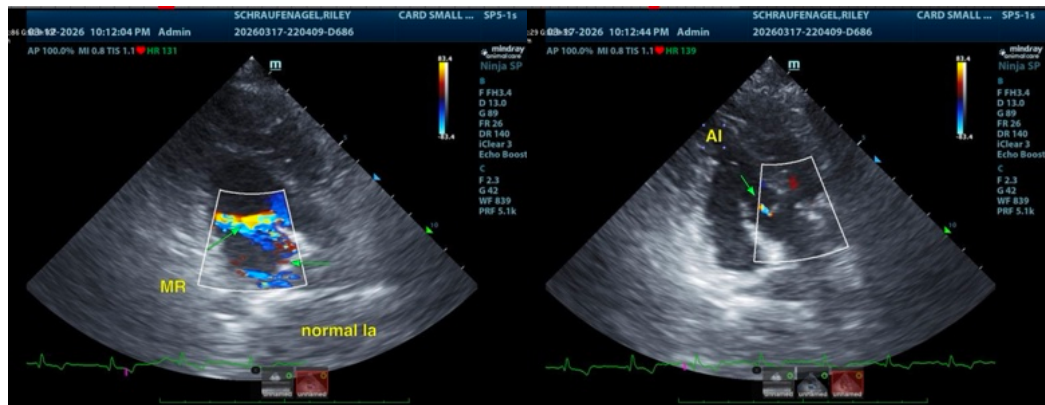
Dr. Mabie

## INVOICE

73517

## DATE

3/17/26



The information and recommendations provided are based on the images presented by the referring veterinarian/sonographer. No evaluation can be communicated regarding pathology that was not visible in the image/video clips provided.

Thank you for this referral. If the clinical or image interpretation does not parallel your findings or if I can be of any further assistance please contact me.

Eric Lindquist, DMV, DABVP (CFM), Cert. IVUSS, CEO of SonoPath.com

[info@SonoPath.com](mailto:info@SonoPath.com)