



PATIENT

Laggy Gatter

SPECIES

Canine

BREED

Siberian Husky

SEX

Spayed female

AGE

6 years

WEIGHT

37.8 kg

INTERPRETED BY

Eric Lindquist, DMV
DABVP, Cert. IVUSS

IMAGING PERFORMED BY

Maria Lara, DVM

HOSPITAL NAME

Allure VH & Urgent
Care

REFERRING VET

Dr. Lara

INVOICE

73481

DATE

3/17/26

PRESENTING CLINICAL SIGNS

- Patient presented 2/16 with blood shot eyes, iris change color from blue to white, decreased to absent appetite and enlarged lymph nodes - submandibular, suprascapular and popliteal.
- Patient was prescribed prednisone at that time by rDVM which improved appetite and decreased size of LNs.
- Initial cytology revealed : Reactive lymphoid hyperplasia Tick Born Disease Panel showed seropositive Bartonella but PCR was negative. Flow Cytometry pending.

ULTRASONOGRAPHIC EXAMINATION OF THE ABDOMEN

Urinary System

The **urinary bladder**, trigone, and pelvic urethra presented normal thicknesses and normal tone. The pelvic urethra was imaged 2.0 cm beyond the cystourethral junction and appeared normal. The ureters were not visible which is normal. No uroliths or sediment were visualized and anechoic urine was present. No evidence of inflammatory or neoplastic changes was noted. Ureteral papillae were normal.

The **kidneys** revealed normal size and structure, corticomedullary definition and ratio for this age. The cortices presented largely uniform texture with normal echogenic relationship to liver and spleen. Medullary structure differed distinctly from the cortex and no evidence of pelvic dilation was present. The capsules were acceptably uniform without significant irregularities. The left kidney measured 5.93 cm. The right kidney measured 6.24 cm.

Adrenal Glands

Both **adrenal glands** were visualized and recognized as having normal shape, size, position and echogenicity for this breed. The phrenic vasculature, glandular echogenicity and detail were unremarkable. Capsule, cortex, and medullary definition were normal for this age patient. The left adrenal gland measured 0.32 cm at the caudal pole and 0.31 cm at the cranial pole. The right adrenal gland measured

Spleen

The **spleen** presented a smooth homogeneous parenchyma hyperechoic to liver and renal cortical parenchyma. The capsule was smooth without noticeable expansion or deviation from within the spleen or adjacent pathology. The splenic vasculature demonstrated normal volume without signs of congestion or thrombosis. No sonographic evidence of acute or chronic inflammatory, neoplastic, or infarctual changes was noted.

Liver

The **liver** images submitted revealed subjectively normal liver size, contour, and structure. Parenchymal echogenicity was naturally coarse and hypoechoic to the spleen. Vascular and biliary tracts were of normal volume with no evidence of congestion. The gallbladder presented acceptably thin walls with primarily anechoic content. The cystic and common bile ducts were normal. No pathological hepatic



PATIENT

lymphadenopathy was evident. No overt structural evidence of inflammatory, infiltrative or regenerative pathology was evident.

Laggy Gatter

SPECIES

Gastrointestinal

Canine

Examination of the **gastrointestinal tract** revealed a stomach and intestine free of stasis, of normal wall thickness, acceptable curvilinear mural detail, and peristaltic activity. Small and large intestine demonstrated normal luminal chyme and stool consistency respectively. No obstructive or overt infiltrative disease was noted. No associated abnormal lymphatic activity was noted.

BREED

Siberian Husky

SEX

Pancreas

Spayed female

The base and limbs of the **pancreas** were observed to be largely isoechoic to surrounding omental fat. Pancreatic duct and capsular contour were acceptably normal and parenchyma respected normal curvilinear patterns. No overt evidence of active inflammatory or neoplastic disease was noted.

AGE

6 years

WEIGHT

ULTRASONOGRAPHIC FINDINGS

37.8 kg

Structurally unremarkable abdomen.

INTERPRETED BY

Eric Lindquist, DMV
DABVP, Cert. IVUSS

INTERPRETATION OF THE FINDINGS & FURTHER RECOMMENDATIONS

There was no evidence of visceral pathology.

IMAGING PERFORMED BY

Maria Lara, DVM

HOSPITAL NAME

Allure VH & Urgent
Care

REFERRING VET

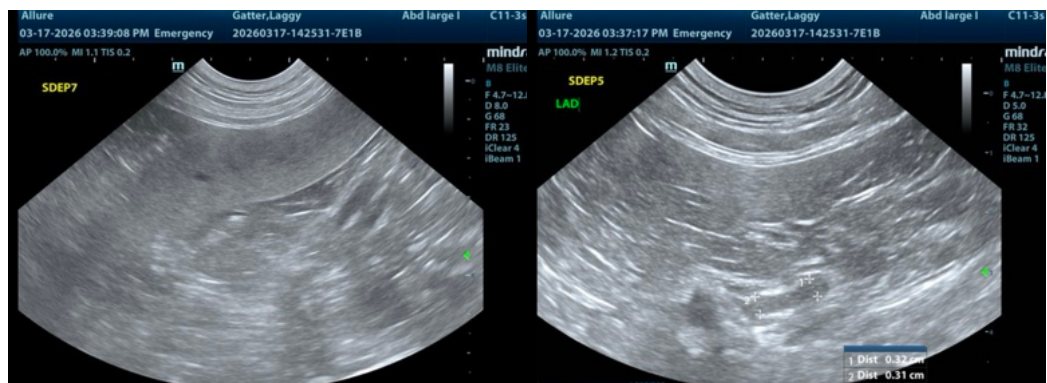
Dr. Lara

INVOICE

73481

DATE

3/17/26





PATIENT

Laggy Gatter

SPECIES

Canine

BREED

Siberian Husky

SEX

Spayed female

AGE

6 years

WEIGHT

37.8 kg

INTERPRETED BY

Eric Lindquist, DMV
DABVP, Cert. IVUSS

IMAGING PERFORMED BY

Maria Lara, DVM

HOSPITAL NAME

Allure VH & Urgent
Care

REFERRING VET

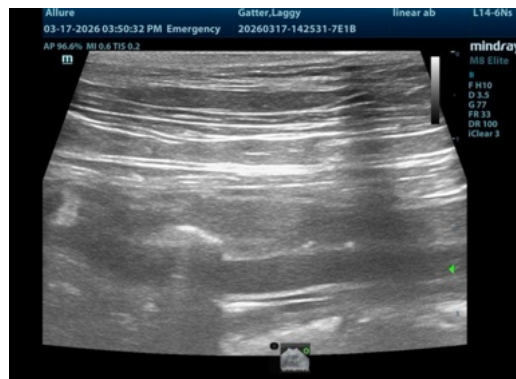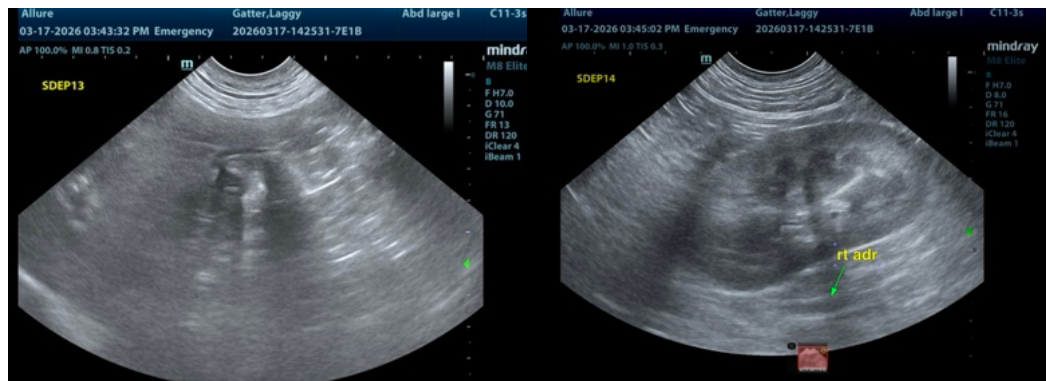
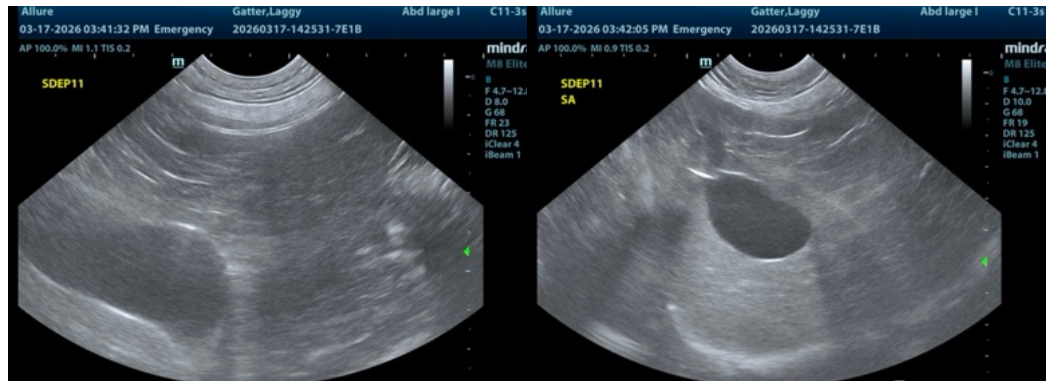
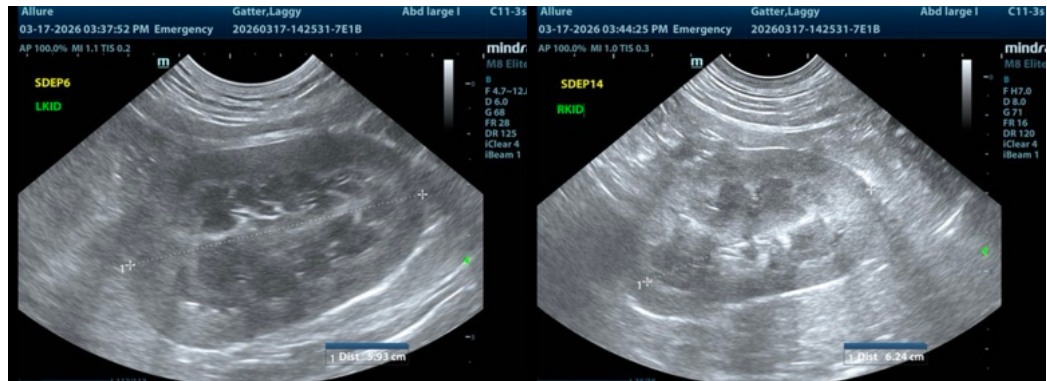
Dr. Lara

INVOICE

73481

DATE

3/17/26





PATIENT

Laggy Gatter

SPECIES

Canine

BREED

Siberian Husky

SEX

Spayed female

AGE

6 years

WEIGHT

37.8 kg

INTERPRETED BY

Eric Lindquist, DMV
DABVP, Cert. IVUSS

IMAGING PERFORMED BY

Maria Lara, DVM

HOSPITAL NAME

Allure VH & Urgent
Care

REFERRING VET

Dr. Lara

INVOICE

73481

DATE

3/17/26

The information and recommendations provided are based on the images presented by the referring veterinarian/sonographer. No evaluation can be communicated regarding pathology that was not visible in the image/video clips provided.

Thank you for this referral. If the clinical or image interpretation does not parallel your findings or if I can be of any further assistance please contact me.

Eric Lindquist, DMV, DABVP (CFM), Cert. IVUSS, CEO of SonoPath.com

info@SonoPath.com