

PATIENT PRESENTING CLINICAL SIGNS

Gunny Hall Not included on form.

SPECIES Abnormal PE/Chem/CBC/UA Results: PE: mm pink, CRT <2 sec, BAR, BCS 3/5 CBC- WBC 18.5, lymphs- 7280, put 599, VetScreen- ALT 232 ALKP 1425 Calcium 14.5

Canine

ULTRASONOGRAPHIC EXAMINATION OF THE ABDOMEN

BREED *Urinary System*

Terrier x

The **urinary bladder**, trigone, and pelvic urethra presented normal thicknesses and normal tone. The ureters were not visible which is normal. No uroliths or sediment were visualized and anechoic urine was present. No evidence of inflammatory or neoplastic changes were noted. Ureteral papillae were normal. The pelvic urethra was imaged 3.0 cm beyond the cystourethral junction.

SEX

Neutered Male

The residual prostate was uniform at 0.68 cm.

AGE

11.6 Years

The **kidneys** revealed normal size and structure, corticomedullary definition and ratio for this age. The cortices presented largely uniform texture with normal echogenic relationship to liver and spleen. Medullary structure differed distinctly from the cortex and no evidence of pelvic dilation was present. The capsules were acceptably uniform without significant irregularities. Left kidney measured 5.9 cm. Right kidney measured 6.82 cm.

WEIGHT

31.5 lbs

Adrenal Glands

INTERPRETED BY

Eric Lindquist, DMV, DABVP (CFM), Cert. IVUSS

The **right adrenal gland** was visualized and recognized as having normal shape, size, position and echogenicity for this breed. The phrenic vasculature, glandular echogenicity and detail were unremarkable. Capsule, cortex, and medullary definition were normal for this age patient. Right measured 2.11 cm x 0.52 cm at the cranial pole and 0.52 cm at the caudal pole.

IMAGING PERFORMED BY

Ginny Dodd, DVM, D, ABVP-CFP

The **left adrenal gland** was slightly heterogeneous and measured at the upper limits of normal at 0.80 cm at the caudal pole and 0.53 cm at the cranial pole.

HOSPITAL NAME

Steele Creek Animal Hospital

Spleen

The **spleen** was largely smooth with subtle heterogeneous parenchymal changes while maintaining normal echogenic relationship to the liver and kidney. These changes are consistent with normal age-related alteration. The capsule was smooth without noticeable impingement from within the spleen or from pathology in the adjacent abdomen. The splenic vasculature demonstrated normal volume without signs of congestion or significant contraction. No evidence of active acute or chronic inflammatory, neoplastic, or infarctual changes were noted.

REFERRING VET

Dr. Daniels

Liver

INVOICE

73740

The **liver** images from right and left intercostal as well as subcostal views revealed subjectively normal liver size, contour, and structure. Some age-related parenchymal remodeling was noted but likely not clinically significant at this time. Vascular and biliary tracts were of normal volume and no evidence of congestion was noted. Minor gallbladder sediment noted, not pathological.

DATE

3/17/26

Gastrointestinal

The **stomach** itself was unremarkable. Intestinal speckling noted in the small intestine. This is an idiopathic finding.



PATIENT

Gunny Hall

SPECIES

Canine

BREED

Terrier x

SEX

Neutered Male

AGE

11.6 Years

WEIGHT

31.5 lbs

INTERPRETED BY

Eric Lindquist, DMV,
 DABVP (CFM), Cert.
 IVUSS

IMAGING PERFORMED BY

Ginny Dodd, DVM, D,
 ABVP-CFP

HOSPITAL NAME

Steele Creek Animal
 Hospital

REFERRING VET

Dr. Daniels

INVOICE

73740

DATE

3/17/26

A mesenteric lymph node was mildly enlarged, reactive, measuring 2.0 cm x 0.64 cm. Heterogeneous, hypochoic nodules were noted within the node.

Pancreas

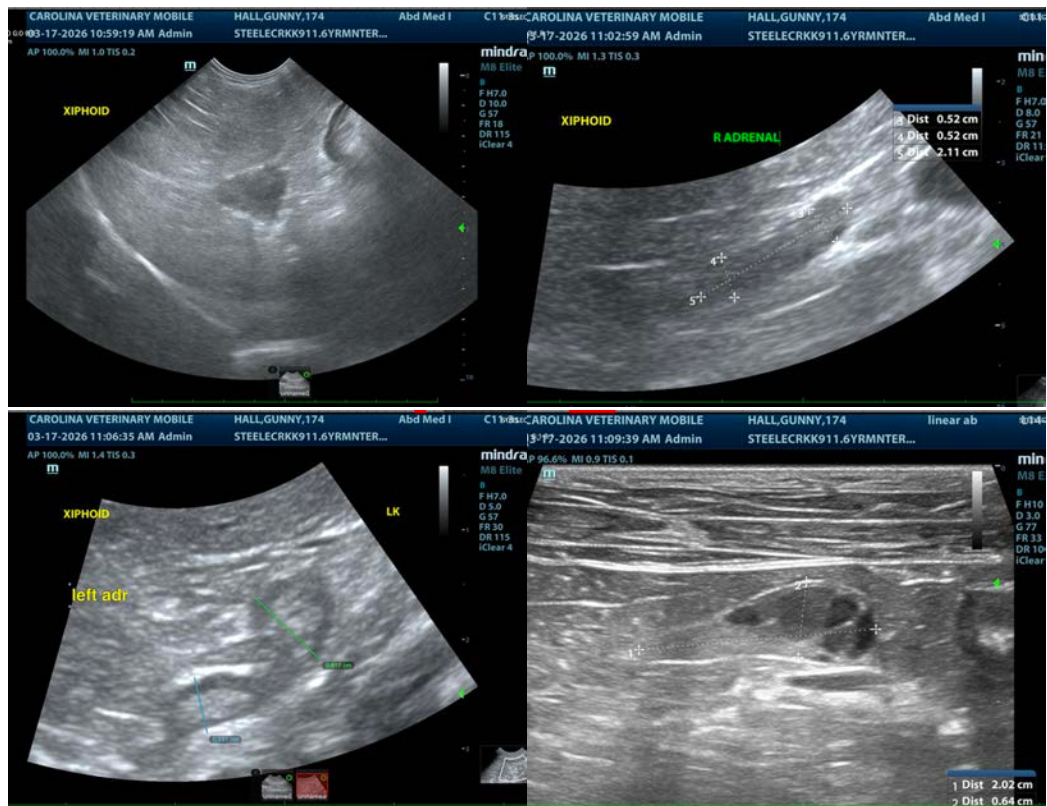
The base and limbs of the **pancreas** were observed to be largely isoechoic to surrounding omental fat. Pancreatic duct and capsular contour were acceptably normal and parenchyma respected normal curvilinear patterns. No overt evidence of active inflammatory or neoplastic disease was noted.

ULTRASONOGRAPHIC FINDINGS

- Slightly heterogeneous left adrenal gland.
- Slight intestinal speckling.
- Minor reactive mesenteric lymph nodes.
- Geriatric abdomen otherwise.

INTERPRETATION OF THE FINDINGS & FURTHER RECOMMENDATIONS

No evidence of significant disease. FNA of the liver could be considered for further definition. No evidence of pathology related to the hypercalcemia. Chest radiographs, anal gland palpation +/- ultrasound imaging +/- para thyroid ultrasound may all be indicated.





PATIENT

Gunny Hall

SPECIES

Canine

BREED

Terrier x

SEX

Neutered Male

AGE

11.6 Years

WEIGHT

31.5 lbs

INTERPRETED BY

Eric Lindquist, DMV,
 DABVP (CFM), Cert.
 IVUSS

IMAGING PERFORMED BY

Ginny Dodd, DVM, D,
 ABVP-CFP

HOSPITAL NAME

Steele Creek Animal
 Hospital

REFERRING VET

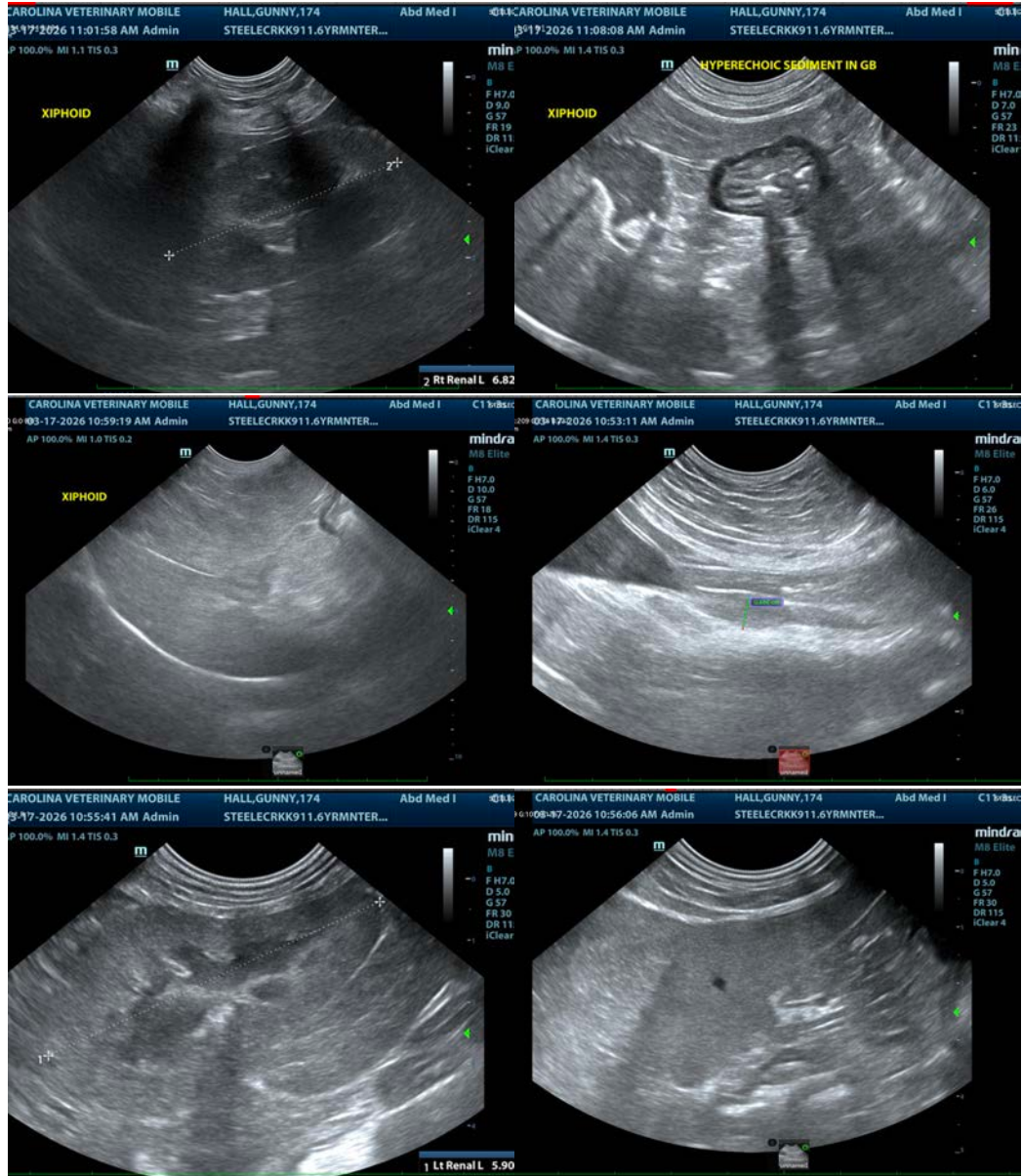
Dr. Daniels

INVOICE

73740

DATE

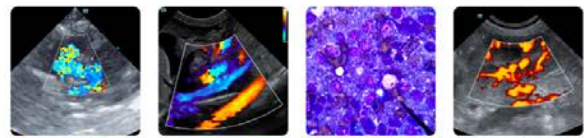
3/17/26



The information and recommendations provided are based on the images presented by the referring veterinarian/sonographer. No evaluation can be communicated regarding pathology that was not visible in the image/video clips provided.

Thank you for this referral. If the clinical or image interpretation does not parallel your findings or if I can be of any further assistance please contact me.

Eric Lindquist, DMV, DABVP(CFM), Cert. IVUSS,
 CEO, Owner, Founder -- SonoPath.com
info@SonoPath.com



PATIENT

Gunny Hall

SPECIES

Canine

BREED

Terrier x

SEX

Neutered Male

AGE

11.6 Years

WEIGHT

31.5 lbs

INTERPRETED BY

Eric Lindquist, DMV,
 DABVP (CFM), Cert.
 IVUSS

IMAGING PERFORMED BY

Ginny Dodd, DVM, D,
 ABVP-CFP

HOSPITAL NAME

Steele Creek Animal
 Hospital

REFERRING VET


Dr. Daniels

INVOICE

73740

DATE

3/17/26



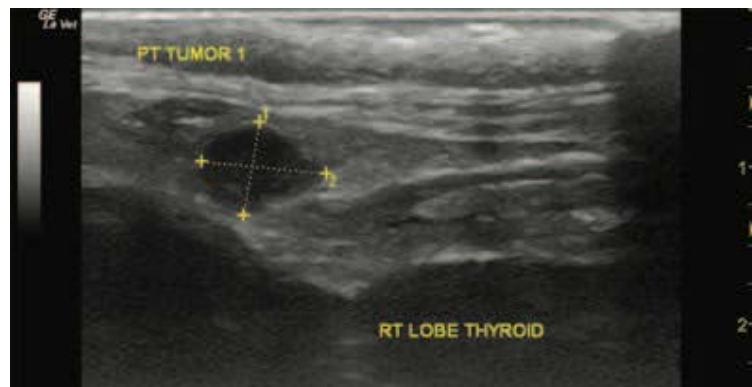The following is an applicable excerpt from the *Curbside Guide to Diagnosis & Treatment of Sonographic Disease* offered by [SonoPath.com](http://sonopath.com) Lindquist, Frank, Lobetti, and Modler.

An essential quick guide for every general practitioner and sonographer.

<https://sonopath.com/products/curbside-guide-editing-due-release-12012015>

CANINE HYPERCALCEMIA

<http://www.sonopath.com/CanineHypercalcemia>

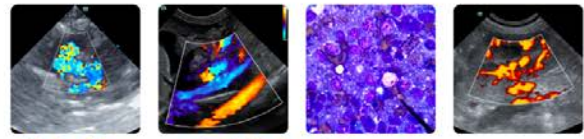


Long axis of the right thyroid lobe in a dog with a parathyroid adenoma. The right internal parathyroid gland (between calipers) shows severe uniform enlargement of more than 7mm.

Description: Hypercalcemia is defined as either a persistently elevated total calcium serum (> 12 mg/dl) or ionized calcium (> 1.45 mmol/l) concentration. Clinical signs are often absent with mild hypercalcemia (< 13 mg/dl). In fact, hypercalcemia is often only discovered when serum biochemistry is done for unrelated reasons. Clinical signs are usually mild when the serum calcium concentration is less than 14 mg/dl; however, signs become more readily apparent when the concentration exceeds 15 mg/dl. Life-threatening cardiac arrhythmias can develop when the serum calcium exceeds 18 mg/dl.

Common etiologies of hypercalcemia include humoral hypercalcemia of malignancy (HHM), hypoadrenocorticism, chronic kidney disease (CKD), hypervitaminosis D, and primary hyperparathyroidism. Less common etiologies include bone neoplasia, osteomyelitis, hypertrophic osteodystrophy, granulomatous disease, calcium supplementation, and oral phosphate binders.

Clinical Signs: Common clinical signs include polyuria, polydipsia, lethargy, inappetence, and weakness. With chronic hypercalcemia, calcium oxalate and calcium phosphate uroliths can form, resulting in clinical signs suggestive of lower urinary tract disease. Systemic signs of illness are suggestive of HHM.



PATIENT

Gunny Hall

SPECIES

Canine

BREED

Terrier x

SEX

Neutered Male

AGE

11.6 Years

WEIGHT

31.5 lbs

INTERPRETED BY

Eric Lindquist, DMV,
 DABVP (CFM), Cert.
 IVUSS

IMAGING PERFORMED BY

Ginny Dodd, DVM, D,
 ABVP-CFP

HOSPITAL NAME

Steele Creek Animal
 Hospital

REFERRING VET

Dr. Daniels

INVOICE

73740

DATE

3/17/26

Diagnosics: One important etiology of hypercalcemia is laboratory error; therefore, hypercalcemia should always be confirmed before embarking on any further diagnostic evaluation. Results of a CBC, serum biochemistry panel, and urinalysis, in conjunction with a patient history and findings from a physical examination, can often provide enough information to arrive at a diagnosis. The appendicular skeleton, peripheral lymph nodes, abdominal cavity, and rectum should all be carefully palpated for masses, lymphadenopathy, hepatomegaly, splenomegaly, and/or pain in the long bones. The following diagnostic tests are helpful for identifying an underlying malignancy: thoracic and abdominal radiographs; abdominal ultrasound; cytological evaluation of aspirates of the liver, spleen, lymph nodes, and bone marrow; determination of serum ionized calcium, parathyroid hormone (PTH), and parathyroid hormone-related protein concentration (PTHrP); and ultrasound of the neck. Ascertaining the concentrations of serum ionized calcium, PTH, and PTHrP helps differentiate primary hyperparathyroidism from HHM. The finding of one or more enlarged parathyroid glands upon conducting an ultrasound of the neck supports a diagnosis of primary hyperparathyroidism.

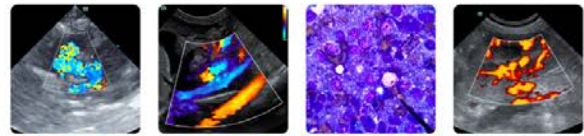
Hypoadrenocorticism-induced hypercalcemia usually occurs in conjunction with hyponatremia, hyperkalemia, and prerenal azotemia. With HHM and primary hyperparathyroidism, serum phosphorus concentration is often in the low to low-normal reference range. If the serum phosphorus concentration is high but kidney function is normal, hypervitaminosis D or osteolysis should be suspected.

It can be difficult to determine whether kidney failure is primary or secondary to hypercalcemia when hyperphosphatemia and hypercalcemia coexist with azotemia. Serum ionized calcium concentrations are typically normal or decreased in cases of renal failure and increased in cases of hypercalcemia caused by other disorders.

Sternal and hilar lymphadenopathy is common with lymphoma-induced hypercalcemia and can be readily identified on thoracic radiographs. In cases of multiple myeloma, discrete lytic lesions in the vertebrae or long bones, hyperproteinemia, proteinuria, and plasma cell infiltration in the bone marrow may be present. Cytological evaluation of the peripheral lymph nodes, bone marrow, and spleen can be helpful in identifying lymphoma.

Increased serum ionized calcium concentrations, detectable serum PTHrP concentrations, and non-detectable serum PTH concentrations are all diagnostic for HHM. Lymphoma is the most common etiology of HHM, but other tumors, such as apocrine gland adenocarcinoma and various carcinomas (e.g. mammary gland, squamous cell, bronchogenic), can all give rise to hypercalcemia. Increased serum ionized calcium, normal to increased serum PTH, and non-detectable PTHrP concentrations are diagnostic of primary hyperparathyroidism.

Differentials for Hypercalcemia: “HARD IONS”



PATIENT

Hyperparathyroid

Gunny Hall

Addison's

SPECIES

Renal

Canine

D-toxicity

Idiopathic

BREED

Osteolytic

Terrier x

Neoplastic

SEX

Spurious

Neutered Male

AGE

PTH tumor: Elevated total and ionized Ca, low PTHrP, and normal/high PTH. Keeshonds, German Shepherds, and Golden Retrievers are all predisposed.

11.6 Years

Addison's disease: Elevated total and normal ionized Ca, elevated BUN, hypoalbuminemia and hyperkalemia.

WEIGHT

31.5 lbs

Renal failure: Elevated to normal total Ca, low ionized Ca, low PTHrP, elevated PTH, azotemia, and low urine specific gravity.

INTERPRETED BY

Vitamin D toxicity: Elevated total and ionized Ca, low PTHrP, and normal/low PTH.

Eric Lindquist, DMV,
 DABVP (CFM), Cert.
 IVUSS

Hypercalcemia of malignancy (HHM): Elevated total and ionized Ca, high PTHrP, and low PTH.

IMAGING PERFORMED BY

Granulomatous disease: Elevated total and ionized Ca, low PTHrP, and low PTH.

Ginny Dodd, DVM, D,
 ABVP-CFP

Renal failure: Elevated to normal total Ca, low ionized Ca, low PTHrP, elevated PTH, azotemia, and low urine specific gravity.

HOSPITAL NAME

Steele Creek Animal
 Hospital

Treatment: Therapies for hypercalcemia are aimed at correcting the underlying etiology; however, because prolonged hypercalcemia can result in kidney damage, the use of fluid therapy, furosemide, and possibly prednisone is indicated in all cases to reduce serum calcium levels. Suggested dosages include saline (0.9% 120-180 ml/kg day IV), furosemide (1-4 mg/kg PO TID), and prednisone (0.25 mg/kg PO Q24hr).

REFERRING VET

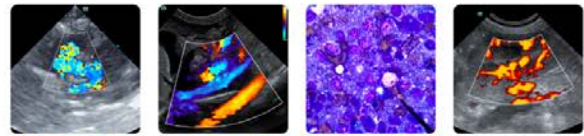
Dr. Daniels

INVOICE

73740

DATE

3/17/26



PATIENT

Gunny Hall

SPECIES

Canine

BREED

Terrier x

SEX

Neutered Male

AGE

11.6 Years

WEIGHT

31.5 lbs

INTERPRETED BY

Eric Lindquist, DMV,
DABVP (CFM), Cert.
IVUSS

IMAGING PERFORMED BY

Ginny Dodd, DVM, D,
ABVP-CFP

HOSPITAL NAME

Steele Creek Animal
Hospital

REFERRING VET

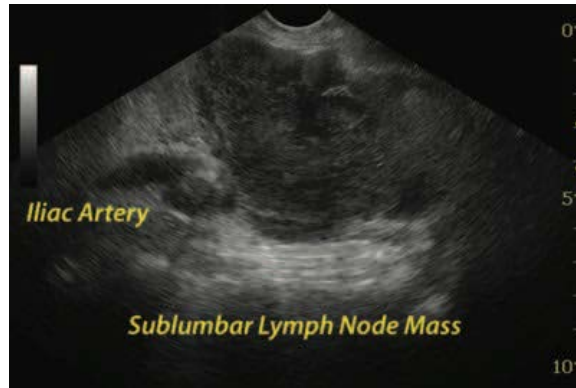
Dr. Daniels

INVOICE

73740

DATE

3/17/26



Long axis of the left hypogastric lymph node in a hypercalcemic dog with lymphoma and hypercalcemia of malignancy. The lymph node is severely enlarged and rounded with a short-to-long-axis ratio > 0.5 indicating malignant infiltration. The regular echoarchitecture is lost, the hilus is not recognized, lymph node parenchyma is hypoechoic and heterogeneous. Also note the mass effect on the external iliac artery. In light of hypercalcemia, lymphadenopathy in this region could also be owing to anal gland adenocarcinoma which can also be imaged sonographically.

References:

Chew DJ, Schenck PA, Jaege JQ. Clinical disorders of hypercalcemia and hypocalcemia in dogs and cats. Proceedings from the American College of Veterinary Internal Medicine, Charlotte, NC, June 4-7, 2003.

Feldman EC. Disorders of the parathyroid glands. In: Ettinger SJ, Feldman EC, ed. *Textbook of Veterinary Internal Medicine, 7th ed.* St. Louis, MO: Saunders Elsevier; 2010:1722-50.

Peterson ME. Hypercalcemia in dogs & cats: differential diagnosis & treatment. Proceedings from the Western Veterinary Conference, Las Vegas, NV, February 19-23, 2012.