



## PATIENT

Daisy Murphy

## SPECIES

Canine

## BREED

Hound Mix

## SEX

Spayed Female

## AGE

13 Years

## WEIGHT

74.6 pounds

## INTERPRETED BY

Eric Lindquist, DMV,  
DABVP(CFM), Cert.  
IVUSS

## IMAGING PERFORMED BY

Dr. Elaina Petrone

## HOSPITAL NAME

Long Branch Animal  
Hospital

## REFERRING VET

Dr. Elaina Petrone

## INVOICE

14394

## DATE

03/17/26

## PRESENTING CLINICAL SIGNS

- Suspect mammary mass.
- CXR-met check
- AUS-met check

## ULTRASONOGRAPHIC EXAMINATION OF THE HEART & ABDOMEN

CANINE CARDIAC PARAMETERS	MR VMAX (m/s)	TR VMAX (m/s)	LA/AO (M-Mode)	LA/AO (Heart Base; Swe)	FS (%)	EF (%)	EPSS (cm)
NORMAL PARAMETER	4.5-5.5	<2.7	1.3	Up to 1.6	28-40	40-100	<0.6
PATIENT	5.0	2.8	1.5	--	35	--	NM
CANINE CARDIAC PARAMETERS	HR (BPM)	AV VMAX (m/s)	PV MAX (m/s)	BODY WEIGHT (lbs)	LAD LA MAX 4 Chamber	LVIDd Avg; 2D and m-mode short axis (cm)	LVIDs Avg; 2D and m-mode short axis (cm)
NORMAL PARAMETER	50-100	0.7-1.7	0.7-1.6				
PATIENT	80	--	0.60	74.6	5.2	3.9	--

### Cardiac Presentation

The **left atrium** was mildly enlarged in this patient. Chamber volumes and echogenicity were normal. The cranial and caudal **mitral** valve leaflets presented vegetative thickening consistent with endocardiosis. Doppler indicated measurable insufficiency. The **left ventricle** presented normal thicknesses with linear contour and was not dilated nor restricted. The **myocardium** presented normal echogenicity without subjective evidence of significant fibrotic or ischemic disease. **Contractility** of the ventricular walls was adequate and in normal range for this patient evidenced by the fractional shortening measurement and subjective evaluation of the different regions of the myocardium. The **left ventricular outflow** tract demonstrated normal laminar flow and subjective structural integrity. The **right atrium** and auricle revealed normal size, structure and content. No evidence of masses was noted or chamber overload. **Tricuspid** valvular assessment demonstrated adequate linear morphology. The **right ventricle** was of normal size (1/3 diameter of LV), chordae structure, myocardial echogenicity and thickness. **Pulmonic** insufficiency was noted. No visible **pericardial** or free pleura fluid was noted. No echographically detectable evidence of infiltrative disease was visible. The cranial **mediastinum and pericardial regions** were free of masses in the visible window.

### Urinary System

The **urinary bladder**, trigone, and pelvic urethra presented normal thicknesses and normal tone. The ureters were not visible which is normal. No uroliths or sediment were visualized, and anechoic urine



## PATIENT

Daisy Murphy

## SPECIES

Canine

## BREED

Hound Mix

## SEX

Spayed Female

## AGE

13 Years

## WEIGHT

74.6 pounds

## INTERPRETED BY

Eric Lindquist, DMV,  
DABVP(CFM), Cert.  
IVUSS

## IMAGING PERFORMED BY

Dr. Elaina Petrone

## HOSPITAL NAME

Long Branch Animal  
Hospital

## REFERRING VET

Dr. Elaina Petrone

## INVOICE

14394

## DATE

03/17/26

was present. No evidence of inflammatory or neoplastic changes were noted. Ureteral papillae were normal.

The **kidneys** revealed normal size and structure, corticomedullary definition and ratio for this age. The cortices presented largely uniform texture with normal echogenic relationship to liver and spleen. Medullary structure differed distinctly from the cortex and no evidence of pelvic dilation was present. The capsules were acceptably uniform without significant irregularities. The left kidney measured 6.9 cm in length. The right kidney measured 6.9 cm in length.

### *Adrenal Glands*

The **left adrenal gland** revealed an enlarged caudal pole measuring 1.45 cm width. No capsular expansion noted without capsular escape or vascular invasion.

The **right adrenal gland** was not visualized.

### *Spleen*

The **spleen** presented a smooth homogeneous parenchyma hyperechoic to liver and renal cortical parenchyma. The capsule was smooth without noticeable expansion or deviation from within the spleen or adjacent pathology. The splenic vasculature demonstrated normal volume without signs of congestion or thrombosis. No sonographic evidence of acute or chronic inflammatory, neoplastic, or infarctual changes were noted.

### *Liver*

The **liver** images from right and left intercostal as well as subcostal views revealed subjectively normal liver size, contour, and structure. Some mild age-related parenchymal remodeling was noted but likely not clinically significant at this time. Vascular and biliary tracts were of normal volume and no evidence of congestion was noted. The gallbladder presented some dependent debris with essentially normal contour. The cystic and common bile ducts were normal. No overt evidence of active inflammatory, infiltrative or regenerative pathology was noted but should be paired with current or past LE elevations regarding any clinical significance to this presentation. The hepatic lymph nodes were unremarkable.

### *Gastrointestinal*

There was some residual chyme and gas was noted in the **stomach**, yet not pathological. This is consistent with end post prandial presentation. Transit of chyme into the small intestine was normal. Curvilinear patterns were maintained throughout the GI tract. No evidence of pathology. Small and large intestine demonstrated normal luminal chyme and stool consistency respectively. No obstructive or overt infiltrative disease was noted. No associated abnormal lymphatic activity was noted.

### *Pancreas*

The base and limbs of the **pancreas** were observed to be largely isoechoic to surrounding omental fat. Pancreatic duct and capsular contour were acceptably normal and parenchyma respected normal curvilinear patterns. No overt evidence of active inflammatory or neoplastic disease was noted.

## ULTRASONOGRAPHIC FINDINGS

- Enlarged left adrenal gland- adenoma, hyperplasia, emerging carcinoma, pheochromocytoma all possible.



## PATIENT

Daisy Murphy

## SPECIES

Canine

## BREED

Hound Mix

## SEX

Spayed Female

## AGE

13 Years

## WEIGHT

74.6 pounds

## INTERPRETED BY

Eric Lindquist, DMV,  
DABVP(CFM), Cert.  
IUUSS

## IMAGING PERFORMED BY

Dr. Elaina Petrone

## HOSPITAL NAME

Long Branch Animal  
Hospital

## REFERRING VET

Dr. Elaina Petrone

## INVOICE

14394

## DATE

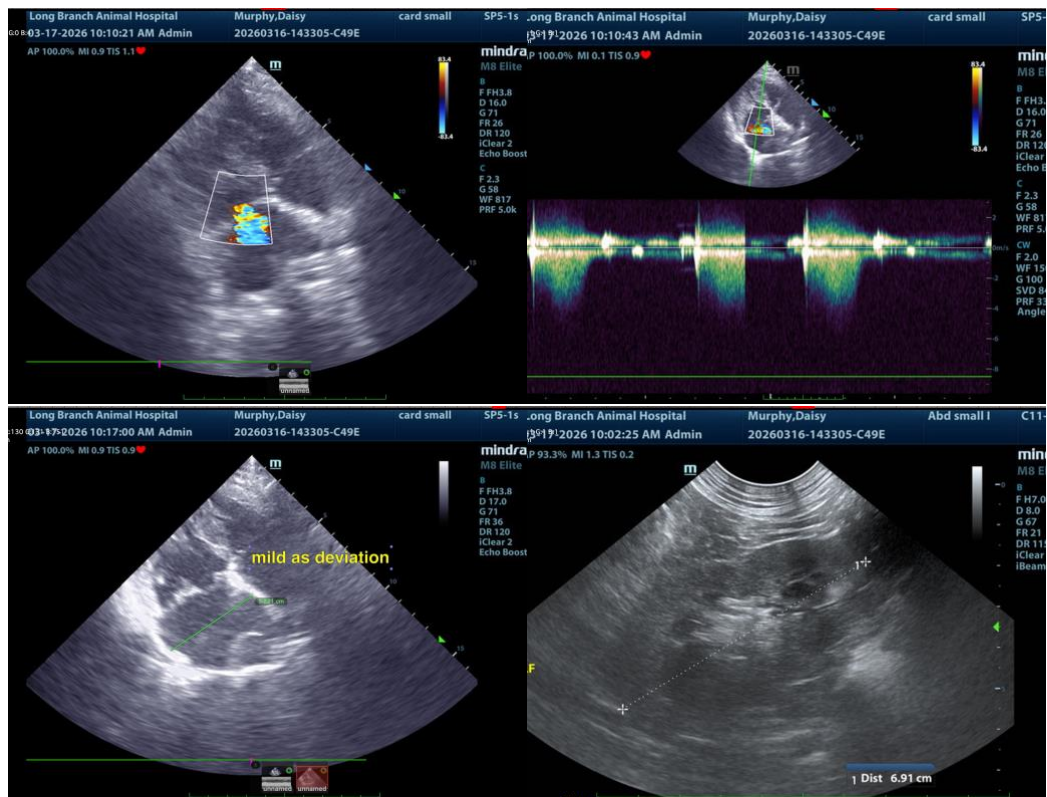
03/17/26

- Early stage B2 valvular disease.
- Age-related abdominal changes.

## INTERPRETATION OF THE FINDINGS & FURTHER RECOMMENDATIONS

Serial blood pressure measurements are recommended in this patient. If hypertension is an issue metanephrine level is recommended. If the patient appears Cushingoid and urine specific gravity is less than 1.020 then work-up for adrenal dependent Cushing's is indicated. Recheck is recommended in 2-3 weeks to assess for any progression of the adrenal gland. No evidence of metastatic disease.

The heart has minor volume overload and is working to compensate for the valvular insufficiency. Target respiratory rate is < 20 resp/minute after therapy. After initiating or adjusting therapy, I recommend recheck on the clinical exam, BUN, Creatinine, USG, Chest radiographs & Blood pressure in 5-7 days. Recheck echo in 6 months, earlier if clinical decompensation is occurring. Minor anesthetic risk for a brief procedure at this time. Repeat preanesthetic echo is ideal if anesthesia is eventually necessary. A suggested anesthetic combination would involve Torbutrol premed, propofol induction, Isoflurane maintenance or equivalent protocol. Recommend initiating Pimobendan 0.30 mg/kg BID. Blood pressure measurements are indicated.





**PATIENT**

Daisy Murphy

**SPECIES**

Canine

**BREED**

Hound Mix

**SEX**

Spayed Female

**AGE**

13 Years

**WEIGHT**

74.6 pounds

**INTERPRETED BY**

Eric Lindquist, DMV,  
DABVP(CFM), Cert.  
IVUSS

**IMAGING  
PERFORMED BY**

Dr. Elaina Petrone

**HOSPITAL NAME**

Long Branch Animal  
Hospital

**REFERRING VET**

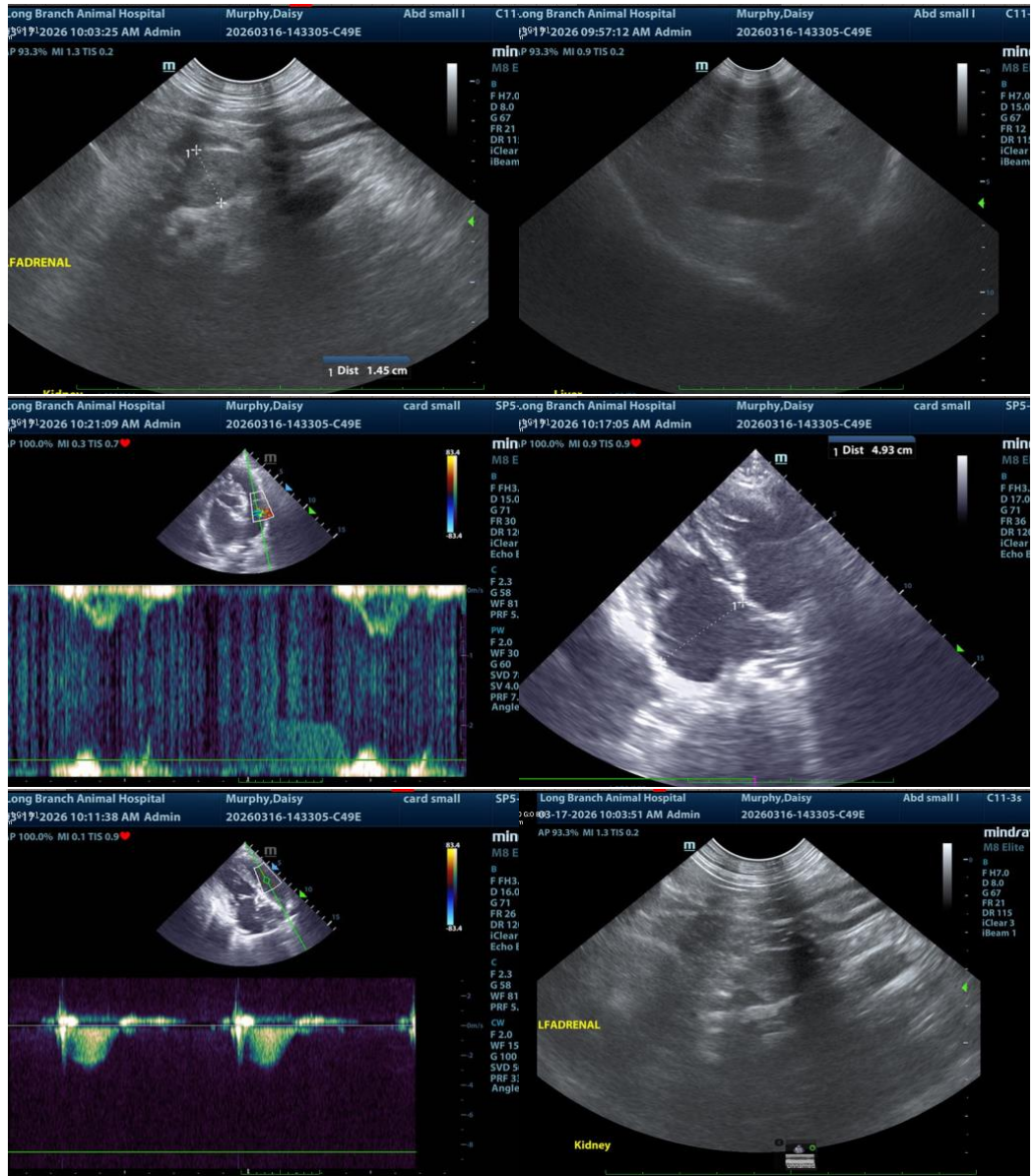
Dr. Elaina Petrone

**INVOICE**

14394

**DATE**

03/17/26



The information and recommendations provided are based on the images presented by the referring veterinarian/sonographer. No evaluation can be communicated regarding pathology that was not visible in the image/video clips provided.

Thank you for this referral. If the clinical or image interpretation does not parallel your findings or if I can be of any further assistance, please contact me.

Eric Lindquist, DMV, DABVP(CFM), Cert. IVUSS,

CEO, Owner, Founder -- SonoPath.com

[info@SonoPath.com](mailto:info@SonoPath.com)



## **PATIENT**

Daisy Murphy

## **SPECIES**

Canine

## **BREED**

Hound Mix

## **SEX**

Spayed Female

## **AGE**

13 Years

## **WEIGHT**

74.6 pounds

## **INTERPRETED BY**

Eric Lindquist, DMV,  
DABVP(CFM), Cert.  
IVUSS

## **IMAGING PERFORMED BY**

Dr. Elaina Petrone

## **HOSPITAL NAME**

Long Branch Animal  
Hospital

## **REFERRING VET**

Dr. Elaina Petrone

## **INVOICE**

14394

## **DATE**

03/17/26