



## PATIENT

Copper Miller

## SPECIES

Feline

## BREED

Domestic Shorthair

## SEX

Neutered male

## AGE

2 years

## WEIGHT

8.9 lbs

## INTERPRETED BY

Eric Lindquist, DMV  
DABVP, Cert. IVUSS

## IMAGING PERFORMED BY

Susan Lincoski

## HOSPITAL NAME

University Drive VH

## REFERRING VET

Dr. Lincoski

## INVOICE

73528

## DATE

3/17/26

## PRESENTING CLINICAL SIGNS

- On/off diarrhea-mucoid, bloody consistent with large bowel. Repeated fecals negative since initially adopted and tapeworm positive, appropriate anti-parasite treatment at that time. Issues continued, and fecal enteric molecular panel did come up positive for Clostridia. He has been treated with fiber, and tylan but still having issues.
- Patient was adopted last July for shelter.
- Blood drawn for gi panel today
- Fecal in July 25 positive for tapeworm antigen. Subsequent fecals August and November negative. Fecal molecular panel Jan 2026: positive Coronavirus, and high levels of C. perfringens alpha toxin.

## ULTRASONOGRAPHIC EXAMINATION OF THE ABDOMEN

### Urinary System

The **urinary bladder**, trigone, and pelvic urethra presented normal thicknesses and normal tone. The ureters were not visible which is normal. No uroliths or sediment were visualized and anechoic urine was present. No evidence of inflammatory or neoplastic changes was noted. Ureteral papillae were normal.

The **kidneys** revealed normal size and structure, corticomedullary definition and ratio for this age. The cortices presented largely uniform texture with normal echogenic relationship to liver and spleen. Medullary structure differed distinctly from the cortex and no evidence of pelvic dilation was present. The capsules were acceptably uniform without significant irregularities. The right kidney measured 3.9 cm. The left kidney measured 3.6 cm.

### Adrenal Glands

Both **adrenal glands** were visualized and recognized as having normal shape, size, position and echogenicity for this breed. The phrenic vasculature, glandular echogenicity and detail were unremarkable. Capsule, cortex, and medullary definition were normal for this age patient. The left adrenal gland measured 0.45 cm. The right adrenal gland measured 0.34 cm.

### Spleen

The **spleen** presented a smooth homogeneous parenchyma hyperechoic to liver and renal cortical parenchyma. The capsule was smooth without noticeable expansion or deviation from within the spleen or adjacent pathology. The splenic vasculature demonstrated normal volume without signs of congestion or thrombosis. No sonographic evidence of acute or chronic inflammatory, neoplastic, or infarctual changes was noted.

### Liver



## PATIENT

Copper Miller

## SPECIES

Feline

## BREED

Domestic Shorthair

## SEX

Neutered male

## AGE

2 years

## WEIGHT

8.9 lbs

## INTERPRETED BY

Eric Lindquist, DMV  
DABVP, Cert. IVUSS

## IMAGING PERFORMED BY

Susan Lincoski

## HOSPITAL NAME

University Drive VH

## REFERRING VET

Dr. Lincoski

## INVOICE

73528

## DATE

3/17/26

The **liver** images submitted revealed subjectively normal liver size, contour, and structure. Parenchymal echogenicity was naturally coarse and hypoechoic to the spleen. Vascular and biliary tracts were of normal volume with no evidence of congestion. The gallbladder presented acceptably thin walls with primarily anechoic content. The cystic and common bile ducts were normal. No pathological hepatic lymphadenopathy was evident. No overt structural evidence of inflammatory, infiltrative or regenerative pathology was evident.

### ***Gastrointestinal***

The **gastrointestinal** presentation revealed mild uniform prominence of the gastric mucosa as well as areas of "ropey" small intestinal wall with slight disruption of the normal 1:3 muscularis/mucosal ratio. Fluid filled gastric lumen was noted. The intestinal submucosa was slightly irregular, thickened and hyperechoic suggestive of low grade, chronic disease. Slight reactive mesenteric lymph node was noted and measured up to 0.5 cm.

### ***Pancreas***

The base and limbs of the **pancreas** were observed to be largely isoechoic to surrounding omental fat. Pancreatic duct and capsular contour were acceptably normal and parenchyma respected normal curvilinear patterns. No overt evidence of active inflammatory or neoplastic disease was noted.

## **ULTRASONOGRAPHIC FINDINGS**

IBD GI pattern.

Slight reactive mesenteric lymph nodes.

## **INTERPRETATION OF THE FINDINGS & FURTHER RECOMMENDATIONS**

Differentials for diarrhea include occult parasitism. Dietary indiscretion, dietary intolerance, antibiotic responsive colitis, intestinal dysbiosis and occult Addison's should all be considered as causes of diarrhea in this patient. A hydrolyzed diet trial may be in this patient's best interest +/- probiotics. 24-hour NPO and reintroduction of bland diet indicated. I recommend a baseline cortisol or ACTH stimulation test, a fresh fecal smear and fecal floatation analysis if not already performed.



**PATIENT**

Copper Miller

**SPECIES**

Feline

**BREED**

Domestic Shorthair

**SEX**

Neutered male

**AGE**

2 years

**WEIGHT**

8.9 lbs

**INTERPRETED BY**

Eric Lindquist, DMV  
DABVP, Cert. IVUSS

**IMAGING PERFORMED BY**

Susan Lincoski

**HOSPITAL NAME**

University Drive VH

**REFERRING VET**

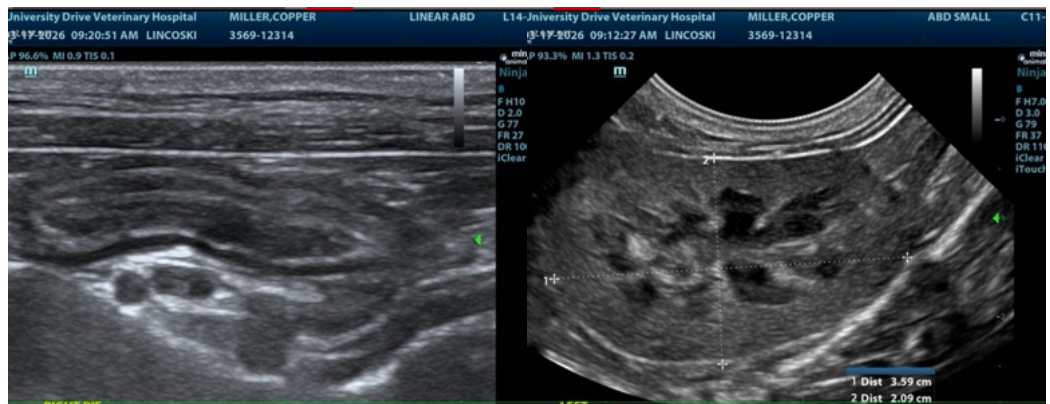
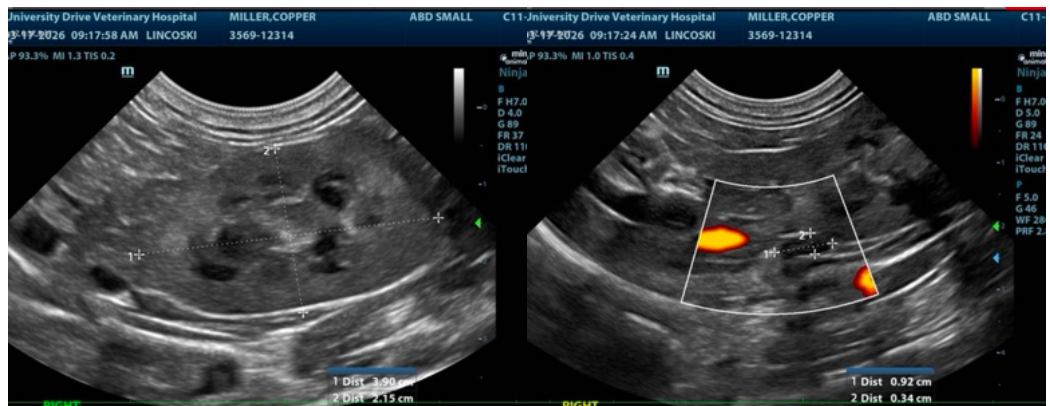
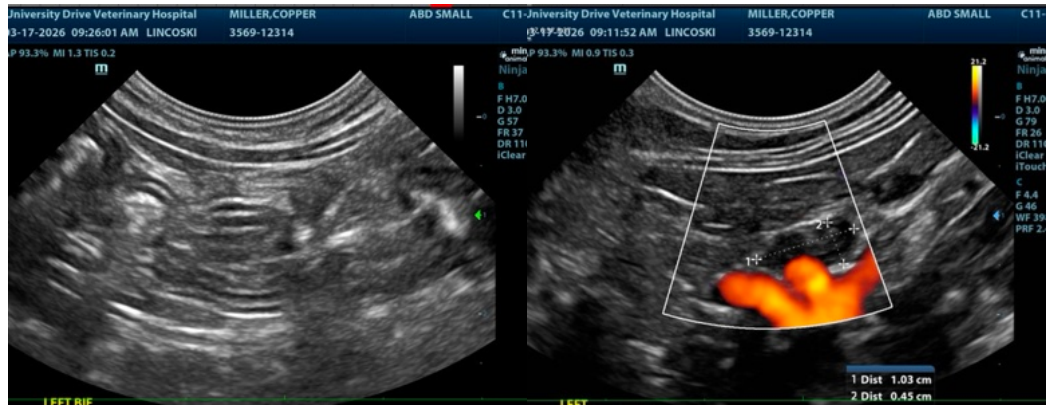
Dr. Lincoski

**INVOICE**

73528

**DATE**

3/17/26





## PATIENT

Copper Miller

## SPECIES

Feline

## BREED

Domestic Shorthair

## SEX

Neutered male

## AGE

2 years

## WEIGHT

8.9 lbs

## INTERPRETED BY

Eric Lindquist, DMV  
DABVP, Cert. IVUSS

## IMAGING PERFORMED BY

Susan Lincoski

## HOSPITAL NAME

University Drive VH

## REFERRING VET

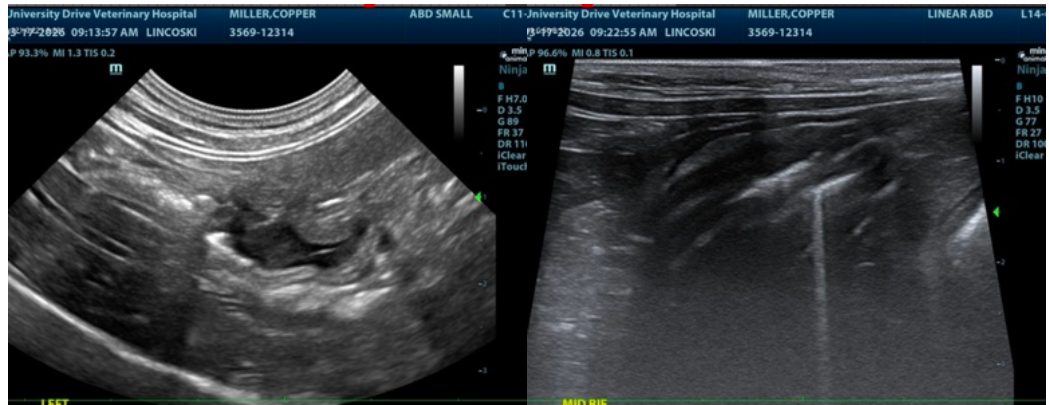
Dr. Lincoski

## INVOICE

73528

## DATE

3/17/26



The information and recommendations provided are based on the images presented by the referring veterinarian/sonographer. No evaluation can be communicated regarding pathology that was not visible in the image/video clips provided.

Thank you for this referral. If the clinical or image interpretation does not parallel your findings or if I can be of any further assistance please contact me.

Eric Lindquist, DMV, DABVP (CFM), Cert. IVUSS, CEO of SonoPath.com

[info@SonoPath.com](mailto:info@SonoPath.com)