

IMAGING PERFORMED BY

IntraPet.com



SonoPath

Clinical Sonography & Telecytology

EDUCATIONAL TELECONSULTATION SERVICES™

1-800-838-4268 info@sonopath.com SonoPath.com

DATE

3/17/23

PATIENT

Leia Kincaid

SPECIES

Canine

BREED

Cockapoo

SEX

Spayed Female

AGE

8/20/08

WEIGHT

19.96 Pounds

INTERPRETED BY

Eric Lindquist, DMV
DABVP, Cert. IVUSS

HOSPITAL NAME

Northwind AH

REFERRING VET

Dr. Jones

INVOICE

45991

PRESENTING CLINICAL SIGNS

Lethargy, ADR, having accidents in the house. Concerned about pale mm, and soft abdomen.

Current Medications: None listed.

Lab Results: Decreased RBC, nucleated RBC, hct, elevated WBC, elevated creatinine

Date of Previous IntraPet Ultrasound: No previous.

Sedation: Not required to complete full diagnostic ultrasound.

Stat Report: Requested/Approved.

ULTRASONOGRAPHIC EXAMINATION OF THE ABDOMEN & THORAX

Urinary System

The **urinary bladder**, trigone, and pelvic urethra presented normal thicknesses and normal tone. The ureters were not visible which is normal. No uroliths or sediment were visualized and anechoic urine was present. No evidence of inflammatory or neoplastic changes were noted. Ureteral papillae were normal.

The **kidneys** revealed largely normal size and structure, corticomedullary definition and ratio (cortex 1/3 of medulla) were essentially maintained with some age-related loss of curvilinear patterns regarding the capsule and C/M junction. The cortices presented largely uniform texture with some increased echogenicity expected for his age patient. Medullary structure differed distinctly from that of the cortex. Slight pyelectasia noted. The right kidney measured 4.76 cm. The left kidney measured 4.58 cm with pyelectasia at 0.33 cm.

Adrenal Glands

Both **adrenal glands** were visualized and recognized as having normal shape, size, position and echogenicity for this breed. The phrenic vasculature, glandular echogenicity and detail were unremarkable. Capsule, cortex, and medullary definition were normal for this age patient. The right adrenal gland measured 1.79 cm x 0.57 cm at the caudal pole and 0.51 cm at the cranial pole. The left adrenal gland measured 1.41 cm x 0.60 cm at the caudal pole and 0.48 cm at the cranial pole.

Spleen

The **spleen** in this patient was uniform, yet volume contracted. Hydration status should be assessed.

Liver

The **liver** presented coarse architecture. Edematous gallbladder noted with minor dependent debris. Hepatic veins and vena cava were dilated, consistent with passive congestion. Heterogeneous parenchymal changes noted throughout the liver yet subjectively benign.

Gastrointestinal

Examination of the **gastrointestinal tract** revealed a stomach and intestine free of stasis, of normal wall thickness, acceptable curvilinear mural detail, and peristaltic activity. Small and large intestine demonstrated normal luminal chyme and stool consistency respectively. No obstructive or overt infiltrative disease was noted. No associated abnormal lymphatic activity was noted.

Pancreas

The **pancreas** was edematous, possibly owing to low-grade inflammation, yet likely secondary to passive congestion.

Free Abdomen

Secondary ascites noted owing to passive congestion, with secondarily enhanced mesentery.

Thorax

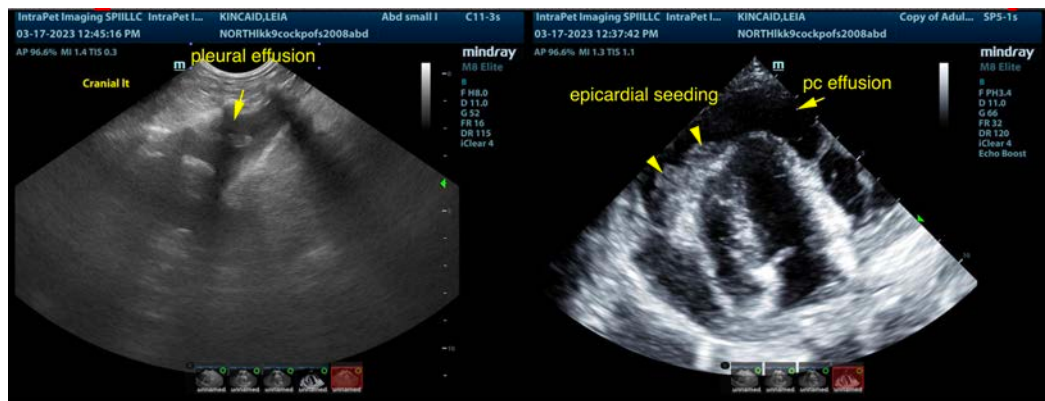
The heart revealed multiple pericardial masses and pericardial effusion. The masses derive from the right auricle. The right auricular wall is completely disrupted, typical of hemangiosarcoma. Other mass seedings noted in the epicardium and pericardium. Pleural effusion also noted, which would suggest full thoracic spread of a neoplastic process.

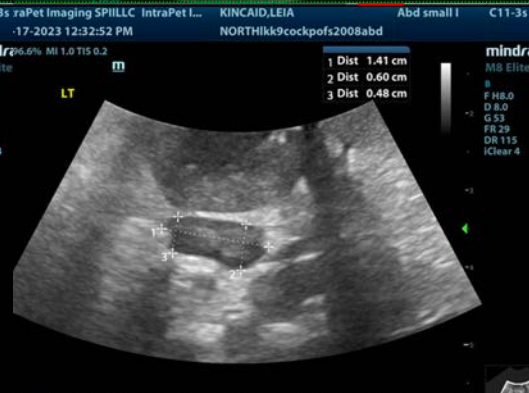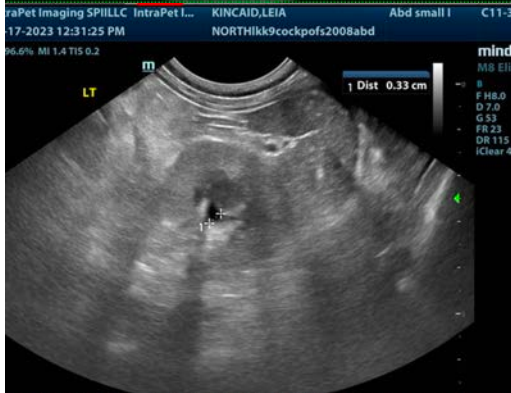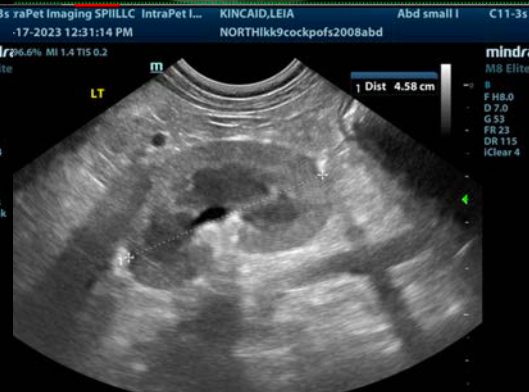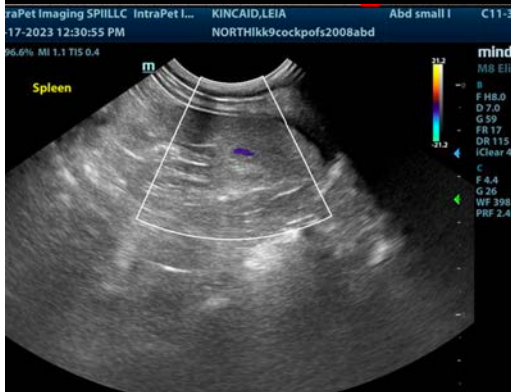
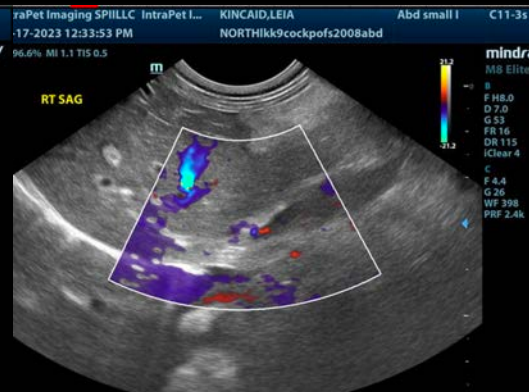
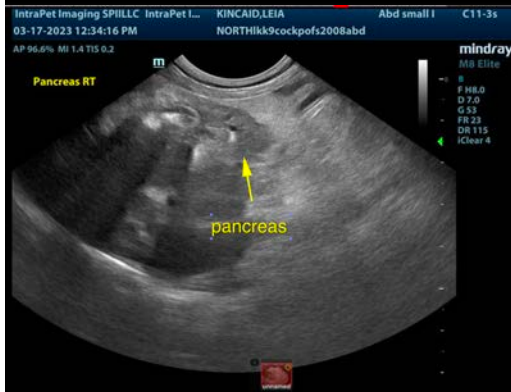
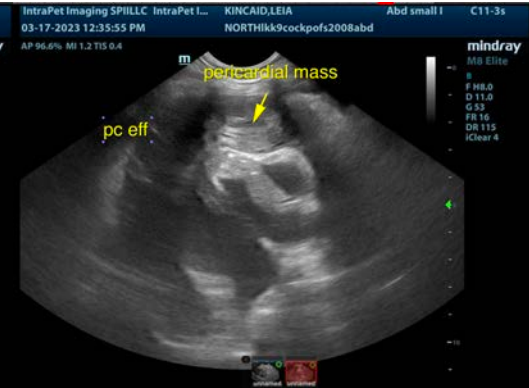
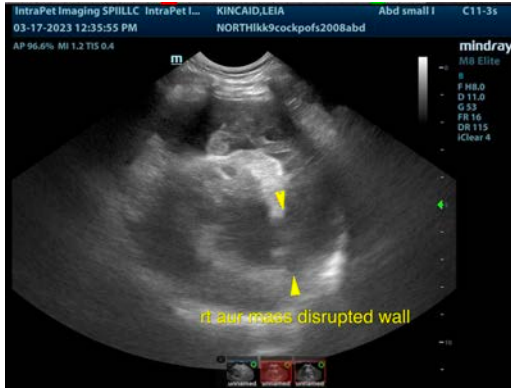ULTRASONOGRAPHIC FINDINGS

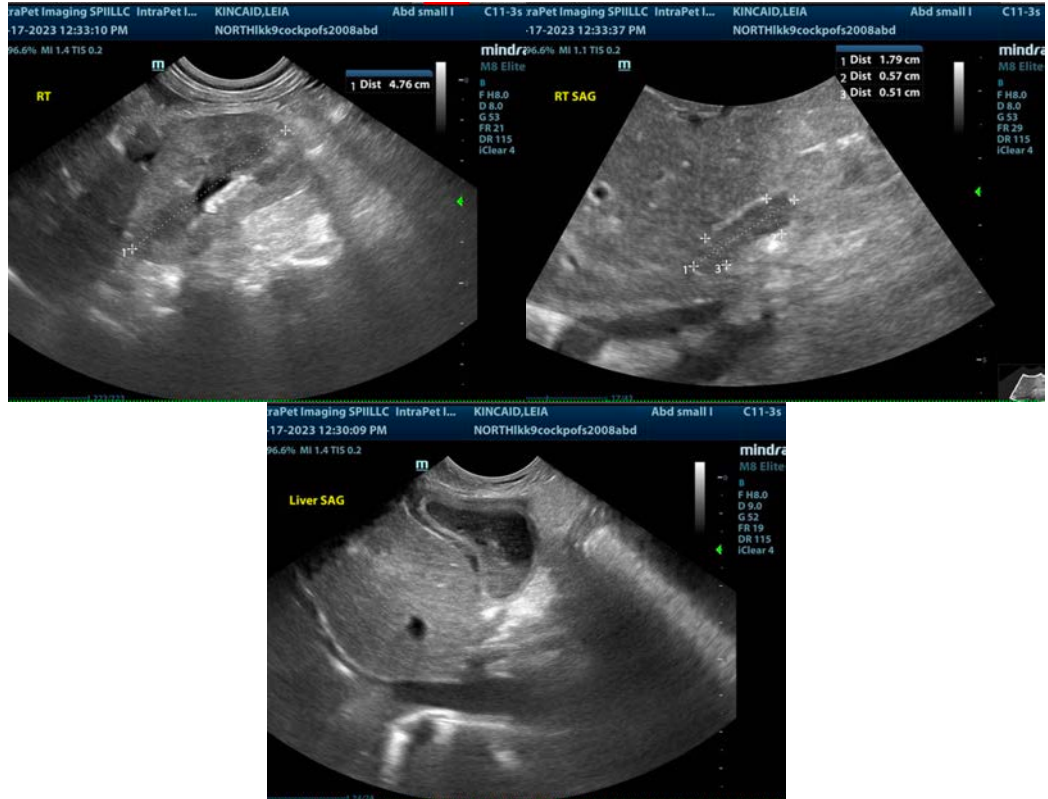
- Geriatric abdomen with passive congestion liver pattern, moderate chronic renal changes and pyelectasia
- Volume contracted spleen
- Edematous pancreas
- Ascites and reactive mesentery
- Thoracic neoplasia – likely hemangiosarcoma and likely spread into the extracardiac space. Pericardial invasion and seeding as well as tamponade/obstructive effect on vena cava inflow, causing secondary passive congestion to the liver and pancreatic edema.

INTERPRETATION OF THE FINDINGS & FURTHER RECOMMENDATIONS

Assessment for UTI indicated. However, the more important issue is the thoracic presentation. The passive congestion in the liver and secondary ascites is likely from a combination of both obstruction of the vena cava inflow into the right auricle and from pericardial effusion/tamponade effect. Prognosis is poor. Quality of life chemotherapeutic intervention with IV Doxorubicin could be considered to attempt to reduce the mass, with recheck echocardiogram 3-5 days post-treatment. This would be extremely palliative and extremely empirical. However, may prove somewhat effective in reducing mass size, presuming that this is hemangiosarcoma. With some significant risk, 25-gauge FNA of the accessible mass with ultrasound guidance could be considered to attempt to definitively have a cytological diagnosis.







The information and recommendations provided are based on the images presented by the referring veterinarian/sonographer. No evaluation can be communicated regarding pathology that was not visible in the image/video clips provided.

Thank you for this referral. If the clinical or image interpretation does not parallel your findings or if I can be of any further assistance please contact me.

Eric Lindquist, DMV, DABVP, Cert. IVUSS, CEO of SonoPath.com
info@SonoPath.com