



**PATIENT**

Jolene Kohler

**SPECIES**

Canine

**BREED**

Lab X

**SEX**

Spayed Female

**AGE**

1 Year

**WEIGHT**

37 Pounds

**INTERPRETED BY**

Eric Lindquist, DMV

DABVP, Cert. IVUSS

**IMAGING PERFORMED BY**

Shari Reffi, CVT

**HOSPITAL NAME**

Shohola Vet Hospital

**REFERRING VET**

Dr. DeMeo

**INVOICE**

46014

**DATE**

3/17/23

**PRESENTING CLINICAL SIGNS**

Stage heartworm disease. Patient is coughing and has III/VI murmur. Current meds: Doxy 200mg sid; Zofran 8mg sid; Gabapentin 200mg; Trazodone 100mg

**ULTRASONOGRAPHIC EXAMINATION OF THE HEART**

CANINE CARDIAC PARAMETERS	MR VMAX (m/s)	TR VMAX (m/s)	LA/AO (Boon method)	LA/AO (Heart Base; Swe)	FS (%)	EF (%)	EPSS (cm)
NORMAL PARAMETER	4.5-5.5	<2.7	1.3	<1.6	28-40	40-100	<0.6
PATIENT			1.0	1.21	34	65	0.3
CANINE CARDIAC PARAMETERS	HR (BPM)	AV VMAX (m/s)	PV MAX (m/s)	BODY WEIGHT (kg)	LA 2D short axis Base view (cm)	LVIDd Avg; 2D and m-mode short axis (cm)	LVIDs Avg; 2D and m-mode short axis (cm)
NORMAL PARAMETER	50-100	0.7-1.7	0.7-1.6	BELOW	BELOW	BELOW	BELOW
PATIENT	131	1.41	1.5		3.26	3.14	

**Cardiac Presentation**

The echocardiogram in this patient demonstrated normal **left atrial** size based on 3 separate methods of LA evaluation. The cranial and caudal **mitral** valve leaflets presented normal linear structure, extension in systole, and union in diastole with normal kinesis. The **left ventricle** presented thicknesses with linear contour and was not dilated nor restricted. The **myocardium** presented normal echogenicity without subjective evidence of significant fibrotic or ischemic disease. **Contractility** of the ventricular walls was adequate and in normal range for this patient evidenced by the fractional shortening measurement and subjective evaluation of the different regions of the myocardium. The **left ventricular outflow** tract demonstrated normal laminar flow and subjective structural integrity. The **right atrium** and auricle revealed normal size, structure and content. No evidence of masses was noted. **Tricuspid** valvular assessment demonstrated adequate linear morphology and kinesis. The **right ventricle** was of normal size (1/3 diameter of LV), chordae structure, myocardial echogenicity and thickness. **Pulmonary outflow** tract assessment revealed normal valve structure, laminar flow, and diameter (approx. 1:1 pa/ao ratio). No visible **pericardial** or free pleura fluid was noted. Some ringdown alveolar artifact noted, which may indicate alveolar disease.

**ULTRASONOGRAPHIC FINDINGS**

- Normal echocardiogram
- Ringdown alveolar artifact

**INTERPRETATION OF THE FINDINGS & FURTHER RECOMMENDATIONS**

Normal physiological laminar flow was noted in all valvular structures. No evidence of turbulence. Temporary volume shift may have caused a physiological murmur, yet there is no structural or functional evidence of disease in this patient. Chest radiographs warranted to assess for any overlying thoracic pathology.



**PATIENT**

Jolene Kohler

**SPECIES**

Canine

**BREED**

Lab X

**SEX**

Spayed Female

**AGE**

1 Year

**WEIGHT**

37 Pounds

**INTERPRETED BY**

Eric Lindquist, DMV

DABVP, Cert. IVUSS

**IMAGING PERFORMED BY**

Shari Reffi, CVT

**HOSPITAL NAME**

Shohola Vet Hospital

**REFERRING VET**

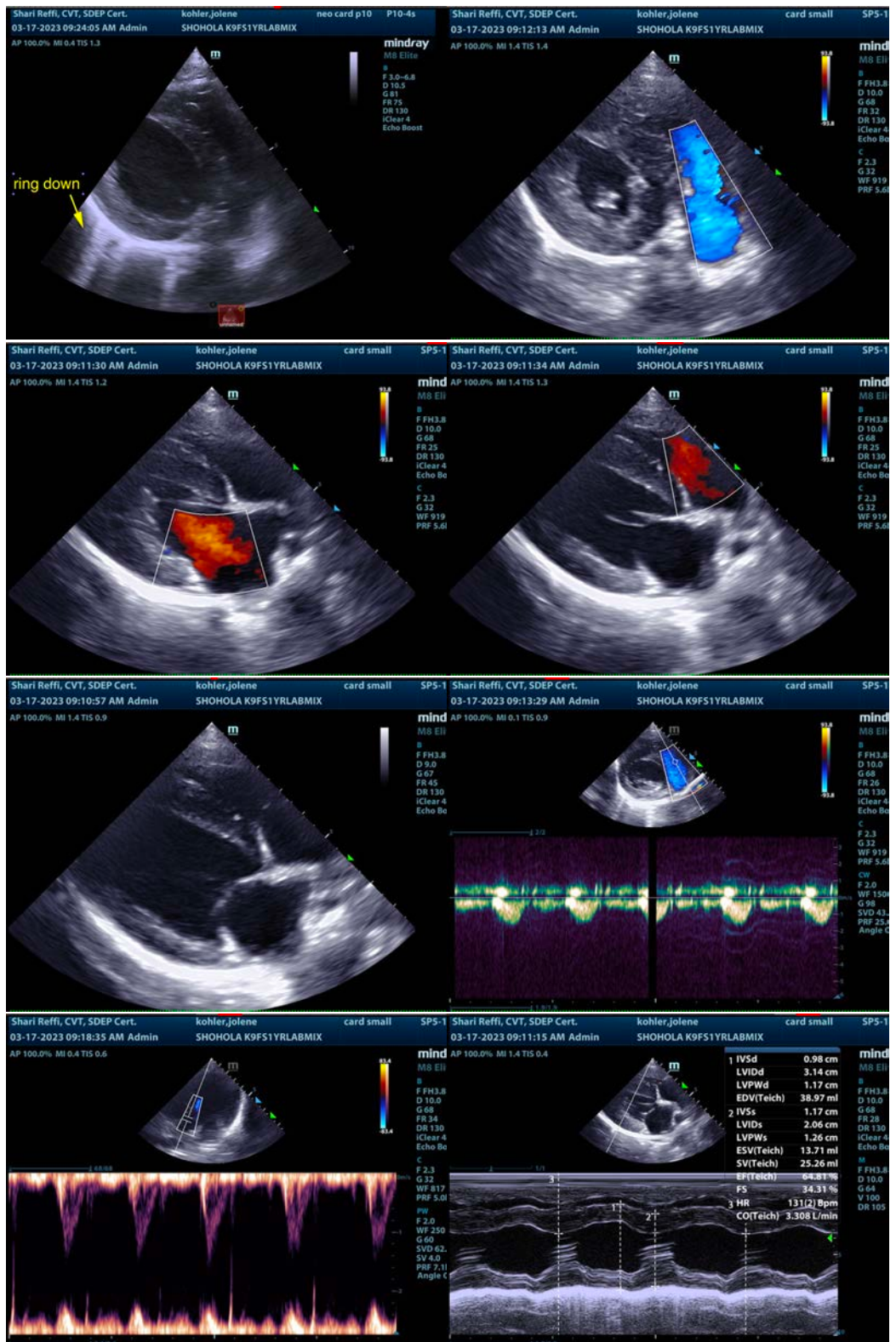
Dr. DeMeo

**INVOICE**

46014

**DATE**

3/17/23





**PATIENT**

Jolene Kohler

**SPECIES**

Canine

**BREED**

Lab X

**SEX**

Spayed Female

**AGE**

1 Year

**WEIGHT**

37 Pounds

**INTERPRETED BY**

Eric Lindquist, DMV

DABVP, Cert. IVUSS

**IMAGING PERFORMED BY**

Shari Reffi, CVT

**HOSPITAL NAME**

Shohola Vet Hospital

**REFERRING VET**

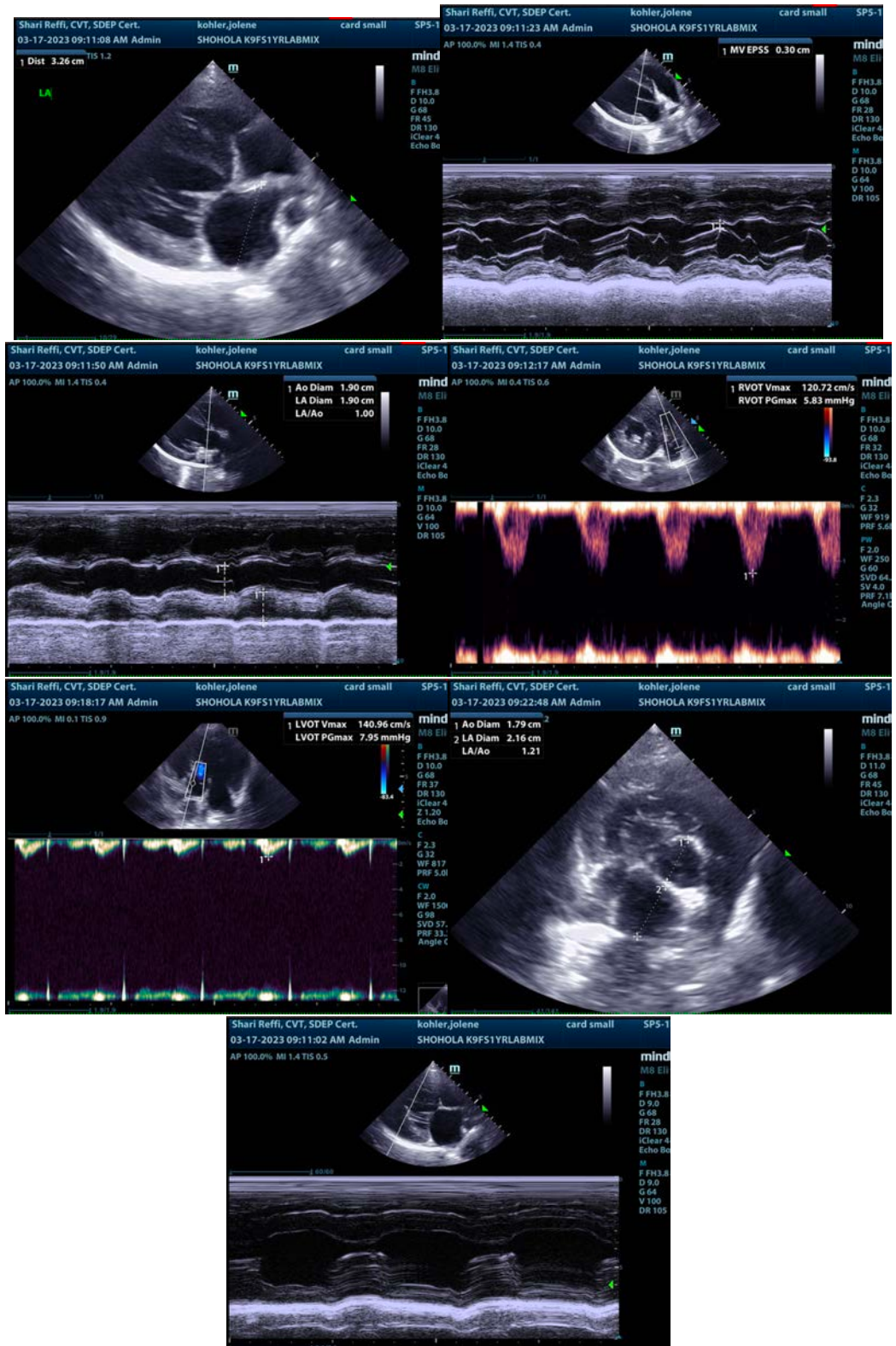
Dr. DeMeo

**INVOICE**

46014

**DATE**

3/17/23





**PATIENT**

Jolene Kohler

The information and recommendations provided are based on the images presented by the referring veterinarian/sonographer. No evaluation can be communicated regarding pathology that was not visible in the image/video clips provided.

**SPECIES**

Canine

Thank you for this referral. If the clinical or image interpretation does not parallel your findings or if I can be of any further assistance please contact me.

**BREED**

Lab X

**Eric Lindquist, DMV, DABVP, Cert. IVUSS, CEO of SonoPath.com**

[info@SonoPath.com](mailto:info@SonoPath.com)

**SEX**

Spayed Female

**AGE**

1 Year

**WEIGHT**

37 Pounds

**INTERPRETED BY**

Eric Lindquist, DMV

DABVP, Cert. IVUSS

**IMAGING PERFORMED BY**

Shari Reffi, CVT

**HOSPITAL NAME**

Shohola Vet Hospital

**REFERRING VET**

Dr. DeMeo

**INVOICE**

46014

**DATE**

3/17/23