



**PATIENT**

Gracie Beitel

**SPECIES**

Canine

**BREED**

English Setter

**SEX**

Spayed Female

**AGE**

10 Years 9 Months

**WEIGHT**

74 Pounds

**INTERPRETED BY**

Eric Lindquist, DMV

DABVP, Cert. IVUSS

**IMAGING PERFORMED BY**

Dr. Julie Vezzetti

**HOSPITAL NAME**

Stuga North Vet Care

**REFERRING VET**

Dr. Julie Vezzetti

**INVOICE**

46021

**DATE**

3/17/23

**PRESENTING CLINICAL SIGNS**

O is concerned there is something going on with patient, no specific symptoms, but did have diarrhea 2 weeks ago. We had previously done a "met check" ultrasound in Sept 2022 that was normal, so just comparing apples to apples to see if any changes.

**ULTRASONOGRAPHIC EXAMINATION OF THE ABDOMEN**

**Urinary System**

The **urinary bladder**, trigone, and pelvic urethra presented normal thicknesses and normal tone. The ureters were not visible which is normal. No uroliths or sediment were visualized and anechoic urine was present. No evidence of inflammatory or neoplastic changes were noted. Ureteral papillae were normal. The pelvic urethra was imaged 2.0 cm beyond the cystourethral junction.

The **kidneys** revealed normal size and structure, corticomedullary definition and ratio for this age. The cortices presented largely uniform texture with normal echogenic relationship to liver and spleen. Medullary structure differed distinctly from the cortex and no evidence of pelvic dilation was present. The capsules were acceptably uniform without significant irregularities. The left kidney measured 5.0 cm. The right kidney measured 6.7 cm.

**Adrenal Glands**

The **left adrenal gland** was visualized obliquely at 0.40 cm.

The **right adrenal gland** was not visualized.

**Spleen**

The **spleen** was mildly enlarged and slightly heterogeneous and folded upon itself caudally with a hyperechoic lipogranuloma in the mid caudal body.

**Liver**

The **liver** presented a vacuolar hepatopathy pattern with minor enlargement and slight coarse architecture. Minor remodeling. Gallbladder and common bile duct were unremarkable.

**Gastrointestinal**

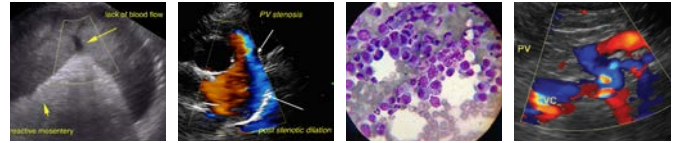
There was some residual chyme and gas was noted in the **stomach**, yet not pathological. This is consistent with end post prandial presentation. Transit of chyme into the small intestine was normal. Curvilinear patterns were maintained throughout the GI tract. No evidence of pathology. Small and large intestine demonstrated normal luminal chyme and stool consistency respectively. No obstructive or overt infiltrative disease was noted. No associated abnormal lymphatic activity was noted.

**Pancreas**

The base and limbs of the **pancreas** were observed to be largely isoechoic to surrounding omental fat. Pancreatic duct and capsular contour were acceptably normal and parenchyma respected normal curvilinear patterns. No overt evidence of active inflammatory or neoplastic disease was noted.

**ULTRASONOGRAPHIC FINDINGS**

- Benign geriatric abdomen with minor lipogranulomatous splenic changes and minor hepatic remodeling
- Partially full stomach



**PATIENT**

Gracie Beitel

**SPECIES**

Canine

**BREED**

English Setter

**SEX**

Spayed Female

**AGE**

10 Years 9 Months

**WEIGHT**

74 Pounds

**INTERPRETED BY**

Eric Lindquist, DMV

DABVP, Cert. IVUSS

**IMAGING PERFORMED BY**

Dr. Julie Vezzetti

**HOSPITAL NAME**

Stuga North Vet Care

**REFERRING VET**

Dr. Julie Vezzetti

**INVOICE**

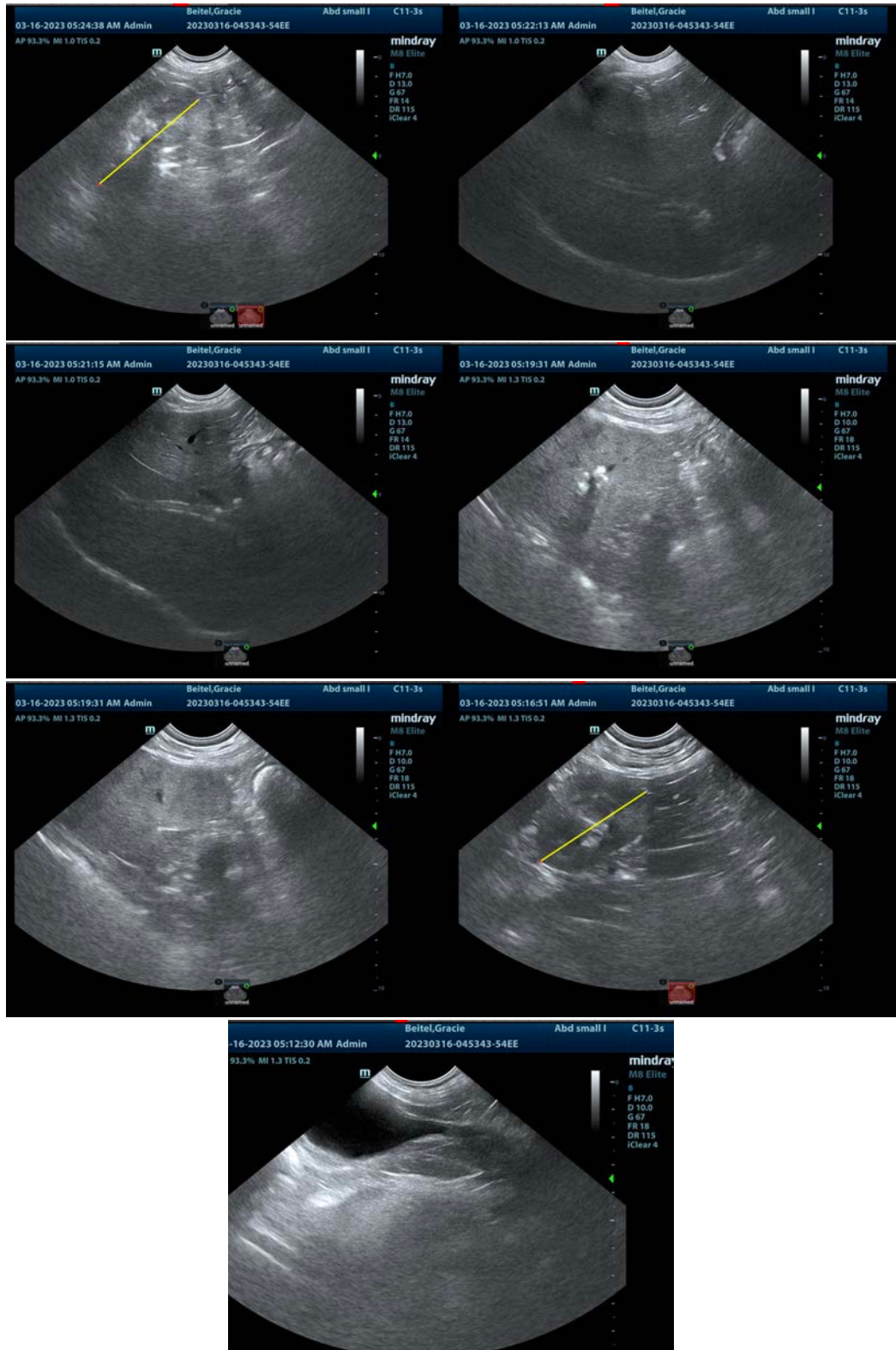
46021

**DATE**

3/17/23

**INTERPRETATION OF THE FINDINGS & FURTHER RECOMMENDATIONS**

No evidence of significant disease.





**PATIENT**

Gracie Beitel

The information and recommendations provided are based on the images presented by the referring veterinarian/sonographer. No evaluation can be communicated regarding pathology that was not visible in the image/video clips provided.

**SPECIES**

Canine

Thank you for this referral. If the clinical or image interpretation does not parallel your findings or if I can be of any further assistance please contact me.

**BREED**

English Setter

**Eric Lindquist**, DMV, DABVP, Cert. IVUSS, CEO of SonoPath.com

[info@SonoPath.com](mailto:info@SonoPath.com)

**SEX**

Spayed Female

**AGE**

10 Years 9 Months

**WEIGHT**

74 Pounds

**INTERPRETED BY**

Eric Lindquist, DMV

DABVP, Cert. IVUSS

**IMAGING PERFORMED BY**

Dr. Julie Vezzetti

**HOSPITAL NAME**

Stuga North Vet Care

**REFERRING VET**

Dr. Julie Vezzetti

**INVOICE**

46021

**DATE**

3/17/23